


LANDES  
BIOSCIENCE

*V a d e m e c u m*

# Pediatric Surgery



Robert M. Arensman  
Daniel A. Bambini  
P. Stephen Almond

# Pediatric Surgery

**Robert M. Arensman, M.D.**

*Northwestern University  
Chicago, Illinois, U.S.A.*

**Daniel A. Bambini, M.D.**

*Northwestern University  
Chicago, Illinois, U.S.A.*

**P. Stephen Almond, M.D.**

*Northwestern University  
Chicago, Illinois, U.S.A.*

**LANDES**  
**BIOSCIENCE**

GEORGETOWN, TEXAS  
U.S.A.

VADEMECUM  
Pediatric Surgery  
LANDES BIOSCIENCE  
Georgetown, Texas U.S.A.

Copyright ©2000 Landes Bioscience

All rights reserved.

No part of this book may be reproduced or transmitted in any form or by any means, electronic or mechanical, including photocopy, recording, or any information storage and retrieval system, without permission in writing from the publisher.

Printed in the U.S.A.

Please address all inquiries to the Publisher:

Landes Bioscience, 810 S. Church Street, Georgetown, Texas, U.S.A. 78626

Phone: 512/ 863 7762; FAX: 512/ 863 0081

ISBN: 1-57059-499-6

**Library of Congress Cataloging-in-Publication Data**

Arensman, Robert M.

Pediatric surgery / Robert M. Arensman, Daniel Bambini, P. Stephen Almond.

p. ; cm. -- (Vademecum)

Includes bibliographical references and index.

ISBN 1-57059-499-6

1. Children--Surgery. I. Bambini, Daniel. II. Almond, P. Stephen. III. Title. IV. Series.

[DNLM: 1. Surgical Procedures, Operative--Child. 2. Surgical Procedures, Operative--Infant. WO 925 A681p 2000]

RD137.A74 2000

617.9'8--dc21

00--311658

While the authors, editors, sponsor and publisher believe that drug selection and dosage and the specifications and usage of equipment and devices, as set forth in this book, are in accord with current recommendations and practice at the time of publication, they make no warranty, expressed or implied, with respect to material described in this book. In view of the ongoing research, equipment development, changes in governmental regulations and the rapid accumulation of information relating to the biomedical sciences, the reader is urged to carefully review and evaluate the information provided herein.

## Dedication --- ---

To children: whose endurance of suffering, whose courage in the face of congenital malformations and childhood cancer, and whose smiles over tears inspire all who work with them to overcome childhood maladies.



# Contents

<b>Section I: Assessment of the Pediatric Surgical Patient.....</b>	<b>1</b>
<b>1. Preoperative Care .....</b>	<b>2</b>
<i>Robert M. Arensman</i>	
Consultation .....	2
Physical Examination .....	2
Diagnostic Studies and Laboratory Investigations .....	3
Pain Management .....	3
Blood Donation .....	4
Presurgical Visitation and Teaching .....	4
<b>2. Immediate Postoperative Care.....</b>	<b>5</b>
<i>Daniel A. Bambini</i>	
Wound and Dressing Care .....	5
Extubation and Transfer .....	5
Postoperative Orders .....	5
Pain Management .....	7
<b>3. Anemia .....</b>	<b>9</b>
<i>Robert M. Arensman and Lars Göran Friberg</i>	
Definition .....	9
Physiologic Anemia .....	9
Iron Deficiency .....	9
Hereditary Spherocytosis .....	9
Sickle Cell Anemia .....	10
Other Anemias .....	10
<b>4. Genetics and Prenatal Diagnosis in Pediatric Surgery .....</b>	<b>11</b>
<i>Lars Göran Friberg</i>	
Prenatal Diagnostic Studies and Tests .....	11
Indications for Prenatal Diagnosis .....	13
<b>Section II: Perioperative Management and Critical Care.....</b>	<b>15</b>
<b>5. Vascular Access .....</b>	<b>16</b>
<i>Marleta Reynolds</i>	
Blood Sampling .....	16
Venous Access .....	16
Central Venous Access .....	17
Umbilical Vessel Access .....	17
Intraosseous Access .....	17
<b>6. Fluids and Electrolytes .....</b>	<b>19</b>
<i>John R. Wesley</i>	
Fluids .....	19
Electrolytes .....	20
Dehydration .....	22

**7. Nutrition and Metabolism ..... 23**

*John R. Wesley*

Introduction ..... 23  
Administering Parenteral Nutrition Solutions ..... 24  
Monitoring ..... 27  
Complications ..... 28  
Pediatric Nutritional Assessment ..... 30  
Transition from Parenteral to Enteral Nutrition ..... 30

**8. Respiratory Failure and Support in Children ..... 31**

*Marybeth Madonna*

Novel Approaches for Respiratory Support in Children ..... 33

**9. Hypovolemic Shock and Resuscitation ..... 35**

*Matthew L. Moront*

Definition ..... 35  
Clinical Indicators of Inadequate Tissue Perfusion ..... 35  
Treatment of Shock ..... 36

**10. Blood Component Therapy ..... 39**

*Richard Fox*

Blood Component Preparation ..... 39  
Screening ..... 39  
Indications for Transfusion ..... 39  
Transfusion Reactions ..... 41

**11. Perioperative Infections and Antibiotics ..... 43**

*Riccardo Superina*

Classification and Incidence of Postoperative Wound Infection ..... 43  
Etiology ..... 43  
Clinical Presentation ..... 44  
Diagnosis ..... 44  
Treatment ..... 45  
Infection of a Central Venous Catheter or Port ..... 48  
Yeast Infections ..... 48  
Summary ..... 48

**Section III: Common Pediatric Surgical Problems ..... 49**

**12. Inguinal Hernia and Hydrocele ..... 50**

*Juda Z. Jona*

Incidence ..... 50  
Etiology ..... 50  
Clinical Presentation ..... 50  
Diagnosis ..... 51  
Treatment ..... 52  
Outcomes ..... 52  
Special Considerations ..... 52

<b>13. Varicocele .....</b>	<b>55</b>
<i>Juda Z. Jona</i>	
Incidence .....	55
Etiology .....	55
Clinical Presentation .....	55
Pathophysiology .....	55
Treatment .....	56
Outcomes .....	56
<b>14. Testicular Torsion .....</b>	<b>57</b>
<i>Juda Z. Jona</i>	
Incidence .....	57
Etiology .....	57
Clinical Presentation .....	57
Diagnosis .....	58
Pathophysiology .....	58
Treatment .....	58
Outcomes .....	59
<b>15. Cryptorchidism: The Undescended Testes (UDT) .....</b>	<b>60</b>
<i>Juda Z. Jona</i>	
Incidence .....	60
Etiology .....	60
Clinical Presentation .....	60
Treatment .....	61
Outcomes .....	62
<b>16. Circumcision .....</b>	<b>63</b>
<i>Lars Göran Friberg and Juda Z. Jona</i>	
Male Circumcision .....	63
Female Circumcision .....	63
Phimosis .....	64
<b>17. Hemangiomas and Vascular Malformations .....</b>	<b>65</b>
<i>Maureen Sheehan and Daniel A. Bambini</i>	
Incidence .....	65
Etiology .....	65
Clinical Presentation .....	65
Diagnosis .....	66
Pathology .....	67
Treatment .....	67
<b>18. Branchial Cysts, Sinuses and Fistulas .....</b>	<b>69</b>
<i>Daniel A. Bambini</i>	
Incidence .....	69
Etiology .....	69
Clinical Presentation .....	70
Diagnosis .....	70



Pathology/Pathophysiology .....	70
Treatment .....	71
Outcome .....	71
<b>19. Thyroglossal Duct Cyst and Sinus .....</b>	<b>72</b>
<i>Daniel A. Bambini</i>	
Incidence .....	72
Etiology .....	72
Clinical Presentation .....	72
Diagnosis .....	74
Pathology .....	74
Treatment .....	74
Outcomes .....	74
<b>20. Umbilical Anomalies .....</b>	<b>75</b>
<i>Daniel A. Bambini</i>	
Incidence .....	75
Etiology .....	75
Clinical Presentation, Diagnosis, and Treatment .....	75
Outcomes .....	78
<b>21. Foreign Bodies of the Gastrointestinal Tract .....</b>	<b>79</b>
<i>John R. Wesley</i>	
Incidence .....	79
Etiology .....	79
Diagnosis .....	80
Treatment .....	80
Prevention .....	84
<b>22. Hypertrophic Pyloric Stenosis .....</b>	<b>85</b>
<i>Richard Fox and Daniel A. Bambini</i>	
Incidence .....	85
Etiology .....	85
Clinical Presentation .....	85
Diagnosis .....	86
Pathology .....	86
Treatment .....	86
Outcomes .....	88
<b>23. Intussusception .....</b>	<b>89</b>
<i>Vinh T. Lam</i>	
Incidence .....	89
Etiology .....	89
Pathology/Pathophysiology .....	89
Clinical Presentation .....	91
Diagnosis .....	91
Treatment .....	92
Outcomes .....	93

**24. Disorders of the Spleen ..... 94**

*Harry T. Papaconstantinou and Dai H. Chung*

Anomalies ..... 94  
Splenectomy ..... 94  
Hematologic Disorders ..... 95  
Cysts and Tumors ..... 97  
Hypersplenism ..... 97  
Postsplenectomy Sepsis ..... 97

**25. Rectal Prolapse and Anal Disorders ..... 99**

*Steve Szczerba*

Constipation ..... 99  
Rectal Prolapse ..... 101  
Anal Fissure ..... 104  
Perianal and Perirectal Abscess ..... 105  
Fistula-In-Ano ..... 106  
Hemorrhoids ..... 106  
Condyloma Acuminata ..... 107

**Section IV: Pediatric Trauma ..... 108**

**26. Initial Assessment and Resuscitation ..... 109**

*Matthew L. Moront and Fawn C. Lewis*

Organization ..... 109  
Primary Survey ..... 110  
Reassessment ..... 113  
Transition Phase ..... 113  
Secondary Survey ..... 113  
Tertiary Survey ..... 113

**27. Soft Tissue and Extremity Trauma ..... 115**

*Daniel A. Bambini and P. Stephen Almond*

Incidence ..... 115  
Etiology ..... 115  
Clinical Presentation ..... 115  
Diagnosis ..... 115  
Management ..... 115

**28. Facial Injuries ..... 120**

*Bahram Ghaderi and Diane Dado*

Incidence ..... 120  
Etiology ..... 120  
Clinical Presentation ..... 120  
Diagnosis ..... 121  
Pathophysiology ..... 121  
Treatment ..... 121

**29. Head and Spinal Cord Injuries in Children ..... 123**

*David Bentrem*

Head Injuries .....	123
Spinal Cord Injuries .....	125

**30. Abdominal Trauma ..... 128**

*John Hijjawi and Daniel A. Bambini*

Classification .....	128
Assessment .....	128
Diagnostic Evaluation .....	129
Splenic Injuries .....	129
Liver Injuries .....	130
Pancreatic Injuries .....	131
Intestinal Injuries .....	131

**31. Genitourinary Trauma ..... 132**

*Kate Abrahamsson and Fawn C. Lewis*

Renal Trauma .....	132
Ureteral Trauma .....	133
Bladder Trauma .....	133
Urethral Trauma .....	133
Scrotal Trauma .....	134
Labial Trauma .....	134
Penile Trauma .....	135
Sexual Abuse .....	135

**32. Thoracic Trauma ..... 136**

*Matthew L. Moront and Fawn C. Lewis*

Introduction .....	136
Immediately Life Threatening Injuries .....	136
Potentially Life Threatening Injuries .....	138

**33. Vascular Injuries ..... 141**

*Daniel A. Bambini*

Incidence .....	141
Etiology .....	141
Clinical Presentation .....	141
Diagnosis .....	142
Treatment .....	142
Outcomes .....	143

**34. Burns ..... 144**

*P. Stephen Almond and Heron E. Rodriguez*

Incidence .....	144
Etiology .....	144
Pathophysiology .....	144
Management .....	145
Airway, Breathing, Circulation .....	145

Secondary Survey .....	145
Fluid Resuscitation .....	145
Burn Wound Care .....	146
Nutrition .....	146
Pain Control .....	148

**35. Bites and Stings ..... 150**

*Heather Haukness and David Bentrem*

Animal Bites .....	150
Snake Bites .....	151
Spider Bites .....	152
Stings .....	152

**36. Neonatal Trauma and Birth Injuries ..... 153**

*Daniel A. Bambini*

Incidence .....	153
Head Injuries .....	153
Spine and Cord Injuries .....	155
Facial Fractures .....	155
Eye Injuries .....	155
Nerve Injuries .....	155
Pneumothorax .....	156
Abdominal Trauma .....	157
Skeletal Fractures .....	157
Iatrogenic Perforation of the Pharynx or Esophagus .....	157

**37. Child Abuse ..... 159**

*Matthew L. Moront and Fawn C. Lewis*

Definitions .....	159
Incidence .....	159
Clinical Presentation .....	159
Diagnosis .....	160
Patterns of Injury .....	160
Burns .....	162

**Section V: Pediatric Tumors ..... 163**

**38. Renal Tumors ..... 164**

*P. Stephen Almond*

Incidence .....	164
Etiology .....	164
Clinical Presentation .....	164
Diagnosis .....	165
Pathology .....	165
Staging .....	167
Treatment .....	167
Outcome .....	168

**39. Neuroblastoma ..... 169**

*Marybeth Madonna*

Background and Etiology .....	169
Pathology .....	169
Clinical Presentation .....	171
Staging .....	171
Diagnosis .....	172
Treatment .....	173
Outcomes .....	174

**40. Liver Tumors ..... 177**

*P. Stephen Almond*

Incidence .....	177
Etiology .....	177
Clinical Presentation .....	177
Diagnostic Studies .....	177
Pathology .....	178
Classification and Staging .....	179
Treatment .....	179
Outcomes .....	179

**41. Teratomas ..... 182**

*P. Stephen Almond*

Incidence .....	182
Etiology .....	182
Sacrococcygeal Teratoma .....	182
Ovarian Teratoma .....	184
Retroperitoneal Teratomas .....	185
Mediastinal Teratomas .....	185
Head and Neck Teratomas .....	185
Testicular Teratomas .....	186

**42. Ovarian Masses ..... 188**

*Robert M. Arensman*

Incidence .....	188
Etiology .....	188
Clinical Presentation .....	188
Diagnosis .....	188
Classification and Staging .....	189
Treatment .....	189

**43. Testicular Tumors ..... 193**

*Daniel A. Bambini*

Incidence .....	193
Etiology .....	193
Clinical Presentation .....	193
Diagnosis .....	193
Pathology .....	194

Classification and Staging .....	194
Treatment .....	194
Outcomes .....	195

#### **44. Gastrointestinal Tumors ..... 197**

*Ambrosio Hernandez and Dai H. Chung*

Esophagus .....	197
Stomach .....	197
Small Intestine .....	198
Appendix .....	198
Large Intestine .....	199

#### **45. Mediastinal Masses ..... 201**

*Vicky L. Chappell and Dai H. Chung*

Etiology and Embryology .....	201
Clinical Presentation .....	202
Diagnosis .....	203
Anterior and Superior Mediastinum .....	203
Middle Mediastinum .....	204
Posterior Mediastinum .....	204
Treatment .....	204
Outcome .....	205

#### **46. Breast Lesions ..... 206**

*Vinh T. Lam and Daniel A. Bambini*

Breast Development .....	206
Diagnostic Approaches to Breast Lesions .....	206
Congenital Breast Anomalies .....	207
Gynecomastia .....	207
Breast Asymmetry .....	208
Nipple Discharge .....	208
Fibroadenoma .....	208
Breast Infection .....	209
Cystosarcoma Phylloides .....	209
Breast Cancer .....	209

#### **47. Hodgkin's Lymphoma ..... 211**

*Lars Göran Friberg and Daniel A. Bambini*

Incidence .....	211
Etiology .....	211
Clinical Presentation .....	211
Diagnosis .....	212
Classification .....	212
Staging .....	212
Treatment .....	213
Outcomes .....	214

**48. Non-Hodgkin's Lymphoma ..... 215**

*Lars Göran Friberg and Daniel A. Bambini*

Incidence ..... 215  
Etiology ..... 215  
Classification ..... 215  
Clinical Presentation ..... 216  
Diagnosis ..... 217  
Staging ..... 217  
Treatment ..... 217  
Outcomes ..... 219

**49. Rhabdomyosarcoma and Other Soft Tissue Tumors .... 220**

*Marleta Reynolds*

Incidence ..... 220  
Clinical Presentation ..... 220  
Diagnosis ..... 220  
Pathology ..... 221  
Classification and Staging ..... 221  
Treatment ..... 221  
Outcomes ..... 221  
Lipomatous Tumors ..... 221  
Fibrous Tumors ..... 222

**50. Thyroid Masses ..... 224**

*Robert M. Arensman*

Incidence ..... 224  
Etiology ..... 224  
Clinical Presentation ..... 224  
Diagnosis ..... 224  
Pathophysiology ..... 225  
Classification ..... 225  
Treatment ..... 226  
Outcomes ..... 227

**Section VI: Gastrointestinal Hemorrhage ..... 228**

**51. Rectal Bleeding in Infancy ..... 229**

*Daniel A. Bambini*

Incidence ..... 229  
Etiology ..... 229  
Clinical Presentation ..... 229  
Diagnosis ..... 231  
Treatment ..... 231

**52. Polyps of the Gastrointestinal Tract ..... 232**

*Riccardo Superina*

Incidence ..... 232  
Etiology and Pathology ..... 232

Clinical Presentation .....	232
Diagnosis .....	233
Classification .....	233
Treatment .....	235

**53. Peptic Ulcer Disease and Gastritis..... 237**

*Heron E. Rodriguez*

Incidence .....	237
Pathophysiology .....	237
Clinical Presentation .....	238
Diagnosis .....	239
Medical Treatment .....	239
Surgical Treatment .....	239

**54. Portal Hypertension ..... 241**

*Kimberly Brown*

Anatomy and Physiology .....	241
Etiology .....	241
Incidence .....	242
Clinical Presentation .....	242
Diagnosis .....	242
Treatment .....	243
Outcome .....	244

**55. Meckel's Diverticulum ..... 245**

*Richard Fox*

Incidence .....	245
Etiology .....	245
Clinical Presentation .....	246
Diagnosis .....	247
Pathology/Pathophysiology .....	247
Treatment .....	247
Outcomes .....	248

**Section VII: Anomalies of the Gastrointestinal Tract ..... 249**

**56. Intestinal Obstruction in the Neonate ..... 250**

*Daniel A. Bambini*

Incidence .....	250
Etiology .....	250
Clinical Presentation .....	250
Diagnosis .....	252
Pathology/Pathophysiology .....	252
Classification and Staging .....	253
Treatment .....	253
Outcomes .....	253



<b>57. Pyloric and Duodenal Obstruction .....</b>	<b>254</b>
<i>Daniel A. Bambini</i>	
Incidence .....	254
Etiology .....	254
Clinical Presentation .....	254
Differential Diagnosis .....	255
Diagnosis .....	255
Pathology and Classification .....	255
Treatment .....	258
Outcomes .....	259
<b>58. Malrotation and Volvulus .....</b>	<b>260</b>
<i>Vinh T. Lam</i>	
Incidence .....	260
Etiology .....	260
Classification .....	261
Clinical Presentation .....	261
Diagnosis .....	261
Treatment .....	262
Outcomes .....	264
<b>59. Atresia and Stenosis.....</b>	<b>265</b>
<i>P. Stephen Almond</i>	
Incidence .....	265
Etiology .....	265
Pathology/Pathophysiology .....	265
Classification and Staging .....	265
Clinical Presentation .....	265
Diagnosis .....	266
Treatment .....	266
Outcomes .....	267
<b>60. Meconium Ileus .....</b>	<b>268</b>
<i>Vinh T. Lam</i>	
Incidence .....	268
Etiology .....	268
Pathology/Pathophysiology .....	268
Classification .....	269
Clinical Presentation .....	269
Diagnosis .....	270
Treatment .....	270
Outcomes .....	271
<b>61. Hirschsprung's Disease .....</b>	<b>272</b>
<i>Robert M. Arensman</i>	
Incidence .....	272
Etiology .....	272
Clinical Presentation .....	272

Diagnosis .....	273
Pathophysiology .....	274
Treatment .....	274

**62. Colonic Atresia ..... 276**

*P. Stephen Almond*

Incidence .....	276
Etiology .....	276
Clinical Presentation .....	276
Diagnosis .....	276
Classification .....	276
Treatment .....	277

**63. Gastrointestinal Duplications and Mesenteric Cysts ..... 278**

*Riccardo Superina and Daniel A. Bambini*

Gastrointestinal Duplications .....	278
Mesenteric Cysts .....	281

**Section VIII: Peritonitis in Infancy ..... 284**

**64. Necrotizing Enterocolitis ..... 285**

*Fawn C. Lewis*

Incidence .....	285
Etiology .....	285
Classification .....	285
Pathology/Pathophysiology .....	285
Clinical Presentation .....	287
Diagnosis .....	287
Treatment .....	287
Outcomes .....	290

**65. Gastrointestinal Perforation in the Newborn ..... 293**

*Daniel A. Bambini*

Incidence .....	293
Etiology and Pathophysiology .....	293
Clinical Presentation .....	293
Diagnosis .....	294
Treatment .....	294
Outcomes .....	294

**66. Neonatal Ascites ..... 295**

*Vinh T. Lam and Daniel A. Bambini*

Incidence .....	295
Urinary Ascites .....	295
Biliary Ascites .....	296
Chylous Ascites .....	297
Outcomes .....	298

**Section IX: Jaundice in Infancy and Childhood ..... 299**

**67. Biliary Atresia ..... 300**

*Riccardo Superina*

Incidence .....	300
Etiology .....	300
Clinical Presentation .....	300
Diagnosis .....	301
Pathology .....	301
Classification and Staging .....	302
Treatment .....	302
Outcomes .....	302

**68. Choledochal Cysts ..... 304**

*Riccardo Superina*

Incidence .....	304
Etiology .....	304
Clinical Presentation .....	304
Diagnosis .....	305
Pathology .....	305
Classification .....	305
Treatment .....	307
Outcomes .....	307

**Section X: Respiratory Distress ..... 309**

**69. Upper Airway Obstruction in the Newborn ..... 310**

*Daniel A. Bambini*

Incidence .....	310
Etiology .....	310
Pathology/Pathophysiology .....	310
Clinical Presentation .....	310
Diagnosis .....	312
Treatment .....	312

**70. Vascular Rings ..... 314**

*Robert M. Arensman*

Incidence .....	314
Etiology .....	314
Clinical Presentation .....	314
Diagnosis .....	315
Pathophysiology .....	315
Treatment .....	315

**71. Tracheoesophageal Fistula and Esophageal Atresia ..... 318**

*Daniel A. Bambini*

Incidence .....	318
Etiology .....	318

Classification .....	318
Pathology/Pathophysiology .....	320
Clinical Presentation .....	320
Diagnosis .....	321
Treatment .....	321
Outcomes .....	322

**72. Diaphragmatic Anomalies ..... 325**

*Daniel A. Bambini*

Incidence .....	325
Etiology .....	325
Clinical Presentation .....	326
Diagnosis .....	326
Pathology/Pathophysiology .....	327
Treatment .....	330
Outcomes .....	331

**73. Congenital Malformations of the Lung..... 333**

*Marleta Reynolds*

Congenital Lobar Emphysema .....	333
Pulmonary Sequestration .....	333
Congenital Cystic Adenomatoid Malformation (CCAM) .....	335
Bronchogenic Cyst .....	337

**74. Foreign Bodies in the Air Passages and Esophagus ..... 339**

*Marleta Reynolds*

Foreign Bodies in the Esophagus .....	339
Foreign Bodies of the Air Passages .....	341

**75. Chylothorax and Diseases of the Pleura..... 344**

*Harry T. Papaconstantinou and Dai H. Chung*

Chylothorax .....	344
Empyema .....	348
Spontaneous Pneumothorax .....	349

**76. Patent Ductus Arteriosus ..... 352**

*Samer Kanaan and Daniel A. Bambini*

Incidence .....	352
Etiology .....	352
Clinical Presentation .....	353
Diagnosis .....	354
Treatment .....	354
Outcomes .....	354

**Section XI: Congenital Malformations of the Chest Wall,  
Abdominal Wall and Perineum ..... 356**

**77. Chest Wall Deformities ..... 357**

*Marleta Reynolds*

Pectus Excavatum .....	357
Pectus Carinatum .....	359
Poland's Syndrome .....	359
Sternal Clefts and Ectopia Cordis .....	359

**78. Abdominal Wall Defects ..... 361**

*Grant H. Geissler*

Incidence .....	361
Omphalocele .....	361
Clinical Presentation .....	362
Treatment .....	363
Outcomes .....	365

**79. Anorectal Malformations ..... 366**

*P. Stephen Almond*

Incidence .....	366
Etiology .....	366
Classification .....	366
Clinical Presentation .....	367
Diagnosis .....	367
Treatment .....	367
Outcomes .....	371

**80. Urogenital Sinus, Cloaca, and Cloacal Exstrophy ..... 372**

*Robert M. Arensman*

Definitions .....	372
Embryogenesis .....	372
Incidence .....	372
Associated Anomalies .....	372
Diagnosis .....	373
Treatment .....	374
Results .....	374

**Section XII: Functional and Acquired Disorders  
of the Esophagus ..... 375**

**81. Gastroesophageal Reflux ..... 376**

*Grant H. Geissler*

Introduction and Incidence.....	376
Embryology and Anatomy .....	376
Clinical Presentation .....	377
Diagnostic Studies .....	377
Medical Therapy .....	378
Surgical Therapy and Long-Term Results .....	378

**82. Achalasia ..... 380**

*David Bentrem*

Incidence ..... 380  
Etiology ..... 380  
Pathophysiology ..... 380  
Clinical Presentation ..... 380  
Diagnosis ..... 381  
Treatment ..... 381

**83. Caustic Esophageal Injury and Perforation ..... 383**

*Christina L. Dial and Daniel A. Bambini*

Incidence ..... 383  
Etiology ..... 383  
Classification and Pathophysiology ..... 384  
Clinical Presentation ..... 384  
Treatment ..... 384  
Outcomes ..... 385

**Section XIII: Gastrointestinal Diseases  
of the Older Child ..... 387**

**84. Appendicitis ..... 388**

*Steve Szczerba*

Incidence ..... 388  
Etiology ..... 388  
Clinical Presentation ..... 388  
Diagnosis ..... 390  
Pathology/Pathophysiology ..... 391  
Treatment ..... 391  
Outcomes ..... 392

**85. Adhesive Intestinal Obstruction ..... 393**

*Todd R. Vogel*

Incidence ..... 393  
Etiology ..... 393  
Clinical Presentation ..... 393  
Diagnosis ..... 393  
Treatment ..... 394

**86. Gallbladder Disease in Childhood ..... 395**

*Fawn C. Lewis*

Incidence ..... 395  
Etiology ..... 395  
Clinical Presentation ..... 396  
Diagnosis ..... 396  
Treatment ..... 398  
Outcomes ..... 398

<b>87. Superior Mesenteric Artery (SMA) Syndrome .....</b>	<b>400</b>
<i>Todd R. Vogel</i>	
Incidence .....	400
Etiology .....	400
Clinical Presentation .....	400
Diagnosis .....	400
Treatment .....	401
<b>88. Inflammatory Bowel Disease .....</b>	<b>402</b>
<i>Christopher Mascio and Daniel A. Bambini</i>	
Incidence and Etiology .....	402
Ulcerative Colitis .....	402
Crohn's Disease .....	405
<b>89. Disorders of the Pancreas .....</b>	<b>408</b>
<i>Todd R. Vogel</i>	
Pancreatic Embryology and Anatomy .....	408
Acute Pancreatitis .....	408
Chronic Relapsing Pancreatitis .....	410
Pancreatic Cysts .....	410
Congenital Pancreatic Abnormalities .....	411
Pancreatic Neoplasms .....	412
<b>Section XIV: Endocrine Disorders .....</b>	<b>414</b>
<b>90. Pheochromocytoma .....</b>	<b>415</b>
<i>Richard Fox</i>	
Incidence .....	415
Clinical Presentation .....	415
Diagnosis .....	416
Pathology/Pathophysiology .....	417
Treatment .....	417
Outcomes .....	419
<b>91. Hyperparathyroidism .....</b>	<b>420</b>
<i>P. Stephen Almond</i>	
Incidence .....	420
Etiology .....	420
Clinical Presentation .....	421
Diagnosis .....	421
Pathology/Pathophysiology .....	421
Treatment .....	421
Outcomes .....	422
<b>92. Neonatal Hypoglycemia .....</b>	<b>424</b>
<i>Daniel A. Bambini</i>	
Incidence .....	424
Etiology .....	424

Pathology/Pathophysiology .....	424
Clinical Presentation .....	425
Diagnosis .....	426
Treatment .....	426
Outcomes .....	427

**93. Intersex ..... 428**

*Daniel A. Bambini*

Incidence .....	428
Development of the Gonads and Genitalia .....	428
Classification and Etiology .....	429
Clinical Presentation .....	430
Diagnosis .....	431
Treatment .....	431
Outcomes .....	433

**Section XV: Miscellaneous Pediatric Surgical Topics ..... 434**

**94. Short Bowel Syndrome ..... 435**

*Fawn C. Lewis and Daniel A. Bambini*

Incidence and Etiology .....	435
Pathophysiology .....	435
Clinical Presentation .....	436
Initial Treatment .....	437
Late Treatment .....	437
Outcomes .....	438

**95. Conjoined Twins ..... 439**

*Robert M. Arensman*

Incidence .....	439
Etiology .....	439
Classification .....	439
Clinical Presentation .....	439
Diagnosis .....	440
Treatment .....	440
Outcomes .....	440

**96. Minimally Invasive Pediatric Surgery ..... 443**

*Harry T. Papaconstantinou and Dai H. Chung*

Indications .....	443
Equipment .....	443
General Considerations .....	444
Appendectomy .....	445
Fundoplication and Gastrostomy .....	445
Splenectomy .....	446
Pyloromyotomy .....	446
Contralateral Inguinal Exploration .....	447
Nonpalpable Testis .....	447



Pull-Through for Hirschsprung's Disease .....	447
Thoracoscopy .....	448
Summary .....	449

<b>Appendix I: Common Drugs and Dosages Used in Pediatric Surgical Patients .....</b>	<b>450</b>
<b>Index .....</b>	<b>459</b>

## Editors

### **Robert M. Arensman, M.D.**

Surgeon-in-Chief  
Division of Pediatric Surgery  
Lydia J. Fredrickson Professor of Pediatric Surgery  
Children's Memorial Hospital  
Northwestern University  
Chicago, Illinois, U.S.A.  
*Chapters 1, 3, 42, 50, 61, 70, 80, 95*

### **Daniel A. Bambini, M.D.**

Fellow in Pediatric Surgery  
Division of Pediatric Surgery  
Children's Memorial Hospital  
Northwestern University  
Chicago, Illinois, U.S.A.  
*Chapters 2, 17-20, 22, 27, 30, 33, 36, 43, 46-48,  
51, 53, 56, 57, 63, 65, 66, 69, 71, 72, 76, 83, 88, 92-94*

### **P. Stephen Almond, M.D.**

Assistant Professor of Surgery  
Director of Trauma  
Divisions of Pediatric Surgery and Transplantation  
Children's Memorial Hospital  
Northwestern University  
Chicago, Illinois, U.S.A.  
*Chapters 27, 34, 38, 40, 41, 59, 62, 79, 91*

## Contributors

Kate Abrahamsson  
Divisionen för barn-och  
ungdomssjukvård Kirurgi  
Queen Silvia Children's Hospital  
Sahlgrenska Universitetssjukhuset/Östra  
Göteborg, Sweden  
*Chapter 31*

David Bentrem  
Department of General Surgery  
Northwestern Memorial Hospital  
Northwestern University  
Chicago, Illinois, U.S.A.  
*Chapters 29, 35, 82*

Kimberly Brown  
Department of General Surgery  
Loyola University Medical Center  
Maywood, Illinois, U.S.A.  
*Chapter 54*

Vicky L. Chappell  
Department of Surgery  
University of Texas  
Medical Branch at Galveston  
Galveston, Texas, U.S.A.  
*Chapter 45*

Dai H. Chung  
Division of Pediatric Surgery  
University of Texas  
Medical Branch at Galveston  
Galveston, Texas, U.S.A.  
*Chapters 24, 44, 45, 75, 96*

Diane Dado  
Division of Plastic Surgery  
Loyola University Medical Center  
Maywood, Illinois, U.S.A.  
*Chapter 28*

Christina L. Dial  
Department of General Surgery  
St. James Hospital and Medical Center  
Midwestern University  
Olympia Fields, Illinois, U.S.A.  
*Chapter 83*

Richard Fox  
Office of Graduate Medical Education  
Loyola University Medical Center  
Maywood, Illinois, U.S.A.  
*Chapters 10, 22, 55, 90*

Lars Göran Friberg  
Divisionen för barn-och  
ungdomssjukvård Kirurgi  
Queen Silvia Children's Hospital  
Sahlgrenska Universitetssjukhuset/Östra  
Göteborg, Sweden  
*Chapters 3, 4, 16, 47, 48*

Grant Geissler  
Department of Pediatric Surgery  
Children's Memorial Hospital  
Northwestern University  
Chicago, Illinois, U.S.A.  
*Chapters 78, 81*

Bahram Ghaderi  
Division of Plastic Surgery  
Loyola University Medical Center  
Maywood, Illinois, U.S.A.  
*Chapter 28*

Heather Haukness  
Department of Pediatrics  
Children's Memorial Hospital  
Northwestern University  
Chicago, Illinois, U.S.A.  
*Chapter 35*

Ambrosio Hernandez  
Department of Surgery  
University of Texas  
Medical Branch at Galveston  
Galveston, Texas, U.S.A.  
*Chapter 44*

John Hijjawi  
Department of Plastic Surgery  
Northwestern Memorial Hospital  
Northwestern University  
Chicago, Illinois, U.S.A.  
*Chapter 30*

Juda Z. Jona  
Division of Pediatric Surgery  
Evanston Hospital  
Evanston, Illinois, U.S.A.  
*Chapters 12-16*

Samer Kanaan  
Department of General Surgery  
Northwestern Memorial Hospital  
Northwestern University  
Chicago, Illinois, U.S.A.  
*Chapter 76*

Vinh T. Lam  
Children's Surgical Associates  
Orange, California, U.S.A.  
*Chapters 23, 46, 58, 60, 66*

Fawn C. Lewis  
Division of Pediatric Surgery  
Children's Memorial Hospital  
Chicago, Illinois, U.S.A.  
*Chapters 31, 37, 64, 86, 94*

Marybeth Madonna  
Division of Pediatric Surgery  
Children's Memorial Hospital  
Chicago, Illinois, U.S.A.  
*Chapters 8, 39*

Christopher Mascio  
Department of General Surgery  
Loyola University Medical Center  
Loyola University  
Maywood, Illinois, U.S.A.  
*Chapter 88*

Matthew L. Moront  
Specialty Surgeons of Pittsburgh  
Pittsburgh, Pennsylvania, U.S.A.  
*Chapters 9, 26, 32, 37, 94*

Harry T. Papaconstantinou  
Department of Surgery  
University of Texas  
Medical Branch at Galveston  
Galveston, Texas, U.S.A.  
*Chapters 24, 75, 96*

Marleta Reynolds  
Division of Pediatric Surgery  
Children's Memorial Hospital  
Chicago, Illinois, U.S.A.  
*Chapters 5, 49, 73, 74, 77*

Heron E. Rodriguez  
Catholic Health Partners  
Columbus Hospital  
Chicago, Illinois, U.S.A.  
*Chapters 34, 53*

Maureen Sheehan  
Department of General Surgery  
Loyola University Medical Center  
Loyola University  
Maywood, Illinois, U.S.A.  
*Chapter 17*

Riccardo Superina  
Division of Pediatric Surgery  
Children's Memorial Hospital  
Chicago, Illinois, U.S.A.  
*Chapters 11, 52, 63, 67, 68*

Steve Szczerba  
Department of General Surgery  
Northwestern Memorial Hospital  
Northwestern University  
Chicago, Illinois, U.S.A.  
*Chapters 25, 84*

Todd R. Vogel  
Department of General Surgery  
Robert Wood Johnson University Hospital  
University of Medicine and Dentistry  
of New Jersey  
New Brunswick, New Jersey, U.S.A.  
*Chapters 85, 87, 89*

John R. Wesley  
Medical Director and Vice President  
of Medical and Professional Affairs  
Baxter Healthcare  
Roundlake, Illinois, U.S.A.  
*Chapters 6, 7, 21*



# Preface

---

---

This modest manual of pediatric surgery has been prepared as a ready reference for information on the common surgical problems of childhood.

It represents basic information that is reasonably known or proven with little if any theory or speculation. It is intended to provide information needed to diagnose, to choose diagnostic studies or to begin treatment.

The information contained herein is a point of departure that leads on to the further study of problems or conditions that afflict our children.

*The Editors*  
*Chicago, Illinois*

## **Section I: Assessment of the Pediatric Surgical Patient**

# Preoperative Care

*Robert M. Arensman*

## Consultation

Prior to surgery for any patient, surgical consultation occurs. This provides a meeting and introduction between child and surgeon and proceeds to a complete history and physical examination. Since many children meet a surgeon for the first time on referral, the results of a prior history and physical examination are often available. If that is the case the previous findings are reviewed, verified, and further information is sought that may elucidate the diagnosis.

The meeting may be brief but creates the foundation for further interaction between surgeon and child. It is certainly an opportunity for the surgeon to create a friendship, or at least trust, between a frightened child and the person who will ultimately perform surgery. This meeting also is the chance to create communication and trust with anxious parents. Consequently, child and parents must be given adequate opportunity to present their understanding of the diagnosis, raise questions concerning surgery and in-hospital care, and discuss worrisome questions such as pain control, postoperative management, ultimate outcome and long-term results.

If a crowded clinic schedule precludes adequate time to cover all aspects of anticipated surgery, it is quite appropriate to schedule further visits or simply to arrange time for phone conferences with all concerned. Frequently, the surgeon can include other significant family members (grandparents, aunts, and uncles, siblings) by arranging for evening phone conversations.

Since many presurgical patients have already undergone diagnostic testing, it is important to review these tests and share the surgeon's interpretation with the child and family. Sometimes this entails consultation with other specialists at the children's hospital (radiologist, pathologists, and pediatric subspecialists). The results of these consultations will generally not be available at the time of the surgical consultation, but the results or discussion can easily be shared with child and family members via phone, e-mail, or fax. Communication at present is one of the easier, but most important, aspects of patient care.

## Physical Examination

Abnormal findings on physical examination are often reported to a surgeon prior to the patient encounter. This does not preclude another examination at the time of the consultation visit. Additional findings may be demonstrated, and certainly one wishes to confirm the previously reported findings. Such simple matters as hernias or hydroceles are often confused and need the careful reexamination of the pediatric



surgeon to clarify. In addition, associated findings, well known to the pediatric surgeon, may not be common knowledge to the referring pediatrician or family practitioner. Therefore, a good physical examination is always advisable prior to surgical intervention.

### **Diagnostic Studies and Laboratory Investigations**

The need for diagnostic studies varies from none to extensive. In the case of a child with a reducible inguinal hernia, a good, but simple, physical examination constitutes the best diagnostic study. Further tests, radiographs, blood examinations, etc. are invasive, bothersome, expensive and unwarranted unless there are other findings or complaints. However, the child who presents with severe, recurrent abdominal pain without any physical findings may need extensive studies to demonstrate the causative pathology (or lack thereof). Suffice to say, diagnostic studies are chosen and done that are needed to completely and safely make a diagnosis and sufficient to advise a child and family concerning the need for surgical intervention.

It is clear that a healthy child on a standard diet requires nothing as far as preoperative testing if the surgical problem is simple, can be done under outpatient general anesthetic without hospital stay. For example, a two-year-old child with uncomplicated bilateral inguinal hernias, eating until a few hours before surgery, whose cheeks and lips betray no sign of anemia can and should undergo operative repair without diagnostic testing. Careful questioning of the family history adequately excludes inherited diseases and bleeding dyscrasias. Examination of the child provides all the further information needed to make a correct decision concerning the need for further tests. In contrast, a two-year-old child with previous diagnosis of biliary atresia with unsuccessful Kasai procedure and progressive biliary cirrhosis clearly needs a very complicated and extensive diagnostic evaluation to allow a determination as to whether he can undergo hepatic transplantation.

In summary, the diagnostic regimen is designed to be sufficiently brief or thorough to correctly and adequately identify the surgical problem(s) and formulate the best and safest surgical plan.

### **Pain Management**

One of the greatest concerns for child or parents when approaching a surgical event is the problem of postoperative pain control. Most children are not particularly concerned about the technical details of the surgery they will undergo, but they are greatly fearful of the pain that they endure in the postoperative period. Knowledge that this can be controlled in a variety of ways provides some comfort. Knowledge that they will also be in the company of their parents during this period of time is also vitally important.

Consequently, the consultation visit or phone conferences include a thorough discussion of postoperative pain management. Commonly used methods of pain control include intraoperative local anesthetic administration, intravenous narcotics, patient controlled analgesia, caudal blocks, epidural blocks and continuous epidural anesthesia. Although these can all be discussed before the surgical event, it is generally best to provide at least one to two hours in the preanesthetic room so this can be discussed a second time with the anesthesia staff. This is the time of the final decision concerning the exact pain control methods to be used. Since this is often

tailored to fit the anesthesia used during the operative event, the anesthesiologist is included in this decision.

## **Blood Donation**

Due to the tremendous information on the hazards of blood transfusion, most parents want to discuss possible transfusion thoroughly. Since transfusion is a rare event, discussion can be limited to acknowledgement that transfusion is most unlikely, and so much so that blood is not routinely prepared for the operation anticipated. In the event that transfusion is a possibility, discussion centers on the use of banked blood versus donor directed blood. This is both a controversial and emotional subject so it is sometimes necessary to involve the director of the blood bank service to fully elucidate the questions posed. Parents must fully understand that blood samples will be necessary from child and donors prior to the surgical date. Furthermore, they need to fully understand that all donor directed blood is subjected to the same testing required for all other blood donations. Finally, parents need to understand that type match does not necessarily predict cross match and that fulfillment of all these requirements requires adequate time before the surgery date.

## **Presurgical Visitation and Teaching**

Most children's hospitals provide a presurgical visitation and teaching program. These programs allow children to visit all portions of the operative suite prior to surgery. They become familiar with the holding area, the operating room, and the postanesthesia recovery area. They have an opportunity to try on "scrubs", gowns, masks and caps. The nurses from the various areas answer questions, reassure the children of their parent's nearness and participation in the entire process, and particularly address concerns about postoperative pain. In our particular hospital, the children conclude the visit by making a mural that is taped to the entry hall wall. As the children pass to the operating rooms, they can look for their previous artwork. We hope it lessens their anxiety and certainly endorse the use of these programs if available.

## ***Selected Readings***

1. Puri P, Sweed Y. Preoperative assessment. In: Puri P, ed. *Newborn Surgery*. Oxford: Butterworth-Heinemann 1996; 41-51.
2. Albanese CT, Rowe MI. Preoperative and postoperative management of the neonate. In: Spitz L, Coran AG, eds. *Operative Surgery*. London: Butterworth 1995; 5-12.

# Immediate Postoperative Care

*Daniel A. Bambini*

The postoperative care of surgical neonates and children begins upon completion of wound closure. The level of postoperative care administered is dependent upon the procedure performed but some general guidelines are provided below. Specific guidelines for postoperative management of many pediatric surgical conditions are provided throughout this handbook.

## Wound and Dressing Care

Prior to the removal of the sterile surgical drapes, the skin surrounding the surgical wound is cleansed with warm saline-soaked sponges or lap pads to remove any debris, blood, or prep solutions surrounding the wound. The area is gently padded dry and a sterile towel or dressing is placed over the wound to prevent contamination at the time of drape removal. The type of dressing applied to surgical wounds is selected according to surgeon preference, the type of wound created, and the method of closure. For clean procedures, a dry, sterile dressing (i.e., gauze, steri strips, Opsite®, Tegrederm®) is suitable. Antibiotic ointments and other wound applicants are generally not necessary. To minimize the stress and pain of later dressing removal, dressings are secured in position with the minimal amount of tape or occlusive barrier that achieves coverage of the wound.

## Extubation and Transfer

Intraoperative monitoring devices should be left in place until after extubation. A physician member of the surgical team should be present at the time of extubation and assist in the transfer of the pediatric surgical patient to the postanesthesia care unit or appropriate intensive care unit. If respiratory rate or inspiratory tidal volumes are inadequate, the child should be observed in the OR until breathing has improved. Special attention to body temperature and measures to prevent hypothermia after drape removal should be instituted including infrared heating lights, wrapping with warm blankets, and increasing the ambient room temperature.

## Postoperative Orders

The postoperative orders are individualized for each patient. In general, outpatient procedures will require only simple postoperative care and specific wound care instructions for the parents. Arrangements for office follow-up visits are discussed. A general outline for writing postoperative orders in postsurgical pediatric patients is provided below.

### *Admission Order*

Specific information regarding the type of bed and/or location within the hospital to which the patient goes after recovery is listed. Arrangements for intensive care unit beds are made preoperatively. If observation status or discharge from the recovery unit is desired, specific instructions regarding wounds, medications, and anticipated clinical course/problems are provided to the parents or primary caregiver.

### *Attending Physician and Consultants*

List the attending physician and all consultants who will participate in the care of the patient. In addition, one specifies which physician(s) and/or service(s) will be the primary providers of postoperative care and orders. The nursing staff must be clearly informed regarding who is contacted for questions about care and for any problems that arise.

### *Diagnosis*

List the primary diagnosis and/or the procedure that has been performed.

### *Allergies*

List any known drug allergies or other sensitivities (i.e., latex, tape, antibiotics, pain medications, etc.)

### *Admission Weight*

The patient's preoperative weight is specified. This is the weight that is used to calculate medication dosages, fluids, nutritional requirements, etc.

### *Vital Signs*

Provide instructions for the frequency at which vital signs are monitored and recorded. Parameters for changes in vital signs that require notification of the surgical team are clearly specified.

### *Monitoring Equipment*

List any special monitoring devices that are appropriate for postoperative care including pulse oximetry, apnea and/or cardiac monitors, etc.

### *Ventilator Settings and Respiratory Care*

For patients requiring postoperative ventilatory support, specific instructions regarding ventilator mode, tidal volume, peak inspiratory pressure, inspired oxygen concentration, etc. are provided. If other respiratory interventions (i.e., nebulizers, chest physiotherapy, frequent suctioning) are required, specific written orders are made.

### *Intravenous Fluids*

Maintenance and replacement fluid orders are provided. Specific information regarding postoperative fluid and electrolyte management is provided in Chapter 7.

### *Diet*

Special diets (i.e., clear liquids, general diet) or oral restriction (i.e., NPO) are specified, including orders for initiation of enteral tube feedings when applicable.

### ***Activity***

Level of activity and/or restriction (i.e., bedrest, ambulation, etc.) is specified. Physical therapy may be helpful to some hospitalized patients and is initiated when appropriate.

### ***Medications***

All medications including doses, routes of administration, and frequencies of administration are recorded clearly and accurately. Analgesic and antiemetic medications are ordered when appropriate. Doses are calculated on a per weight basis.

### ***Wound Care***

Special instructions for dressing care or surgical wounds are provided when applicable.

### ***Drains***

Drain care orders include specific requests for suction, stripping, frequency of emptying, and quantification of output. Nasogastric tubes are placed to suction or gravity drainage according to attending surgeon preference. Foley catheters are placed to gravity drainage.

### ***Special Studies***

Any radiographic exams or follow-up studies are specified, and the radiology department and/or attending radiologist should be notified of all requests. Chest radiographs are obtained in the recovery room or intensive care unit for all patients who remain intubated or who had intraoperative placement of central venous lines or catheters.

### ***Laboratory Tests***

Routine laboratory testing is often not necessary in pediatric surgical patients, especially those who have procedures in the surgicenter and are discharged shortly after surgery. Specific laboratory studies are obtained if the results are expected to alter clinical management of the patient. Laboratory tests are often indicated in children who undergo extensive and complicated procedures.

### ***Pain Management***

Achieving adequate pain relief is important in children, although children often do not or cannot complain specifically of pain. Pain may adversely affect recovery of infants since painful stimuli may result in decreased arterial saturation and increased pulmonary vascular resistance. Effective pain control allows earlier ambulation and faster recovery in older children.

Local anesthetics administered in the operating room can provide prolonged pain control. Local wound infiltration or regional nerve blocks with bupivacaine (Sensorcaine®) provide pain control for 4-6 hours following an operation. The maximum dose is 3 mg/kg given as a 0.25-0.75% solution.

For larger operations, intravenous narcotics provide excellent pain control. Liberal use of patient controlled analgesia devices and epidural catheters improve postoperative pain control after many abdominal or thoracic operations.

***Selected Readings***

1. Filston HC, Izant, Jr. RJ. The surgical neonate: Evaluation and care, 2<sup>nd</sup> edition. Norwalk, CT: Appleton-Century-Crofts 1985.
2. Raffensperger JG. Immediate postoperative care. In: Raffensperger JG ed. Swenson's Pediatric Surgery, 5<sup>th</sup> edition. Norwalk, CT: Appleton & Lange 1990; 27–28.

# Anemia

*Robert M. Arensman and Lars Göran Friberg*

Unlike many Chapters of this handbook that deal with a specific surgical condition, this short Chapter touches on a physiologic state that has great importance to the surgeon. Anemia denotes a state in which a patient has less than normal hemoglobin. In this situation, decreased oxygen transport may decrease wound healing, may increase cardiac stress during or after surgical event, and may predispose to a variety of postoperative complications. Fortunately, all these anemia problems are less likely in the pediatric patient, but still one must consider carefully the presence of anemia, its probable cause, whether it should be corrected (how and how quickly), and its chance of seriously affecting surgical outcome.

## Definition

Generally, anemia is defined as hemoglobin less than 10 grams/deciliter. The normal value for adults and older children is 12-16 grams/deciliter. However, this value may be higher in the newborn and will characteristically fall below this normal range during the first 1-2 months of life.

## Physiologic Anemia

Babies rapidly lower their hemoglobin in the neonatal period. Values often fall to the 9-10 g/dl level with corresponding hematocrits of 25-30%. This change is normal and reflects a slow initiation of hematopoiesis by the neonatal bone marrow. If surgery is necessary during this period, the surgical and anesthesiological staff must decide whether the transfusion of blood outweighs risks of transfusion and delay of hematopoiesis onset.

## Iron Deficiency

Iron supplies are transferred to a neonate late in intrauterine life. These supplies may be low in preterm children, just as the supply of other nutrients, vitamins, minerals are low in early children. If there is no compelling reason to correct the anemia quickly, the infant is given iron orally. This is absorbed in the duodenum and proximal jejunum and nicely corrects the problem. Parental iron or transfusion are the alternatives if this deficiency must be corrected quickly.

## Hereditary Spherocytosis

This is an autosomal dominant disease process that prevents red cells from assuming their characteristic biconcave shape. The elliptical red blood cells do not move easily through the capillary bed or the pulp of the spleen. Red cells thus

entrapped are more rapidly destroyed, resulting in splenomegaly, jaundice, and anemia. The presence of a family history consistent with this disease and the observation of spherocytes and reticulocytes on a peripheral blood smear confirm the diagnosis. Further confirmation involves demonstration of increased cellular fragility in the osmotic fragility test. These children are highly prone to the development of gallstones and concomitant biliary tract disease. Thus, they need full evaluation of those structures if they are coming to splenectomy to control the spherocytosis.

### Sickle Cell Anemia

This is the most common inherited disorder of the African American population. Up to 10% of this population is affected. This disease is an autosomal recessive trait and requires the homozygous state for expression of the full-blown disease. Most of these patients have anemia, leukocytosis, jaundice, and perhaps splenomegaly early. By teenage years, the spleen usually shrinks from progressive infarction and fibrosis. However, these children by then often also have biliary stones and biliary tract disease.

In severe forms of this disease, children have painful crises that involve bone pain, severe right and left upper abdominal pain, strokes, and pulmonary infarctions. Many of these children develop osteomyelitis and leg ulcers.

A peripheral smear demonstrates sickle shaped red blood cells, especially when crisis is occurring. However, today most of these children are quickly diagnosed at the time of birth through mandated state screening programs. Hemoglobin electrophoresis confirms the presence of hemoglobin S and indicates the zygosity. Prenatal diagnosis is possible through amniocentesis and DNA analysis.

Although surgeons are not generally asked to manage children with this disease, they are frequently asked to consult for abdominal pain. When surgery is necessary for appendicitis, biliary problems, etc., it is important that the surgeon know how to manage these children to optimize outcome. Preoperative suppressive transfusions, exchange transfusions, meticulous hydration and prevention of hypoxia all are important aspects of preoperative, intraoperative, and postoperative care.

### Other Anemias

Diverse other anemic states more rarely come to the attention of pediatric surgeons. Generally, the request is to assist with a complication of the anemia, most often splenomegaly or biliary complications such as cholelithiasis. Care should be used to correct the anemia to the degree possible before operation. If this is not possible, the surgeon must try to optimize care to prevent postoperative complications associated with low red blood volume and decreased oxygen transport.

### Selected Readings

1. In: Behrman LE, Kliegman RM, Jenson HB, eds. *Nelson Textbook of Pediatrics*. Philadelphia: W.B. Saunders Company, 16<sup>th</sup> edition, Chapters 452-471. 2000; 481-490.
2. Oski FA. The erythrocyte and its disorders. In: Nathan DG, Oski FA, eds. *Hematology of Infancy and Childhood*, 3<sup>rd</sup> edition. Philadelphia: W.B. Saunders 1987.
3. Seeler RA, Shwiaki MZ. Acute splenic sequestration crises (ASSC) in young children with sickle cell anemia. *Clin Pediatr* 1972; 11:701.
4. Rennels MB et al. Cholelithiasis in patients with major sickle hemoglobinopathies. *Am J Dis Child* 1983; 138:66.



# Genetics and Prenatal Diagnosis in Pediatric Surgery

*Lars Göran Friberg*

Serious malformations occur in 1.5% of all births. For half of these children the etiology is unknown; the other half have a documented genetic or teratogenic cause. The importance of prenatal diagnosis lies in its ability to give parents several options. If there are malformations or conditions incompatible with life, the pregnancy can be terminated. If the malformation is correctable at term, surgery can take place after delivery. For some malformations, progressive adverse effects in utero may warrant consideration of early delivery or fetal surgery.

Modern obstetric care includes close monitoring during pregnancy and various prenatal screening-tests, such as alpha-fetoprotein screening and prenatal ultrasonography. Fetal ultrasonography is routinely performed around the 18th gestational week. Occasionally, there are indications for more invasive screening tests, such as chorionic villus sampling, amniocentesis, fetoscopy, fetal sampling, and percutaneous umbilical blood sampling.

Early detection of congenital defects in utero allows for both parental counseling and referral to a perinatal center where further investigation of the condition can be undertaken and monitoring of the high-risk pregnancy can be done. The perinatal center should advise when, where and how delivery will take place. Appropriate centers must have a skilled neonatal intensive care facility and pediatric surgical expertise.

## **Prenatal Diagnostic Studies and Tests**

### *Chorionic Villus Sampling (CVS)*

CVS allows biopsy of fetal cells for chromosomal, enzymatic or DNA analysis in the first trimester (9-12 weeks gestation). Cells are obtained by direct biopsy of chorion, either transcervically or transabdominally, preferably under ultrasound guidance. The major disadvantage of this procedure is the associated 3% increased rate of spontaneous abortion. CVS is the preferred prenatal diagnostic test for many high risk conditions (i.e., cystic fibrosis, sickle cell disease, Duchenne's dystrophy, etc.)

### *Alpha-Fetoprotein (AFP) Screening*

AFP is one of the major proteins in fetal serum. Screening should be offered to women at 16-18 weeks of gestation. AFP in maternal serum is of fetal origin. Increased

levels of AFP are found in fetuses with neural tube defects, anencephaly, Turner's syndrome, omphalocele, sacroccygeal teratoma, intestinal obstruction and missed abortion. Low AFP levels are observed in intrauterine growth retardation, Trisomy 18, Trisomy 21, and other conditions. However, a normal AFP level does not rule out trisomy. Women with a maternal age exceeding 35 years are at high risk for having babies with Down's Syndrome. Consequently, this group and indeed most pregnant women are now offered assay for both AFP and human chorionic gonadotropin (hCG). Human chorionic gonadotropin levels are frequently elevated in fetuses with Trisomy 21.

4

### *Amniocentesis*

Amniocentesis involves sampling and analysis of amniotic fluid to detect presence of metabolic disorders and chromosomal defects. Amniocentesis can be safely performed between 12-18 weeks gestation and usually takes 14 days to obtain results. The safety of this procedure is somewhat better than CVS. The risk of miscarriage following amniocentesis is less than 1%.

### *Fetoscopy and Fetal Sampling*

When appropriate, these procedures are performed between 15 and 21 weeks of gestation. Analysis of fetal blood can reveal many conditions including Wiskott-Aldrich syndrome, hemophilia A and B, hemoglobinopathies, alpha 1-antitrypsin deficiency, and chronic granulomatous disease. Conditions in which the genetic defect is not expressed in the amniotic fluid can be discovered by sampling from the skin and liver. Fibroblastic cell culture can be performed to reveal mosaicism. The risk of miscarriage is around 5%.

### *Percutaneous Umbilical Blood Sampling*

Percutaneous aspiration of umbilical cord blood can be safely performed under ultrasound guidance. The blood samples can reveal hematologic abnormalities including isoimmunization. This procedure is usually done between 18 and 20 weeks of gestation. The risk of miscarriage is about 2%. Results of analysis are usually available within 2-3 days.

### *Prenatal Ultrasound*

Sonography is the most important method of fetal screening. It is useful to determine gestational age of the fetus, single or multiple births, the amniotic fluid volume, growth in high risk pregnancies, and a significant number of fetal anomalies. Ultrasonography is the best noninvasive method for determining both functional and anatomic abnormalities in the fetus. Evaluation of amniotic fluid volume is most important. When performed in the 4th month of gestation, the finding of normal amounts of amniotic fluid suggests normal swallowing and renal function. A finding of reduced amniotic fluid volume, or no fluid at all, is a sign of impaired renal function, such as obstruction, multicystic kidneys or renal agenesis. Too much amniotic fluid (more than 2000 ml = polyhydramnios) suggests impaired fetal swallowing (neurologic abnormality, anencephali), proximal alimentary tract obstruction, or compression of the esophagus due to diaphragmatic hernia or congenital lung malformation.

Although a single ultrasound study can provide a wealth of information, serial studies over time can provide even more. Functional evaluation of kidney, heart, and lungs is considerably more accurate with repeated exams.

The heart and the great vessels are easily visualized with ultrasonography or fetal echocardiography. The dynamic function can be evaluated. The four chambers and the two great vessels should be visualized and allows the diagnosis of anomalies such as tetralogy of Fallot, tricuspid atresia, hypoplastic left heart, aortic valve stenosis/atresia and double outlet right ventricle.

Cerebral malformations, encephaloceles, and hydrocephalus are readily identified by prenatal ultrasound. Intraabdominal structures like hepatic neoplasms (hemangioma), neuroblastoma, enteric duplications and atresias of the gut can also be detected. The differentiation of omphalocele and gastroschisis is especially important because the prognosis in omphalocele is so much worse, compared to gastroschisis, because of the serious associated anomalies and chromosomal defects.

## Indications for Prenatal Diagnosis

### *General Risk Factors*

Maternal age more than 35 years (increased risk for fetal chromosomal abnormality).

Elevated or reduced serum AFP

Increased serum hCG.

### *Specific Risk Factors*

Previous still birth or neonatal death.

Previous child with a structural defect or chromosomal abnormality.

Structural abnormality in any of the parents.

Balanced translocation in any of the parents.

Inherited disorders (i.e., cystic fibrosis, metabolic disorders, sex-linked disorders)

Medical disease in the mother (i.e., diabetes mellitus)

Exposure to teratogens (i.e., ionizing radiation, anticonvulsant medicine, alcohol, etc.)

Infections (i.e., rubella, toxoplasmosis, cytomegalovirus)

### *Treatment of the Fetus*

Hydrops fetalis can occur secondary to isoimmunization induced hemolysis. Prenatal treatment of this condition may include erythrocyte transfusion in utero. Transplacental treatment can be administered for cardiac arrhythmias (especially supraventricular tachycardia) leading to hydrops. The most common prenatal treatment used for the fetus is steroid (i.e., glucocorticoid) administration to increase pulmonary surfactant in the lungs of the preterm infants.

### *Fetal Surgery*

The indication for fetal surgery is malformations that interfere with fetal organ development, which if alleviated would allow normal organogenesis. Pioneering work is now carried out in a few centers for highly selected cases; however, these procedures

involve significant risks for both the mother and the fetus (i.e., infection, premature labor, etc.).

Although no large series have proven any long term benefits, work continues (and should continue at a few centers with close supervision) on the use of fetal surgery for:

1. vesicoamniotic shunt for severe bilateral hydronephrosis with pulmonary hypoplasia
2. congenital diaphragmatic hernia with prenatal prosthetic patch repair or tracheal plugging
3. lobectomy for congenital cystic adenomatoid malformation
4. thoracoamniotic shunt for fetal chylothorax
5. ventriculoamniotic shunt for severe obstructive hydrocephalus
6. resection of sacrococcygeal teratoma to prevent cardiac failure secondary to arteriovenous fistula
7. correction of critical aortic stenosis to prevent severe left ventricular hypoplasia

### *Selected Readings*

1. Harrison R. The fetus as a patient. In: O'Neill Jr. JA, et al, ed. Pediatric Surgery, 5<sup>th</sup> Edition St. Louis: Mosby, 1998; 33-41.
2. Zackai EH, Robin NH. Clinical Genetics. In: O'Neill Jr. JA et al, eds. Pediatric Surgery, 5<sup>th</sup> Edition. St. Louis: Mosby, 1998; 19-31.
3. Caniano DA, Baylis F. Ethical considerations in prenatal surgical consultation. *Pediatr Surg Int* 1999; 15:303-9.
4. Milner R, Adzick NS. Perinatal management of fetal malformations amenable to surgical correction. *Curr Opin Obstetr Gyn* 1999; 11:177-83.

## **Section II: Perioperative Management and Critical Care**

## Vascular Access

*Marleta Reynolds*

### Blood Sampling

Current microtechniques of chemical analysis allow small samples of blood to be taken from children. Capillary tubes can be used for obtaining blood by “heel-stick”. If more blood is needed an antecubital or scalp vein can be used. An assistant will be needed to restrain the child. A 21 or 23 gauge scalp needle (butterfly) with preattached plastic tubing and a small syringe is used to penetrate the skin and enter the vein. Blood will flow immediately and can be aspirated gently by the assistant. Peripheral arterial blood can be sampled in a similar fashion.

Under extreme conditions an experienced physician may use a femoral vein for blood sampling. The child will need to be adequately restrained and the skin prepared with antibacterial solution. The femoral artery is palpated and a small scalp vein needle is inserted just medial to the femoral artery.

### Venous Access

Access for infusion therapy can be obtained by percutaneous insertion of steel needles or plastic catheters or by cutdown on peripheral veins. When placing a percutaneous catheter make a small nick in the skin at the insertion site with a separate needle to eliminate skin traction on the plastic catheter and avoid damage to the tip of the catheter. A local anesthetic can be injected to raise a skin wheal at the insertion site. If time allows a topical anesthetic cream can be applied. The needle and plastic catheter are inserted until blood returns. The catheter can then be advanced over the needle into the vein. The catheter is secured by a plastic dressing and tape to allow monitoring of the insertion site and catheter tip site. Phlebitis is the most common complication of peripheral intravenous catheters.

Cutdowns for peripheral venous access are being used less frequently. The cephalic vein at the wrist and the saphenous vein at the ankle are good sites because of their superficial and constant location. Meticulous care should be taken in restraining the extremity and maintaining sterile technique. A vertical incision over the vein provides for greater exposure and the incision can be extended proximally if more length of the vein is needed. A plastic catheter can be placed in the vein by making an oblique venotomy. If the vein is very small the catheter can be passed over a needle. The catheter is secured with absorbable suture and the wound is closed. A sterile dressing is placed and the extremity is immobilized. Peripheral arteries can be cannulated using a similar technique.

## Central Venous Access

Central venous access can be obtained by cutdown or percutaneous technique. "PIC" lines or "PCVCs" are small silastic catheters advanced into the central circulation via a peripheral vein. These central lines can be placed with or without ultrasound guidance. These lines cannot be maintained indefinitely but are ideal for several days and up to several weeks. Catheter related sepsis occurs in 2.7-6% of patients with these catheters. Venous thrombosis has been reported in 0.3%.

When short-term, multiple port or large bore access is needed, a percutaneous central line can be placed via the subclavian, external or internal jugular vein. For prolonged parenteral nutrition, blood samplings, or chemotherapy, a tunneled silastic catheter with or without a venous reservoir is preferred. The catheter can be placed with a percutaneous technique or by cutdown utilizing the subclavian, external jugular, internal jugular or saphenous veins. Fluoroscopy should be used during placement of any central line to confirm correct placement. If the subclavian vein has been accessed, a chest x-ray should be obtained to identify an associated pneumothorax or other thoracic complication.

## Umbilical Vessel Access

Central venous and arterial access can be obtained through the umbilical cord in a newborn. The distal cord is amputated after the area is prepped with an aseptic solution. The umbilical vein is large and thin-walled and a 5 French plastic catheter can be advanced through the ductus venosus into the right atrium. A 3.5 French soft plastic catheter can be advanced into either of the paired umbilical arteries and positioned in the thoracic or abdominal aorta. The catheter should be positioned above the diaphragm or below the level of the renal arteries. The position of either catheter must be verified by x-ray. Heparin is added to the infusate to prevent thrombosis. Because of the high associated complication rate both of these catheters should be removed as soon as possible.

## Intraosseous Access

In emergency situations intravenous access may not be easily or rapidly attainable in an infant or small child. The intraosseous route may be used for infusion of fluid, drugs and blood. Bone marrow needles, short (18-22 gauge) spinal needles or large (14-16 gauge) hypodermic needles can be used. The knee is supported and the tibia prepared with antimicrobial solution. The needle is placed in the midline of the anterior tibia on the flat surface 1-3 cm below the tibial tuberosity. The needle is directed inferiorly at a 60-90° angle and advanced until marrow content is aspirated. The fluid should flow freely into the intramedullary space. The needle is stabilized with a supported dressing to prevent dislodgement. Placement may be checked with a miniature C-arm imaging device.

It is contraindicated to use the intraosseous route in children with diseases of the bone or with ipsilateral extremity fractures. Needle dislodgement with subperiosteal or subcutaneous infiltration of fluid is the most common complication. Compartment syndrome and osteomyelitis have been reported. The infection rate is not higher using this technique. Fears over potential injury to the tibial growth plate have not been substantiated. It is generally advisable to remove an intraosseous needle as soon as possible.

*Selected Readings*

1. In: Simon RR, Brenner BE, eds. Emergency Procedures and Techniques, 3rd edition. Baltimore: Williams & Williams 1994; 418-419.
2. Guy J, Haley K, Zuspan SJ. Use of intraosseous infusion in the pediatric trauma patient. *J Pediatr Surg* 1993; 28(2):158-61.
3. Donaldson JS, Morello FP, Junewick JJ et al. Peripherally inserted central venous catheters: US guided vascular access in pediatric patients. *Radiology* 1995; 197(2):542-4.
4. Dubois J, Garel L, Tapiero B et al. Peripherally inserted central catheters in infants and children. *Radiology* 1997; 204(3):622-6.



# Fluids and Electrolytes

*John R. Wesley*

Paramount to successful treatment of infants and children with surgical disease is the establishment of fluid and electrolyte balance as expeditiously as possible, preferably preoperatively. Adequate vascular access must be established (see previous section) and careful attention given to keeping the infant or child warm, and reducing insensible losses. Special attention must be given to estimating and correcting pre-existing dehydration, and special note taken of the physiologic status of the patient.

Most neonates are born with 10% fluid excess secondary to high levels of antidiuretic hormone (ADH) that limit excretion of fluid during the first 24 hours of life. Overaggressive administration of fluid and electrolytes will interfere with normalization of the physiologic process. Fluid overload is linked with the development of patent ductus arteriosus, respiratory difficulty, and has been linked as a contributing factor to necrotizing enterocolitis.

Fluid loss is composed of sensible water (urine, feces, sweat) and insensible water loss (respiratory and transepidermal).

## Fluids

### *Insensible Water Loss*

Respiratory water loss increases with low humidity of inspired air and increases in minute ventilation (increased metabolic rate, fever, congestive heart failure, and respiratory distress syndrome).

### *Transepidermal Water Loss Is Affected by:*

- Skin keratin thickness (e.g., thin in VLBW, thick in postmature infant)
- Surface area/body mass
- Postnatal age
- Activity level
- Body temperature
- Postural changes
- Ambient humidity
- Ambient temperature
- Air currents (e.g., open bed)
- Phototherapy
- Radiant heat

### *Other Sources of Fluid Imbalance (Sensible Water Loss)*

- Third space (e.g., NEC burns)
- Diarrhea
- Diabetes insipidus
- SIADH
- Renal failure
- Congestive heart failure (e.g., from PDA)
- Hyperglycemia (osmotic diuresis)

### *Estimated Maintenance Fluid Requirements for Premature to Term Infants (ml/kg/d):*

Day	Premature		Term
	< 1250 g	> 1250 g	
1	100	75	60-75
2	100-120	75-100	75-85
3	120-up	100-up	100

Note: The above table is only an estimate of fluid requirements. Careful monitoring of fluid status is essential. Some VLBW infants require very large amounts (e.g., 250-300 ml/kg/d) of fluid. Patients under warmers or receiving phototherapy may require an additional 15-25 ml/kg/d.

### *Maintenance Fluid Requirements for Term Infants and Older Children*

Weight	Daily Fluid requirements
0-10 kg	100 cc/kg/day or 4 cc/kg/hr
10-20 kg	1000 cc + 50 cc/kg/day >10 kg or 40 cc + 2 cc/kg/hr >10 kg
> 20 kg	1500 cc + 20 cc/kg/day > 20 kg or 60 cc + 1 cc/kg/hr > 20 kg

### **Electrolytes**

#### *Maintenance Electrolytes for Premature Infants:*

##### **Sodium**

Maintenance: 2-4 mEq/kg/d for infants > 30 weeks gestation; 3-5 for infants < 30 weeks gestation

Generally not given in the first 24 hours

In VLBW infants and infants born with gastroschisis and omphalocele, check base line sodium (electrolytes) at birth

Bicarbonate is a sodium salt: 1 mEq  $\text{NaHCO}_3$  = 1 mEq Na

##### **Potassium**

Maintenance: 2 mEq/kg/d

Generally not in first 24 hours of age, or until infant has urinated

Decrease need with renal compromise or extensive tissue breakdown (e.g., NEC, burns)

Increase need with diuretics and certain drugs (e.g., Amphotericin B)

**Maintenance electrolytes for term infants and children up to 20 kg**

Component	Supplied As	Amount Required	Comments
Na	NaCl; Na acetate	2-4 mEq/kg/day	The acetate salt should be used in hyperchloremic patients. When used as a phosphate source, each millimole of Na phosphate provides approx. 1.3 mEq Na.
K	KCl; K phosphate K acetate	2-4 mEq/kg/day	Each millimole of K phosphate provides approximately 1.5 mEq potassium.
Ca	Ca Gluconate 10%	0.5-3.0 mEq/kg/day 10 mL (1 g) provides 4.8 mEq	Premature infants require more calcium than full-term infants or children. An initial dose of 1 mEq/kg/day should be adjusted on basis of serum calcium and PO <sub>4</sub> measurements. Precipitation factor should be calculated and should not exceed a factor of 3.
Calcium- Phosphate Precipitation Factor	$\frac{[(\text{Calcium mEq/kg}) + (\text{Phosphate mM/kg})] \times \text{Wt(kg)} \times 100}{\text{Total Infusion Volume per Bottle}} \leq 3$		Adjunct Calcium or Phosphate to maintain Precipitation Factor $\leq 3$ (per 100ml).
PO <sub>4</sub>	K phosphate Na Phosphate	0.5-1.5 mM/kg/day	Order only to provide maintenance phosphorus, the major anion of intracellular fluids, important in the formation of ATP, ADP, and creatine phosphate. Due to valence change with pH, PO <sub>4</sub> is ordered in millimoles rather than millequivalents. The normal serum level for term newborns is 3.5-8.6 mg/dL; for premature newborns during the first week only it is 5.4 to 10.9 mg/dL, and declines toward term newborns in 304 weeks.
Mg	MgSO <sub>4</sub>	0.5-1.0 mEq/kg/day	A major cation in the body acting as a catalyst for many intracellular enzymatic reactions.

Electrolyte ranges are for patients up to 10 kg. Heavier (and older) patients should be given electrolytes based on standard replacement solutions (0.5 NS or NS) supplemented according to serum electrolyte measurements.

## Dehydration

Add to maintenance fluids any losses from dehydration:

% Weight loss	H <sub>2</sub> O cc/kg	Na mEq/kg	Cl mEq/kg	K mEq/kg
5	50	4	3	3
10	100	8	6	6
15	150	12	9	9

For practical purposes, mild to moderate dehydration should be corrected with IV D<sub>5</sub>-1/2 NS + 20 mEq KCl/L; and severe dehydration should be corrected with Ringers Lactate or normal saline (NS) + 20 mEq/KCl/L.

On the first day after birth, maintenance fluids are usually started with D<sub>10</sub>W and blood sugar maintained between 60-80 mg/dL. More fluid is required for insensible and/or third space losses. On the second day after birth, sodium and potassium may be added in accordance with fluid status and electrolyte determination. On the third day after birth, IV fluids are gradually increased, dependent on clinical status.

Sodium and potassium may be required within the first day after birth if fluid losses after surgery are high. Sodium should not be added to the IV fluid until serum sodium is < 135 mg%, and there is no evidence of edema or other overhydration. The acetate form of sodium and potassium are given to small for gestational age (SGA) neonates. Usually sodium and potassium chloride can be given to surgical patients if the base excess is > 0 and urine pH is greater than 7.

If the patient is unable to take oral nutrition by the third day of age, parenteral nutrition should be started at that time, once fluid and electrolyte balance has been attained.

### *Selected Readings*

1. Wesley JR, Khalidi N, Faubion WC et al. The University of Michigan Medical Center Parenteral and Enteral Nutrition Manual, Sixth Edition. North Chicago: Abbott Laboratories, 1990.
2. Nelson WE, Behrman RE, Kliegman RM et al. Fluid and Electrolyte Therapy. In: Joe Editor et al eds. Textbook of Pediatrics. Philadelphia: WB Saunders Co. 1996; 206-222.
3. Bell EF, Oh W. Fluid and electrolyte balance in very low birth weight infants. Clin Perinatol 1979; 6:139-150.
4. Rowe MI. Fluid and electrolyte management. In: Welch KJ et al, ed. Pediatric Surgery, 4<sup>th</sup> Edition. Chicago : Year Book Medical Publishers 1986; 22-27.

# Nutrition and Metabolism

*John R. Wesley*

## Introduction

Several considerations make parenteral nutrition in the premature neonate, the infant, and young child, significantly different from that in the adult. These include smaller body size, rapid growth, highly variable fluid requirements, and in newborn infants, the immaturity of certain organ systems, especially the liver, kidney, lung, and gastrointestinal tract. Infants and children have markedly decreased energy stores when compared with the adult, and are much more rapidly affected by inability to eat, and nothing by mouth (NPO) orders that frequently accompany the onset of severe illness and subsequent diagnostic studies. An infant or child stressed by major infection, severe trauma, or major surgery is frequently unable to tolerate enteral nutrition. Inadequate nutritional support may result in weakening of respiratory muscles, depression of central nervous system function, apnea, increased difficulty in weaning from mechanical ventilation, and increased susceptibility to infection. The disordered nutrient metabolism encountered during severe systemic stress results in altered nutrient requirements. A traumatized or septic patient has significantly increased fluid and electrolyte requirements, as well as increased energy needs. Other important nutrients in relatively short supply, such as water-soluble vitamins and some fat-soluble vitamins, are used at a more rapid rate, and if unrecognized and unreplaced, become rate-limiting factors without which recovery and wound healing cannot proceed. Minor metabolic stress can be met and overcome with relative ease; but with children, especially neonates, there is never much margin for error. Major stress demands a much more sophisticated understanding of host response, altered organ physiology, and a detailed finely tuned plan for effective intervention.

Because so many medical and surgical problems are made worse by malnutrition, parenteral nutrition should be initiated as early as possible once a physician determines that an infant or small child is malnourished, or unlikely to tolerate enteral nutrition within a 3-5 day period. Most normal newborns establish positive nitrogen balance with weight stabilization or weight gain by the second to fourth postpartum day. In infants unable to take adequate enteral nutrition, sufficient nutrients can be provided with peripheral parenteral nutrition by infusing glucose-amino acid solutions concomitantly with fat emulsion. Central venous access may be more appropriate in infants who require fluid restriction, or in infants with limited peripheral vein access and with a need for prolonged parenteral nutrition.

Every infant receiving parenteral nutrition (PN) goes through a period of physiologic adjustment which can be divided into two stages. The first stage is a time of increasing tolerance to the PN solution as reflected by the serum and urine glucose levels. During this time the glucose and lipid dose should be gradually increased until a sufficient number of calories are provided or until other factors, such as the volume of fluid tolerated, limit further increases. The time required for this initial adjustment phase is extremely variable. Immature infants, or those with severe stress due to infection or respiratory insufficiency, will require a longer period for stabilization than the more mature infant. The second stage marks the beginning of the period during which the infant is receiving an adequate number of calories for weight gain and electrolyte balance is stable. Optimal weight gain for newborns during this phase should be 15-25 grams per day, or 1-2% of total body weight in kg/day in older patients. Weight gain greater than this may reflect excess fluid administration and fluid retention. Inadequate weight gain may reflect an underlying metabolic insult, such as sepsis. During both phases, it is very important to keep accurate intake and output records, and obtain daily weights at the same time and with the same scale each day. Urine output should run 1 mL/kg/hour or more, with urine specific gravity between 1.005 and 1.015 in the absence of glucosuria.

PN solution is ordered for 24 hour periods, at a specified hourly flow rate. The patient's daily weight must be provided so that the pharmacist can check the appropriateness of the orders for the components being compounded. Volume, amino acids, lipid emulsion, and all electrolytes should be ordered per kilogram. (Chapter 6, Fluid and Electrolytes) Dextrose, amino acid, and fat emulsion calories along with the nonprotein calories-to-gram nitrogen ratio should be calculated to ensure the appropriate balance of PN components. This ratio should always be in the range of 150-300 nonprotein calories per gram of nitrogen.

The following tables summarize the essential components of a complete set of PN orders (Tables 7.1 and 7.2).

### **Administering Parenteral Nutrition Solutions**

Infants should be started on half-strength solutions (4-8 mg/kg/min of dextrose) and advanced to 3/4 and full-strength (10-14 mg/kg/min maximum) over the ensuing 24-48 hours, with rates adjusted according to urine and blood glucose determinations. Total volume can then be increased as tolerated to further increase caloric intake. Because of the high rate of phlebitis with hyperosmolar solutions, peripheral PN concentration should not exceed 12.5% dextrose and 2.5% amino acids.

In low birth weight and critically ill infants, umbilical artery (UA) and vein (UVC) catheters are usually present. Central strength formulations (greater than 10%) can be infused through a UVC once placement of the catheter tip above the diaphragm is confirmed. Concentrations of dextrose administered through a UAC should usually be limited to a maximum of 12.5%.

It is safe to begin fat emulsion at a rate of 0.5-1 g/kg/day on the first day of TPN. Lipids can be advanced at a rate of 0.5 g/kg/day to a maximum of 3 g/kg/day in premature infants, and 4 g/kg/day in full term infants.

Central PN solutions may be administered alone, or as a 3-in-1 solution with intravenous fat. Peripheral formulations are generally given concomitantly with intravenous fat to reduce the osmolarity of the final solution and to keep the total

**Table 7.1. Pediatric PN: Macronutrients**

Component	Supplied As	Amount Required	Comments
Fluid	Combination of items below	60-150 mL/kg/day	See Chapter on fluid and electrolytes. Monitor intake and output. Aim for urine output of 1-2 mL/kg/hr with urine Sp Gr. 1.005-1.015.
Calories	Protein 4.0 kcal/g CHO 3.4 kcal/g Fat 9.0 kcal/g (IV Fat emulsion 10% = 1kcal/mL; 20% = 2 kcal/mL.	45-120 kcal/kg/day	Maintenance and Normal Growth: Age (yrs):                      Kcal/kg: 0-1*                              90-120 12-18                             75-90 12-19                             60-75 12-20                             45-60 Calorie requirement increased by one or more of the following: 12% increase for each degree of fever above 37°C. 20-30% increase with major surgery. 40-50% increase with severe sepsis. 50-100% increase with long-term growth failure. *Premature infants should start at 80 kcal/kg and increase as needed for appropriate weight gain.
Protein	Amino Acid solution 5% 7%	To provide essential and nonessential amino acids 1.7-2.5 protein g/kg/day	In neonates, protein should be initiated at 1 g/kg and advanced to a maximum of 2.5 g/kg/d. For every gram of nitrogen given, 150-300 nonprotein calories should be provided as carbohydrate or fat to maintain positive nitrogen balance. 1 g protein = 0.16 g nitrogen.
Carbohydrate	D5, D10, D25, D50	To provide necessary calories Rate: 0.4-1.5 g/kg/hr.	Use D10 + A2.0 for peripheral PN (0.4 kcal/mL) Nonprotein-calorie/gN ratio 85:1. Add fat emulsion for additional nonprotein calories. D25 + A3.5 for Central PN (1.0 kcal/mL) Nonprotein-calorie/gN ratio 155:1. In neonates up to D12.5 can be administered in peripheral lines and through umbilical artery catheters. D25 can be infused through umbilical venous catheters if proper line placement in the right atrium is confirmed.

volume within manageable limits. Ideally, the daily intravenous calorie budget should approximate normal calorie distribution in a balanced enteral pediatric diet: 45% carbohydrate, 40% fat and 15% protein. In actual practice, only enough fat need be given to prevent essential fatty acid deficiency. Most importantly, the sum of the

**Table 7.2. Pediatric PN: Micronutrients**

Component	Supplied As	Amount Required	Comments
Vit B12	Cyanocobalamin	1 mcg is provided in the Pediatric Multivitamin Solution	Important coenzyme function related to growth, red and white blood cell maturation. Included in multivitamin solution.
Folic Acid		140 mcg is provided in the Pediatric Multivitamin Solution	Important factor in cellular growth, especially in the maturation of red and white blood cells. Included in multivitamin solution.
Multivitamins	Pediatric Multivitamin Solution (Astra)	2-3 mL/day*	Each 3 mL vial contains: Vitamin A – 2300 IU Vitamin D – 400 IU Ascorbic Acid – 80 mg Thiamine (B1) – 1.2 mg Riboflavin (B2) – 1.4 mg Niacinamide – 17 IU Pyridoxine – 1 mg Pantothenic Acid – 5 mg Vitamin E – 7 IU Folic Acid – 140 mcg Cyanocobalamin (B12) – 1 mcg Phytonadione (k1) – 200 mcg Biotin – 20 mcg *Neonates and infants under 1.75 kg: 2 mL/day Infants and children 1.75-30 kg: 3 mL/day
Iron	RBCs or Imferon®	2 mg/day	Start at 5 weeks of age. Higher requirement with unreplaced blood loss or chronic iron deficiency. A test dose of Imferon is necessary before instituting therapy.
Phytonadione (Vit K1)	AquaMephyton®	200 mcg are provided in the Pediatric Multivitamins	Important in the production of certain coagulation factors (prothrombin, VII, IX, X). Deficiency and hemorrhagic diathesis may develop rapidly in neonates who are not being fed enterally. Included in multivitamin solution.

*continued on next page*



Trace elements Less than 10 kg		Each 0.3 mL of trace elements mixture contains:
Zn	300.0 mcg/kg/day	300.0 mcg Zn
Cu	20.0 mcg/kg/day	20.0 mcg Cu
Mn	10.0 mcg/kg/day	10.0 mcg Mn
Cr	0.2 mcg/kg/day	0.2 mcg Cr
Se	0.8 mcg/kg/day	0.8 mcg Se
		Each patient (1-9 kg) should receive 0.3 mL/kg/day of the mixture.
Trace elements 10-30 kg		Each 0.1 mL of trace elements mixture contains:
Zn	100.0 mcg/kg/day	100.0 mcg Zn
Cu	20.0 mcg/kg/day	20.0 mcg Cu
Mn	10.0 mcg/kg/day	10.1 mcg Mn
Cr	0.2 mcg/kg/day	0.2 mcg Cr
Se	.8 mcg/kg/day	0.8 mcg Se
		Each patient (10-30 kg) should receive 0.1 mL/kg/day of the mixture. In patients with weight greater than 30 kg, use adult trace element solution, 1 mL/day.
Heparin	1 IU/mL	Helps prevent platelet thrombi and clots from forming at the catheter tip. Heparin may be deleted from the TPN of neonates and children on ECMO therapy.

nonprotein calories should be sufficient to provide a total nonprotein-calorie-to-gram-nitrogen ratio in the range of 150:1 to 300:1. This range is necessary to achieve the optimal utilization and protein-sparing effect of the administered PN solution. Excessive or unbalanced protein intake has been associated with metabolic acidosis in small premature infants.

Tables 7.1 and 7.2 are designed to provide a guide for parenteral nutrition in newborn infants and small children. The nutritional requirements for children over age 3 years and teenagers will not be dealt with separately except to reiterate their increased caloric requirements due to rapid growth and development. In addition, each pediatric unit or service may have guidelines for specific application of PN for problems unique to their patients.

## Monitoring

Infants on PN must be carefully monitored. In addition to accurate daily intake, output, weight, and weekly length and head circumference, judicious use of blood tests is very important in infants and children due to their small total blood volume. Table 7.3 outlines recommended tests and frequency of monitoring. Careful attention to the values will alert the physician to potential metabolic complications and ensure optimal benefit from PN therapy.

**Table 7.3. Blood values monitored routinely during parenteral nutrition**

<b>At start of therapy and biweekly*</b>	<b>Frequency of monitoring At start of therapy and weekly</b>	<b>As indicated</b>
Na, K, Cl	SGOT, LDH, alkaline phosphatase	Copper
Creatinine		
Urea	Bilirubin direct/total	Zinc
Glucose	Triglycerides	Iron
Hgb, Hct, WBC, platelets	Magnesium	Ammonia
	Albumin or Prealbumin	Osmolarity
	Calcium, phosphorus	pH

\*Serum levels should be monitored more frequently in the premature infant.

## Complications

### *Technical Complications*

The incidence of technical complications due to placement and position of central lines in infants and children has been greatly reduced in recent years by careful attention to aseptic technique and x-ray conformation after catheter insertion. The introduction of nonreactive silicone catheters in place of polyvinylchloride catheters has reduced the incidence of foreign body reaction and subclavian vein or vena cava thrombosis. The incidence of cardiac arrhythmias due to irritation from the catheter has been greatly reduced by placing the tip of the catheter at the junction of the superior vena cava and the right atrium rather than in the heart. Suturing the catheter to the skin at the catheter-cutaneous junction and checking to be sure that the catheter is secure at each 72 hour dressing change has greatly reduced the frequency of catheter dislocation. The complications arising from administration of PN through an umbilical artery catheter (UAC) in neonates are associated with the UAC placement, e.g., vasospasm, thrombosis, embolization, hypertension, hemorrhage, and necrotizing enterocolitis.

Almost all of the technical complications inherent in central PN can be avoided by use of peripheral PN administration. Phlebitis and superficial skin slough are the most common complications in patients receiving peripheral PN. The incidence of phlebitis is reduced in patients receiving concomitant intravenous fat emulsion. Simultaneous infusion of fat reduces the osmolarity and increases the pH of the PN solution, and although still slightly hypertonic, the fat emulsion appears to protect the vein from phlebitis. If an infiltrated IV site is identified quickly, it is usually benign, and the extravasated fluid is rapidly reabsorbed. This process is enhanced by warm moist dressings to the area and silver sulfadiazine dressings in those few cases where skin slough occurs. Very rarely a skin slough site will require skin grafting.

### *Metabolic Complications*

Almost every conceivable metabolic complication has been reported during total parenteral nutrition. Table 7.4 lists the more common metabolic complications, and although serious consequences may ensue if metabolic complications go

**Table 7.4. Potential metabolic complications from PN**

- 1. Electrolyte Imbalance**
  - a. Hyper/hyponatremia
  - b. Hyper/hypokalemia
  - c. Hyper/hypochloremia
  - d. Hyper/hypocalcemia
  - e. Hyper/hypomagnesemia
  - f. Hyper/hypophosphatemia
- 2. Carbohydrate Administration**
  - a. Hyper/hypoglycemia
  - b. Hyperosmolarity and associated osmotic diuresis with dehydration, leading to nonketotic hyperglycemic coma.
- 3. Protein Administration**
  - a. Cholestatic jaundice
  - b. Azotemia
- 4. Lipid Administration**
  - a. Hyperlipidemia
  - b. Alteration of pulmonary function
  - c. Displacement of albumin-bound bilirubin by plasma free fatty acid
  - d. "Overloading syndrome" – characterized by hyperlipidemia, fever, lethargy, liver damage, and coagulation disorders. This has been reported in adults but has been recognized rarely in children.
- 5. Trace Element Deficiencies**
  - a. Zinc deficiency
  - b. Copper deficiency
  - c. Chromium deficiency
- 6. Essential Fatty Acid Deficiency (EFAD)**

EFAD occurs if lipid emulsions are not used; the major clinical manifestation is a desquamating skin rash.

undetected for any length of time, careful clinical monitoring and appropriate adjustment of the PN solution results in most patients tolerating parenteral nutrition infusion quite well.

### *Infectious Complications*

Sepsis continues to be the major complication of centrally infused parenteral nutrition in infants and children, and the protocol for work-up of possible catheter sepsis is the same as that for the adult. Placement of catheters under strict aseptic conditions and meticulous care of the catheter site with 72-hour standardized dressing changes greatly reduces the incidence of septic complications. In addition, strict avoidance of the use of the PN catheter for blood drawing, administration of medication, or blood products, minimizes the risks of contamination and mechanical failure.

Peripheral PN administration has the advantage of eliminating most of the septic and technical complications inherent with central catheters. However, the avoidance of frequent infiltration and local infection or skin slough that may accompany peripheral IV infusion is dependent on the same careful attention to sterile technique of insertion and occlusive dressings that are important in central line management.

## Pediatric Nutritional Assessment

Nutritional assessment of the pediatric patient differs from that of the adult. The pediatric patient, especially the infant, does not have the reserves of an adult and must be provided additional calories for growth. Thus, nutritional inadequacies are seen more quickly and can be more devastating in the pediatric age group. In addition to standard biochemical parameters, such as albumin and total protein, body weight should be obtained daily, and height/length and head circumference should be measured at least weekly on all patients where adequate nutrient intake is questioned.

Whenever possible, enteral nutrition should be employed to support the pediatric patient, and supplemented with PN to ensure adequate calories. Even a small amount of enteral nutrition will reduce or prevent septic complications stemming from bacterial translocation and breakdown of normal host mucosal barriers to bacteria, fungi, and endotoxin.

## Transition from Parenteral to Enteral Nutrition

One of the most important, and frequently overlooked, phases of the pediatric patient's recovery from a severe medical or surgical illness is the transition period from parenteral to enteral nutrition. Successful reintroduction of enteral nutrition requires an understanding of how parenteral nutrition affects the functional capacities of the gastrointestinal tract and the limitations of the child's immature physiology. To manage a plan for successful transition of the pediatric patient from parenteral to enteral support, the clinician must select an appropriate formula, design a feeding regimen, and taper the parenteral support appropriately. The selection of a formula is based on the child's age, clinical pathology, and the caloric density, osmolarity, protein content, carbohydrate and fat source, and the nutrient complexity of the formula. The transition feeding regimen is designed to allow for adaptive increases in digestive enzymes and surface area within the gut. Small advances in the volume of enteral feedings are made first; increases in concentration of the formula follow later. A systematic method for the progression of enteric support and the tapering of parenteral nutrition is preferred.

### *Selected Readings*

1. In: Suskind RM ed. Textbook of Pediatric Nutrition, Second edition. New York: Raven Press 1993.
2. Wesley JR, Khalidi N, Faubion WC et al. The University of Michigan Medical Center Parenteral and Enteral Nutrition Manual, Sixth Edition. North Chicago: Abbott Laboratories, 1990: 54-69.
3. Wesley JR. Nutrient metabolism in relation to the systemic stress response. In: Fuhrman BP, Zimmerman JJ eds. Pediatric Critical Care, 2<sup>nd</sup> edition. St. Louis: C.V. Mosby 1998; 799-819.
4. Bachman AL, Klish WJ. Handbook of Nutritional Support. Baltimore, William & Wilkins 1997: 73-91.
5. Han-Markey T, Wesley JR. Pediatric critical care. In: ASPEN, eds. Silver Springs, MD: The ASPEN Nutrition Support Practice Manual 1998; 34:1-10.
6. Braunschweig CL, Wesley JR, Clark SF et al. Rationale and guidelines for transitional feeding in the 3-30 kg child. J Amer Diet Assoc 1988; 88:479-482.

## Respiratory Failure and Support in Children

*Marybeth Madonna*

Respiratory failure in children can occur for a variety of reasons. In neonates, the usual final common pathway is persistent pulmonary hypertension (PPH) and persistent fetal circulation. Infants are born with shunts in place between the systemic and pulmonary circulation, namely the patent ductus arteriosus and the patent foramen ovale. In conditions with increased pulmonary vascular resistance and pulmonary hypertension, these shunts allow blood to bypass the lungs and return to the body prior to oxygenation. Many conditions predispose to this final pathophysiology. In the preterm infant the most common is respiratory distress syndrome (RDS) that is due to immaturity of the lungs which have deficient surfactant production. In term infants, respiratory failure occurs due to pneumonia, sepsis, or aspiration, most commonly of meconium but also of blood or amniotic fluid. In addition, those babies born with congenital abnormalities of the heart or lungs such as congenital diaphragmatic hernia, lobar emphysema, or anomalies of venous return may have respiratory distress secondary to PPH.

In children, the common end physiology of respiratory failure is acute respiratory distress syndrome (ARDS). In this condition, inflammatory mediators are released after a stress. These mediators make the respiratory epithelium leaky and thick, this decreases gas exchange. Again, a variety of conditions predispose to this final pathway. Most common is pneumonia or pneumonitis caused by respiratory syncytial virus (RSV) infection. Patients can also have a variety of other viral and bacterial pneumonias. In addition, sepsis, stress, massive transfusions, near drowning and inhalation injuries all predispose to ARDS.

Treatment of the neonate or child with respiratory failure is similar to treatment of adults, namely providing adequate oxygenation and ventilatory support. However, there are some distinct differences. The airways of the child are smaller than those of adults and therefore, airway conductance is less. The anterior-posterior diameter of the glottis in infants and small children is less than one third that of adults. In children the narrowest part of the airway is the subglottis, unlike adults where it is the glottis. Due to these conditions, uncuffed endotracheal tubes are used in infants and smaller children. When these tubes are used, there is a leak of ventilatory pressures. The respiratory rate in children is much faster than in adults, and children tend to increase respiratory rate rather than tidal volume in times of stress.

Additionally, the inspiratory time is much shorter (as low as 0.4-0.5 seconds). Children have lower tidal volumes than adults (despite a similar ratio of tidal volume to body weight), with neonates having tidal volumes as low as 20 ml. All of these differences must be considered when managing respiratory failure in children.

The characteristics of ventilator support must be understood. Historically, infants and small children were treated with pressure control ventilation with a nonsynchronized respiratory rate because the ventilators did not have a high enough sensitivity to measure the small inspiratory effort of children. With the computer era, this has changed. The variety of conventional ventilatory support available for children today is great.

The components of the support are similar to those in adults. Volume cycled (volume control) ventilation delivers a set tidal volume to the patient with each breath, regardless of the pressure required to achieve that volume. In pressure cycled ventilation (pressure control) the breath is terminated when a set peak pressure is reached regardless of the volume delivered. With time-cycled ventilation, mandatory inspiration ends when a preset time has passed regardless of airway pressure or volume delivered. Today, a combination of these modes can be used with the more sophisticated ventilators available. This allows volume control, pressure limited ventilation during which a set tidal volume is delivered to the patient as long as a preset pressure is not exceeded. In the various modes of ventilation, the percentage of inspired oxygen and respiratory rate is set. In addition, the positive end expiratory pressure (PEEP) is set.

In comparison to tidal volume, there is a large dead space in the ventilator circuit of children. Consequently, assistance of spontaneous respiratory effort is required. Synchronized mandatory ventilation delivers a set number of breaths but the mandatory breaths are synchronized with the patient's own respiratory efforts so only a portion of the breaths are assisted by the ventilator (the preset rate). Another aid to spontaneous respiration is pressure support ventilation. The spontaneous inspiration is sensed in this mode and a variable flow of gas is delivered until the airway pressure reaches a preset pressure. This pressure is then actively sustained during the patient's inspiration. Thus, the work of inspiration is much less.

The child's disease condition and the physician's familiarity with the equipment determine which of the above ventilatory modes is used. No matter what mode is used, the physician tries to minimize the pulmonary damage caused by the ventilator. Ventilator induced lung injury is a significant complication of respiratory support in children. One of the important components of the support that needs limitation is the fraction of inspired oxygen. Oxygen toxicity is a real problem. Increased oxygen content in airways causes increased free radical formation that in turn causes damage to respiratory epithelium. In addition, premature infants can suffer other long-term sequelae from high oxygen content, most importantly retinopathy of prematurity (ROP).

In most pulmonary disease states, a child loses functional residual capacity (FRC) of the lung due to alveolar collapse. Higher ventilatory pressures are required to overcome this problem. The higher peak airway (inspiratory) pressures (PIP) subsequently causes damage to the lungs themselves (barotrauma), setting up a vicious cycle. Recently, it has been shown that the volume of the breath ("volutrauma") is also implicated in lung damage. Since it is now believed that the opening and closing

of the alveoli is the main problem causing airway damage, the pressure and volume of breaths are important. Pressure and volume are limited whenever possible. To achieve this, the physician may allow permissive hypercapnea (i.e., accept  $\text{PaCO}_2$  of 60-80 as long as the pH is over 7.2). This method of respiratory support decreases mortality in both infants and children with respiratory failure due to a variety of conditions.

To prevent lung damage from alveolar recoil, adequate pressures are needed to prevent the alveoli from collapsing. To achieve this, a higher level of positive end-expiratory pressure (PEEP) is used. The use of PEEP increases functional residual capacity (FRC) and also increases ventilation perfusion matching, thereby increasing oxygenation. Higher PEEP also decreases alveolar edema.

To assist ventilation/perfusion matching, prone positioning is sometimes used. The benefit from prone positioning is thought to result from blood flow redistribution to the dependant areas of the lung (anterior in prone positioning) or more homogenous distribution of ventilation.

### **Novel Approaches for Respiratory Support in Children**

Inverse ratio ventilation is occasionally used in an attempt to enhance alveolar distension and reduce hypoxemia and pulmonary shunting. In this type of ventilation, more time is spent in inspiration than expiration (usually 2:1). There is a risk of incomplete expiration, which can cause auto PEEP, a condition in which the true PEEP is much higher than that set on the ventilator.

High frequency ventilation delivers respiratory support at high rates with tidal volumes near anatomic dead space. This is very similar to the panting of dogs. Jet ventilation provides small bursts of gas through a jet port in the endotracheal tube at a rate of 240-600 breaths per minute (BPM). In oscillatory ventilation, a piston pump drives a diaphragm that delivers small volumes at frequencies of 180-900 BPM. When using high frequency ventilation, oxygenation is manipulated by changing the mean airway pressure (MAP) delivered and the  $\text{FiO}_2$ . The ventilation is provided by the change in pressure around the MAP (also called DP). In high frequency ventilation, axial streams are developed in the airways with a prograde central core and streaming in the opposite direction at the periphery thereby transporting particles rapidly to the terminal airways. The goal of high frequency ventilation is to apply a MAP that recruits alveoli and maintains oxygenation while limiting the amplitude (DP) to provide adequate chest wall movement and  $\text{CO}_2$  elimination.

Intratracheal pulmonary ventilation (ITPV) uses an infusion of fresh gas into the trachea via a cannula placed at the tip of the endotracheal tube. This gas flow replaces central airway dead space with fresh gas during the expiratory phase of ventilation and functions to reduce dead space, thereby increasing  $\text{CO}_2$  elimination. Experience with this mode of ventilation in children with respiratory failure is limited.

Surfactant is a phospholipid that is produced in the lungs by the Type II pneumatocytes. It functions to reduce surface tension in the lungs, thereby increasing compliance and FRC. It is most effective when administered with its associated proteins. This agent has significantly reduced the mortality of premature infants due to respiratory distress syndrome (RDS) because these infants are naturally defi-

cient in surfactant. It has also improved outcomes in full term infants and children with respiratory failure complicated by a relative surfactant deficiency.

Liquid ventilation is a mode of ventilation in which gas exchange is achieved in the lungs through a liquid medium. The liquid must have a low surface tension and high solubility to oxygen and carbon dioxide and must be nontoxic. A present, the perfluorocarbons are the only commercially available liquid ventilation medium and are only used experimentally. Either total liquid ventilation, requiring a special ventilator or partial liquid ventilation where the lungs are filled to FRC with the liquid and then conventional ventilation is used can be attempted. Phase I trials have shown improved oxygenation and pulmonary mechanics in adults treated with this mode of ventilation.

Nitric oxide is an endogenously produced substance that induces vascular smooth muscle relaxation. It is generated by nitric oxide synthase (NOS) through oxidation of L-arginine to citrulline. It stimulates guanylate cyclase to produce increased cGMP that reduces intracellular calcium causing relaxation of vascular smooth muscle. Nitric oxide, when administered as a gas, is a potent selective pulmonary vasodilator. This agent has proven very useful in neonates with pulmonary hypertension. It may also benefit older children perhaps through improved ventilation/perfusion matching.

8 Extracorporeal membrane oxygenation (ECMO) has been used in neonates since 1975. In this form of therapy, a membrane oxygenator provides oxygenation and ventilation. The membrane is made of silicone which is very permeable to oxygen and carbon dioxide but impermeable to blood and nearly impermeable to water. Access is obtained through a venotomy or arteriotomy in the infant or child. The blood is then pumped to the oxygenator and then back to the patient. Most commonly the neck vessels are used for access.

There are two forms of therapy. Venovenous ECMO uses only the jugular vein and relies on a double lumen catheter to both remove and return blood to the patient. This provides only support of oxygenation and ventilation but relies on the patient's cardiac output to deliver the oxygenated blood. In venoarterial ECMO, the jugular vein and carotid artery are cannulated and both cardiac and respiratory support are provided because the patient's heart is partially bypassed. ECMO is a highly effective form of therapy with survival rates of over 90% for some diagnoses (such as meconium aspiration syndrome) treated. However, it is a very invasive therapy with significant risks, mostly due to bleeding from the anticoagulation therapy required. Therefore, it is used with caution and only in centers with knowledge and experience with this therapy.

### *Selected Readings*

1. Arensman RM, Statter MB, Bastawrous AL et al. Modern treatment modalities for neonatal and pediatric respiratory failure. *Am J Surg* 1996; 172:41-47.
2. Hirschl RB. Respiratory failure: Current status of experimental therapies. *Sem Pediatr Surg* 1999; 8:155-170.
3. Shanley CJ, Hirschl RB, Schumaker RE et al. Extracorporeal life support for neonatal and respiratory failure: a 20 year experience. *Ann Surg* 1994; 220:269-282.



# Hypovolemic Shock and Resuscitation

*Matthew L. Moront*

## Definition

Shock can be defined in a variety of ways. In general, shock exists when there is evidence of multisystem organ hypoperfusion. This evidence is gathered during the initial clinical assessment and supported by laboratory tests and monitoring systemic acid-base balance. On a cellular level shock is characterized as an imbalance between oxygen delivery and oxygen consumption. This imbalance leads to a failure of tissue perfusion to meet metabolic demands of the cell and results in anaerobic metabolism, metabolic acidosis, the release of inflammatory mediators, and eventually multisystem organ failure. Implicit in this definition is that inadequate perfusion can be caused by decreased oxygen supply, increased oxygen demand, or a combination of both of these factors.

Children manifest a shock state differently than adults. Perhaps the most striking difference between adults and children is the degree to which cardiac output can fall without exhibiting systemic hypotension. The intrinsic compensatory mechanisms of children allow a loss of 40-45% of the intravascular volume before systemic blood pressure can no longer be maintained. At the point where compensatory mechanisms are no longer able to maintain blood pressure, children often decompensate with a precipitous drop in blood pressure.

## Clinical Indicators of Inadequate Tissue Perfusion

### *Tachycardia*

Tachycardia is one of the earliest signs of shock but is not specific. An increased heart rate is also caused by other factors such as fear, anxiety and pain. The response of the heart rate to a fluid challenge provides insight as to ongoing fluid losses or the degree of volume deficit.

### *Altered Mental Status*

Mental status changes are observed when cerebral perfusion is compromised as a result of hypovolemia. Unfortunately, children with head injuries present in a similar fashion. An example of altered mental status is a child who exhibits a minimal response to blood draws or placement of an intravenous catheter. Another example is a child who initially appears combative or somnolent after losing blood from a femur fracture or deep laceration and undergoes a significant improvement in mental status after 20-40 cc/kg fluid challenge.

### *Decreased Diastolic Pressure*

The diastolic pressure should normally be two thirds of the systolic pressure. A decrease in diastolic pressure of 20 mm Hg or greater indicates significant intravascular volume loss. This finding can be subtle and is also one of the early indicators of inadequate tissue perfusion.

### *Mottled Cool Extremities*

One of the body's compensatory mechanisms to counter the effects of hypovolemia is to shunt blood away from the less critical areas in the periphery to the essential internal organs. The result is a mottled appearance of the skin beginning in the extremities and, in severe shock states, extending onto the torso. Peripheral perfusion is frequently measured by evaluating capillary refill at the nail bed, which is normally less than 2 seconds. Children in shock frequently have measurable delays in capillary refill. A more subjective measure of the central shunting of blood is in the assessment of the quality of peripheral versus central arterial pulses. Children in shock frequently exhibit thready distal pulses when compared to a femoral or carotid arterial pulse. In severe shock states distal pulses may not be palpable. The distal pulses will return after appropriate fluid resuscitation and the peripheral pulses will subjectively feel as strong as the central pulsations.

### *Decreased Systolic Blood Pressure*

In children with hypovolemic shock, decreased systolic blood pressure is a late finding and indicates severe intravascular volume loss of over 40% of circulating blood volume with vascular decompensation. A normal systolic blood pressure is approximately 80 mm Hg plus two times the age in years. For example, a child who is 4 years old should have a systolic blood pressure of  $80 + (4 \text{ years} \times 2) = 88$  mm Hg. A decreased systolic blood pressure indicates all of the body's intrinsic compensatory mechanisms are unable to maintain adequate perfusion to the vital organs. This situation is referred to as uncompensated shock and requires immediate attention to prevent cardiorespiratory arrest and death.

### *Urine Output*

A decrease in urine output represents diminished organ perfusion and is a finding in children with intravascular volume loss which usually indicates a deficit of between 25-40% of blood volume. Accurate hourly assessment of urine output requires a bladder catheter. Another frequently used urine measurement is the specific gravity. Children with a high specific gravity (1.010-1.030) have concentrated urine which is suggestive of a volume deficit. It must be emphasized that both of these indicators are late findings and should only confirm the other signs of inadequate tissue perfusion and volume deficit.

## **Treatment of Shock**

### *Priorities*

Establishing a secure airway with protection of the cervical spine occupy the highest priority in the primary survey. Ensuring adequate ventilation and oxygenation are also essential initial steps prior to assessing for signs of inadequate tissue

perfusion. Once these tasks are accomplished, attention is directed at evaluation of shock and restoration of adequate circulating volume.

### *Intravenous Access*

The placement of sufficient intravenous access is a considerable challenge in a seriously ill infant or young child. A systematic stepwise approach is essential in accomplishing this difficult task.

Two large bore catheters placed above and below the diaphragm are optimal. No more than 90 seconds or two attempts should be made at peripheral intravenous (IV) access before moving on to alternate methods for children in hypovolemic shock. In children under 6 years of age, an intraosseous infusion device can be placed in the proximal tibia or distal femur. This route is only used in an unconscious victim in extremis.

Older children in whom peripheral IV access cannot be obtained require a saphenous vein cutdown at the ankle or groin. This procedure should be performed by a surgeon or someone skilled in this method of securing IV access.

Failure of the previously described methods mandates placement of a central venous line. Possible insertion sites include the subclavian, internal jugular, and the femoral veins. For children in severe shock, the preferred site is the femoral approach. This leaves the head and torso free for reassessment and other procedures and avoids life-threatening complications (i.e., pneumothorax, hemothorax).

### *Fluid Resuscitation*

After assessing for signs of inadequate perfusion and securing intravenous access, administration of a 20 cc/kg crystalloid fluid bolus is appropriate. A careful reassessment following the bolus will provide information as to the need for further fluid challenges. If the heart rate decreases significantly, the mental status clears, or other signs of poor perfusion disappear then no additional fluid boluses are needed. If the child's status is either only slightly improved or unchanged, a second challenge of 20 cc/kg is required. Reassessment after the second bolus using the same evaluation criteria usually reveals a restoration of adequate circulating intravascular volume. Evidence of persistent hypovolemia requires the clinician to conduct a careful search for sources of ongoing or unrecognized hemorrhage. A third crystalloid bolus is initiated and 10 ccs/kg of crossmatched packed red blood cells (PRBCs) delivered via a rapid fluid warmer. If insufficient time has passed for a full crossmatch, unmatched type specific cells, or else O-negative packed red blood cells (PRBCs) are given.

### *Thermoregulation*

The maintenance of the body's core temperature is an essential component in restoring homeostasis to an injured child. Hypothermia, defined as a core temperature less than 36°C causes coagulopathy and acidosis. All fluids are warmed to as near body temperature as possible via in-line warming devices. This is especially true for blood and blood products, which are normally stored at 4°C. The temperature in the resuscitation area is kept high and the child kept covered unless exposure is necessary for examination or intervention. It is much easier to keep an injured child warm than it is to re-warm a child who has become hypothermic.

*Selected Readings*

1. American College of Surgeons Committee on Trauma. Advanced Trauma Life Support Course. Chicago, IL: American College of Surgeons 1997.
2. American Heart Association. Pediatric Advanced Life Support. Dallas, TX: American Heart Association, 1988.
3. Walley KR, Wood LDH. Shock. In: Hall JB, Schmidt GA, Wood JDH eds. Principles of Critical Care, 2<sup>nd</sup> Edition. New York: McGraw Hill 1992; 277–301.

# Blood Component Therapy

*Richard Fox*

Blood component therapy has revolutionized the ability to care for patients with both acute and chronic medical conditions. However, as with the administration of any medication, inherent risks exist. These risks include immunologic, infectious or metabolic derangements. So the medical practitioner must weigh the benefits and risks. To do so, it is important to understand the following information.

## Blood Component Preparation

Whole blood is the source from which all other blood components are derived. A preservative solution is added and the mixture is centrifuged. The resulting product includes packed red blood cells (PRBCs) and a plasma/platelet mixture. The plasma/platelet fraction is further centrifuged to obtain two further preparations: a platelet/clotting factor (except factor VIII) fraction and plasma. Plasma, when frozen and then thawed to 4°C, results in cryoprecipitate and protein fractions.

Whole blood consists of red blood cells and plasma plus a preservative solution. Packed red blood cells consist of red blood cells, minimal amounts of plasma and a storage solution. Platelet fractions contain variable amounts of white blood cells and plasma plus preservative. Fresh frozen plasma contains all coagulation factors and plasma plus a storage solution. Cryoprecipitate consists of factor VIII, XIII, fibrinogen, fibronectin, and von Willebrand's factor. Granulocyte fractions contain white cell, plasma, and storage solution components. Plasma protein consists primarily of albumin with lesser amounts of alpha and beta globulin (but no gamma globulin). In addition, pure albumin solutions (5% and 25%) are commercially available.

## Screening

All donor blood products must be labeled indicating the ABO grouping, and when possible, the Rh type. The Food and Drug Administration (FDA) has mandated that all units for allogeneic transfusion be screened and found negative for antibodies to human immunodeficiency virus (anti-HIV), hepatitis C virus (anti-HCV), hepatitis B core antigen (anti-HBc) and human T-cell lymphotropic virus (anti-HTLV) as well as hepatitis B surface antigen (HBs) and human immunodeficiency virus (HIV-1) antigen. A serologic test is also performed for syphilis.

## Indications for Transfusion

Few absolute criteria for transfusion exist. A better understanding of the risks and benefits of each type of blood component enable clinicians to individualize

transfusion therapy upon established guidelines rather than old “transfusion trigger” principles.

Rarely is whole blood indicated. Furthermore, few institutions maintain an active stock of whole blood. It is reserved for acute blood loss >15-30% of total blood volume. For cases less than this, similar results can be obtained with crystalloid/colloid and packed red cell therapy. Packed red cell therapy is reserved for patients with symptomatic anemia and a hemoglobin value < 6 g/dL. With autologous transfusion, the criteria may be more liberal. One unit of PRBCs contains 250 cc-300 cc and in adults raises the hemoglobin by 1g/dl or the hematocrit by 3%. In neonates 10 cc/kg is the usual initial transfusion amount which raises the hematocrit about 10%.

Platelet therapy is reserved for patients with postoperative bleeding and platelet counts < 50,000/ $\mu$ L, as well as cancer/ chemotherapy patients with rapidly falling or low platelet counts < 10,000/ $\mu$ L. Of note, platelet transfusions are usually ineffective in patients with thrombocytopenia secondary to destruction or circulating autoimmune disorders, such as immune thrombocytopenic purpura (ITP) or thrombotic thrombocytopenic purpura (TTP). One unit (approximately 50 cc) raises the platelet count between 5-10,000 plts/ $\mu$ L in a 70 kg adult, and 20,000 plts/ $\mu$ L in an 18 kg child.

Fresh frozen plasma can be used for rapid coumadin reversal when insufficient time is available for vitamin K reversal (approximately six hours). Other indications include:

1. unidentifiable coagulation factor defects or coagulation factor deficiencies for which specific factor component therapy is unavailable,
2. prothrombin time > 1.5 times normal with microvascular bleeding,
3. massive transfusion with subsequent coagulopathy, and
4. conditions such as TTP. It is not used for plasma volume expansion.

Cryoprecipitate is used for specific factor deficiencies, i.e., factors VIII, XIII, fibrinogen, fibronectin and von Willebrand's factor. In particular, it is second line therapy for patients with:

1. von Willebrand's disease unresponsive to desmopressin therapy, or
2. Factor VIII:C (hemophilia A) deficiency when specific Factor VIII concentrate is unavailable.

Cryoprecipitate may occasionally be indicated when serum fibrinogen levels are below 80-100 mg/dL. The indications for use in patients with fibronectin deficiency are not well defined. Another use of cryoprecipitate is to make a “fibrin glue” by mixing it with topical thrombin to enhance hemostasis.

Albumin and plasma protein fractions are reserved purely for volume expansion. There is currently little support for its use as a nutritional supplementation.

Granulocyte transfusions are available for patients with neutropenia and active infection unresponsive to antibiotic therapy. A recombinant granulocyte colony stimulating factor (gCSF) is also currently available.

A variety of other factors are available for specific deficiencies. Viral inactivated Factor VIII exists for treatment of hemophilia A and von Willebrand's disease. Factor IX (prothrombin complex concentrate) may be used for coumadin reversal and specific factor deficiency. Activated prothrombin complex concentrate (composed

of Factors II, VII, IX, and X) is available for hemophilia A and those with Factor VIII antibody. Rh immune globulin is available for those receiving Rh(D) positive platelet concentrates, or pregnant/postpartum females to minimize isoimmunization. Intravenous immune globulin (IVIG) is available to treat patients with immunoglobulin deficiency or TTP.

## Transfusion Reactions

Immediate and delayed immunologic and nonimmunologic reactions to blood products are well described. Immediate immunologic complications include:

1. hemolytic transfusion reactions,
2. immune-mediated platelet destruction,
3. febrile nonhemolytic reactions, and
4. allergic reactions.

Hemolysis most commonly occurs secondary to ABO incompatibility with intravascular destruction of donor RBCs followed by complement activation, hypotension, diminished renal blood flow and very rarely disseminated intravascular coagulation with multi system organ failure. Symptoms include fever, tachycardia, chills, dyspnea, chest and back pain, and abnormal bleeding. Treatment includes stopping the transfusion, fluid resuscitation and pressor support as necessary. In addition, specimens are sent to the lab to check for hemoglobinuria and hemoglobinemia. Urine is also analyzed for Coomb's direct antibody.

Platelet counts may be refractory to platelet transfusion. Often this occurs secondary to alloantibody directed against human leukocyte antigen (HLA) or platelet specific antigens. It most commonly occurs in patients who have received multiple previous transfusions. Diagnosis is suggested by a poor response noted on posttransfusion platelet levels. Treatment requires HLA matched donor platelets.

Febrile nonhemolytic reactions occur secondary to antibody in the donor or recipient blood directed against white blood cells or cytokine activation. Such reactions occur in 1% of all transfusions and treatment/prevention requires antipyretics or future transfusion with washed red cells.

Allergic reactions are heralded by the appearance of urticaria or even anaphylaxis. Treatment involves preadministration of antihistamine for minor reactions and possibly even epinephrine and corticosteroids when severe.

Delayed immunologic reactions include hemolysis, alloimmunization, and graft-versus-host disease (GVHD). Delayed hemolysis occurs from 2-14 days after transfusion as a result of previous alloimmunization to red blood cell antigen. Transfused cells may remain in the circulation for an extended period of time thus provoking an anesthetic response with fevers, diminished blood counts and development of a positive Coomb's antibody test. Treatment is observation and the course is self-limited. Alloimmunization is an anesthetic response mediated by IgM on secondary exposure to an antigen present on donor red blood cells. GVHD occurs when viable T-lymphocytes in donor blood engraft and destroy host tissue antigen. Severely immunocompromised hosts are the most seriously threatened (i.e., fetus, bone marrow transplant and organ transplant patients, and those with immunodeficiency syndromes). Symptoms include fever, rash, nausea, vomiting and diarrhea with an increase in liver function assays and drop in cell counts. A fatality rate of up to 90%

is described. GVHD cannot be fully prevented but its risk is minimized by using gamma irradiated blood products.

Nonimmunologic complications include infectious disease transmission such as: cytomegalovirus (CMV), hepatitis, HIV, and rarely babesia, bartonella, borrelia, brucella, leishmania, parvovirus, plasmodia, toxoplasma, and trypanosome. Bacterial contamination occurs secondary to both gram positive or negative organisms. Symptoms include fevers, chills, hypotension and shock. Treatment involves stopping the transfusion, administering antibiotics and vasopressors, and obtaining cultures. Circulatory overload syndromes present with pulmonary edema most commonly in patients with chronic severe anemia (because of their low RBC mass with elevated plasma volumes). These complications are avoided by regulating the transfusion rate between 2-4 cc/kg/hr.

Massive transfusion of cold blood products can produce hypothermic complications that present with cardiac arrhythmia and arrest. These are best prevented by using fluid warming devices < 42°C. Metabolic complications of transfusion therapy include: alkalosis or acidosis, citrate toxicity with subsequent hypocalcemia, hyperkalemia from prolonged blood storage, hypokalemia from alkalosis, diminished 2-3 DPG with subsequent leftward shift of the oxygen dissociation curve, and hemosiderosis from chronic transfusions.

### *Selected Readings*

1. Wolf CFW. Blood component therapy. In: Barie PS, Shires GT eds. Surgical Intensive Care. Boston : Little Brown & Company 1993; 723-739.
2. Hutchinson RJ. Surgical implications of hematologic disease. In: O'Neill Jr. JA et al, eds. Pediatric Surgery, 5th edition. St. Louis: Mosby 1998; 157-170.
3. Valeri RC. Physiology of blood transfusion. In: Barie PS, Shires GT eds. Surgical Intensive Care. Boston: Little Brown & Company 1993; 681-721.



# Perioperative Infections and Antibiotics

*Riccardo Superina*

Perioperative infections in surgical patients include postoperative wound infections and other nosocomial infections. In the following Chapter, only those infections that occur in the wound or at the operative site will be discussed. Nosocomial infections such as hospital acquired gastroenteritis, postoperative pneumonia, or infections at peripheral intravenous catheter sites are not considered.

## **Classification and Incidence of Postoperative Wound Infection**

Wound classification is used as a guide to the expected incidence of wound infections. The risk for surgical wound infection depends greatly upon the degree of contamination encountered at the time of operation.

### *Clean Wounds*

Clean wounds are those that result after procedures that have no preoperative infection and during which no mucosal surface is breached. Wound infections in clean wounds are very uncommon and overall should be less than 0.1%.

### *Clean-Contaminated Wounds*

Clean-contaminated wounds result from operations in which a mucosal barrier has been breached but in which no infection or acute inflammation has been encountered. The wound infection rate is less than 1%.

### *Contaminated Wounds*

Wounds that result from operations done in the presence of acute inflammation or active infection are considered contaminated. Wound infections occur in less than 5% of cases.

### *Dirty Wounds*

Dirty wounds are those wounds resulting from operations done in the presence of pus or gross fecal contamination. Wound infection occurs in about 20-30% of these wounds.

## **Etiology**

Bacteria are responsible for most surgical wound infections. These pathogens may be either endogenous or exogenous to the host. Postoperative wound infections

in clean cases usually originate from operating room personnel or from the skin of the patient. For this reason they are usually caused by gram-stain positive organisms such as *Staphylococcus aureus* or *Staphylococcus epidermidis*.

In the other types of surgical wounds, the bacteria causing wound infections usually originate in the host and more specifically, in the organ or organs being operated upon. For this reason, operations on the intestines are complicated by postoperative infections caused by gram-negative bacteria. Wound infections following appendicitis are frequently caused by aerobic or anaerobic colonic organisms. Respiratory flora may be present in wounds after pulmonary resections.

Patients who have been in a hospital for prolonged periods of time become colonized with bacteria that have acquired resistance to many antibiotics. Infections with multi-resistant organisms are more difficult to treat. Examples of such organisms include methicillin-resistant *Staphylococcus aureus* (MRSA) and Enterococci with resistance to vancomycin and ampicillin.

Moderate or severely ill patients acquire defects in neutrophil function that play a permissive role in the development of postoperative infections. These defects include abnormalities in neutrophil migration, intracellular killing and phagocytosis. Factors such as malnutrition, sepsis and trauma all impair host neutrophil defenses. B and T lymphocyte function is also impaired in very sick patients and contributes to the higher than expected incidence of postoperative sepsis observed in these patients.

Newborns are considered immunologically challenged hosts. Neonates have immature bacteriostatic and bactericidal defense mechanisms which place them at greater risk for postoperative infections than older sick children.

## Clinical Presentation

### *Wound Infections*

The findings of redness, tenderness, heat, and swelling at the operative site all suggest postoperative wound infection. Fever may or may not be present. Typically wound infections develop 3-5 days after operation, but this is quite variable. Virulent anaerobic streptococcal infections may cause exquisite pain at the operative site within 24 hours after operation, whereas slow growing Staphylococci may present a week or more after surgery.

### *Deep Infections*

Deeper infections in the chest and abdominal cavity present with fever and pain. In children, accurate description of subjective complaints is not often possible, and reliance on the parents' interpretation of a child's behavior and mood is often a very useful guide to assessing a child's recovery after surgery.

A postoperative ileus that does not resolve after an abdominal procedure should lead one to suspect infection. Abdominal tenderness or redness may indicate an underlying infection. Persistent cough, pleuritic chest pain and tachypnea may indicate an intrathoracic infection after chest procedures.

## Diagnosis

### *Culture*

If a deep postoperative infection is suspected, the diagnosis is established by careful culturing of peripheral blood or wound fluid at the operative site. Postoperative

drains such as chest tubes and intra-abdominal drains may provide samples that if cultured act as a guide to antibiotic selection.

### *Laboratory Tests*

Biochemical and hematologic tests support but do not prove the presence of an infection. An elevated white blood cell count or "left shift" (less mature leukocytes in the differential white blood cell count) support the diagnosis of infection. However, the absence of these indicators does not mean an infection is not present.

### *Diagnostic Imaging*

Plain films sometimes provide valuable data regarding infected postoperative fluid collections. Chest films of patients with intrathoracic infections often show pleural effusions, air fluid levels in the chest, or subpulmonic collections. Plain films are less helpful at localizing collections in the abdomen but may demonstrate other nonspecific signs such as abnormal gas patterns (i.e., ileus), air-fluid levels, or distended loops of bowel.

Ultrasonography and computed tomography (CT) provide accurate information regarding the presence of fluid collections in the abdomen. Ultrasonography can accurately determine size and complexity of intra-abdominal fluid collections. The echogenic characteristics of the fluid can often indicate whether infection in the fluid is likely. Computed tomography (CT) with intravenous contrast may show contrast enhancement at the periphery of a fluid. Contrast enhancement is common with infected fluid collections and abscesses. Radionuclide scans such as gallium scans may be helpful when all other modalities fail but are rarely necessary.

## **Treatment**

### *Antibiotic Prophylaxis*

Antibiotic prophylaxis as a means of preventing postoperative infection is a concept that was introduced and developed in the 1960s by Sir Ashley Miles. In theory, an early critical period of a wound infection exists that determines the outcome of the infection. The conditions in the wound present at the time of the inoculation with bacteria determine the fate of the infection. If antibiotics are administered so that tissue levels are present at the time bacteria are introduced into a wound, then infection can be prevented. If bacteria are inoculated into a site where there is no protection and in which conditions are suitable for growth, then infection and sepsis ensue.

Prophylactic antibiotics to prevent wound infections must be administered prior to the operation so that adequate bacteriostatic levels will be present at the time bacteria are introduced. It is recommended that intravenous antibiotics be administered at least 30-60 minutes before the incision is made. The choice of antibiotics is determined by:

1. the site of the operation and
2. the type of bacteria which are likely to be encountered.

Prophylaxis for clean operations has never been proven to be beneficial except in:

1. immunocompromised hosts,
2. patients at risk for endocarditis, and

3. patients in whom an artificial device such as a vascular prosthesis will be implanted.

Recommendations for prophylactic antibiotic therapy to prevent postoperative infection are listed in Table 11.1.

### *Wound Closure for Dirty Cases*

In adult general surgery, it is customary to leave the skin and subcutaneous tissues open after completion of a dirty or contaminated case. In pediatric cases, it is less customary to do so. Children have fewer postoperative wound infections than adults. This may be mainly because children have less subcutaneous fat and better vascularity to subcutaneous area.

### *Established Wound Infections*

Treatment of established wound infections requires drainage and, in some cases, antibiotic administration. For infections in which there is copious pus and little surrounding inflammation, drainage may be all that is necessary. The host has already contained the infection. If the wound is already partially opened, drainage may already be started and no additional manipulation may be needed. For closed wounds, aspiration with a narrow gauge needle may be attempted under mild sedation and infiltration with local anesthesia. If pus is aspirated, then a portion of the wound may be opened and pus expressed. Irrigation and packing may be necessary to promote growth of granulation tissue and secondary wound closure.

Surgical wounds with purulent drainage, tissue edema, and cellulitis, are at least partially opened and broad-spectrum antibiotics are started. Necrotizing wound infections are always kept in mind. If symptoms do not improve after 12-24 hours as manifest by decrease in the area of redness and swelling, then wound exploration under anesthesia is considered. All necrotic tissue is removed and proper cultures are taken from deep inside the infected area. In the most severe cases, widespread resection of infected areas as well as high-dose antibiotic therapy are necessary for control of the infection.

### *Deep Infections*

The treatment of deeper postoperative infections is guided by the location of the infection, the threat it poses to the host, and the presence of drainable infected fluid. When an abscess has formed, no matter where, drainage is mandatory. Localized collections may be drained by interventional radiologists who can also insert catheters for continued drainage. Postoperative peri-appendiceal infections may be treated very well using this technique and have all but eliminated the need for repeated laparotomies after appendectomy. Drainage will also permit the collection of samples for culture. Antibiotic therapy is recommended even when there is a drainable collection until fever has subsided and the white blood cell count is returning to the normal range.

Treatment of postoperative infections with antibiotics implies that the infection is serious and will spread unless treated. Therefore, broad-spectrum antibiotic therapy is recommended until there has been a response or until cultures have identified an organism allowing sensitivity testing to determine choice of drugs.

**Table 11.1. Recommendations for prophylactic antibiotic therapy in surgical patients**

Site of Operation	Recommended Antibiotics or Antibiotic Therapy
Head and Neck	penicillin and gentamicin
Lungs and Trachea	cefazolin
Biliary Tree and Liver	cefazolin
Small Bowel	ampicillin and gentamicin OR cefoxitin
Large Bowel	ampicillin, metranidazole, and gentamicin OR cefoxitin
Genitourinary Tract	ampicillin
Operations on Newborn Babies	ampicillin and gentamicin for 48 hours prior to operation
Patients at Risk for Endocarditis	penicillin and gentamicin before surgery and for 2 doses following surgery
Subcutaneous Reservoir Placement	cefazolin before surgery and for 2 doses after surgery

Abdominal infections originating from the gastrointestinal tract are treated with antibiotics against gram-positive and gram-negative organisms as well as anaerobes. A useful combination is so called “triple therapy” with metranidazole, ampicillin and gentamicin. Clindamycin is preferred by some instead of metranidazole because of its better gram-positive coverage. For patients with renal impairment, it may be better to substitute a third generation cephalosporin instead of an aminoglycoside (i.e., gentamicin) to cover gram-negative bacteria.

Biliary tract sepsis requires coverage against Enterococci as well as Enterobacter species and therefore includes ampicillin and an aminoglycoside. Vancomycin is substituted for cases in which ampicillin-resistant organisms are possible until sensitivity results are available.

Thoracic postoperative infections are less prevalent than abdominal ones, principally because the intestines are a vast reservoir of bacteria. Infections following lung resections for bronchiectasis or in patients with cystic fibrosis may be difficult to treat. Postoperative empyemas require drainage with large bore chest tube(s) and prolonged treatment with antibiotics. Antibiotic therapy is tailored to specific culture results and sensitivities.

### ***Surgical Re-Exploration***

Postoperative infections, no matter what location, may require re-operation if more conservative measures fail. Failure of conservative treatment is indicated by:

1. continued fever,
2. persistent leukocytosis, and
3. lack of clinical improvement in the patient. A continued septic state in association with radiologic evidence of undrained fluid usually mandates re-exploration.

## Infection of a Central Venous Catheter or Port

Once established, infection of a catheter with or without a subcutaneous port is difficult to eradicate without removal of the device. Urokinase can be administered to facilitate resolution of the infection by dissolving clot at the catheter (nidus of infection). Then treatment with antibiotics for 2–3 weeks may eradicate infection if the patient remains afebrile and blood cultures are negative during the period of treatment. In-patients who receive chemotherapy and have leukopenia are always prone to infection. At least some efforts should be made to salvage intravascular devices in these high risk patients, since removal requires another operation and offers no guarantee that a new infection will not occur. Prophylactic antibiotics should always be considered before insertion or implantation of a central venous catheter and subcutaneous port.

## Yeast Infections

While uncommon, yeast infections are not rare in pediatric surgical patients. Patients who are malnourished, debilitated and often treated with a number of powerful antibiotics are at risk for development of yeast infections. *Candida* is the most common yeast isolated in the pediatric surgical patients. *Candida* is much more difficult to culture than bacteria, and therapy is commonly delayed for that reason.

Any patient suspected of having a serious postoperative infection, yet not improving on antibiotic therapy, should be examined for *Candida* infection. Cultures of the wound, drains and urine are done. Ophthalmologic examination of the fundus and ultrasound examination of the ureters and kidneys may also be done in an attempt to detect evidence of *Candida* infection.

Amphotericin remains the treatment of choice for serious *Candida* infections. Serious infections should be treated for 14–21 days. Fluconazole may be used in less serious cases, particularly if renal function is already impaired. Liposomal amphotericin formulation is also available for use in selected patients with impaired renal function.

## Summary

Children are very resistant to wound infections. Antibiotics are a powerful ally in the treatment of infections, but must be used judiciously and only when necessary. Antibiotic therapy is based on culture results whenever possible, but are not withheld if clinical signs indicate an infection that cannot be proven or characterized.

## Selected Readings

1. Nichols RL. Postoperative infections in the age of drug-resistant gram-positive bacteria. *Amer J Med* 1998; 104:11S–16S.
2. Hunt TK, Hopf HW. Wound healing and wound infection: what surgeons and anesthesiologists can do. *Surg Clin N Amer* 1997; 77:587–606.
3. Nichols RL. Surgical infections: Prevention and treatment—1965 to 1995. *Amer J Surg* 1996; 172:68–74.

## **Section III: Common Pediatric Surgical Problems**

# Inguinal Hernia and Hydrocele

*Juda Z. Jona*

## Incidence

Hernias and hydroceles are among the most common pediatric surgical problems. The incidence of indirect inguinal hernia in the term neonate is 3.5-5%. Premature infants have a higher incidence of approximately 9-11%. Inguinal hernias are more common in boys (male: female ratio is 5:1 to 10:1). Sixty percent of inguinal hernias occur on the right side, while about 30% occur on the left. Ten percent occur as bilateral hernias. Bilateral hernias are more common in premature infants (45-55%) and females. Indirect inguinal hernias and hydroceles are known to have familial tendencies, but true heredity factors have not been clarified.

## Etiology

The processes vaginalis is an elongated diverticulum of the peritoneum which accompanies the testicle upon its descent into the scrotum. It pierces the anterior abdominal wall at the deep (internal) inguinal ring which is located just lateral to the deep inferior epigastric blood vessels. In most individuals, the processes obliterates during the ninth month of intrauterine life or soon after birth. If that channel remains open, intraperitoneal fluid will slowly accumulate in the structure forming a communicating hydrocele (also known as hernia/hydrocele) If the processes is wide enough, intestines, ovaries, or omentum can herniate into the inguinal canal forming an indirect hernia. Should the processes vaginalis obliterate near its origin but remain patent distally fluid may accumulate forming a noncommunicating hydrocele. If the processes obliterates proximally and distally but remains patent in its mid portion then it is known as hydrocele of the cord .

Direct inguinal hernias are occasionally identified in children. The abdominal wall defect is in the floor of the inguinal canal within the confinement of Hasselbach's triangle. Anatomically, Hasselbach's triangle is that area bordered superolaterally by the inferior epigastric vessels, inferiorly by the inguinal ligament, medially by the rectus abdominus muscle. Direct inguinal hernias are believed to occur secondary to structural weakness. Femoral hernias occur inferior to the inguinal ligament within the femoral canal, just medial to the femoral vessels and are extremely rare in children.

## Clinical Presentation

A bulge (swelling) in the groin which at times may extend into the scrotum is by far the most frequent sign. The bulge may appear and then disappear with some regularity especially during straining, crying, or coughing. Although sharp pain is



usually not associated with herniation, discomfort that occurs in some babies is easily overlooked. Occasionally constipation, “colicky-baby” syndrome, and even regurgitation are present.

In the very young, the initial presentation may be an episode of incarceration. In this scenario, the baby is more symptomatic, the bulge is firm and tender to touch, the groin and scrotum may be erythematous, and vomiting or poor feeding are frequent. A history of recurring groin swelling which the parents or the pediatrician can reduce is a strong indication that a hernia is present.

## Diagnosis

The physical examination in many is so characteristic that only observation is necessary to make the diagnosis. The examiner palpates the cord to ascertain if bowel or other structures are present. Diagnostic confirmation is made when the contents of the hernia are reduced into the peritoneal cavity. Hydroceles, even the communicating variety, are difficult to reduce though many reduce spontaneously when the child is recumbent over several hours. Many physicians resort to transillumination to distinguish a hydrocele from a hernia containing bowel. However, this may be misleading, particularly in infants, since a hernia with gas-filled bowel loops may transilluminate quite well. If the child presents with a reduced hernia, secondary changes can be found that suggest presence of a hernia. Palpation of the cord may elicit the “silk glove” sign (rubbing together of the opposing peritoneal membranes of the empty sac). The cord may feel thickened in comparison to the contralateral side. Increases in intra-abdominal pressure (i.e., coughing, crying, exhaling against an occlusion such as thumb in mouth, blowing bubbles, etc) may help demonstrate the hernia.

In the face of a suggestive history but no concrete findings, repeated examination in 2-3 weeks is recommended. The parents should continue observation, be taught how to reduce the hernia and, at times, even resort to photographing the hernia so that a definite diagnosis can be established.

Complete history and physical examination may reveal other unrecognized conditions. The genitalia and the testicles must be carefully examined. At times, a retractile testis presents as an inguinal bulge and appears to be a hernia. Undescended testes are commonly (85%) associated with indirect hernia, and the two conditions are repaired at the same time. Occasionally, the differential diagnosis includes inguinal or femoral adenopathy. If an adenitis has progressed to an abscess, the findings may be difficult to distinguish from an advanced stage of incarcerated inguinal hernia. In this scenario, immediate surgical exploration is undertaken for both diagnosis and treatment.

When incarceration is suspected, plain abdominal films are helpful and demonstrate an obstructive/ileus bowel gas pattern and intestinal gas in the groin and scrotum. Plain films are also useful to distinguish between an acute hydrocele, for which an operation can be delayed, and incarceration which requires immediate attention. When in doubt—operate! Untreated incarceration leads to bowel necrosis and/or testicular ischemia.

## Treatment

The reason for repairing an inguinal hernia is to prevent incarceration. Since the incidence of incarceration is inversely related to age, the younger the patient—the sooner the repair. Premature babies should have their hernias repaired just prior to discharge from the hospital. Asymptomatic school age children can be repaired when school is in recess. The timing of repair is less clear with hydroceles. In most centers, hydroceles are not repaired until the baby is 12-18 months or older. Approximately 90-95% of all hydroceles resolve spontaneously in the first few months of life. If a hydrocele becomes very large and tense, earlier repair can be considered. If a hydrocele cannot be differentiated from a hernia, operation is indicated.

The operation is an outpatient procedure performed under general anesthesia. Infants less than 60 weeks postconception and children with associated conditions (i.e., cystic fibrosis, hemophilia, etc.) Need admission for 24 hours of observation. The recommended steps of inguinal hernia repair are listed in Table 12.1.

Postoperative care is straightforward. Since intradermal absorbable sutures are used for wound closure, most of these patients can start routine bathing within 24-48 hours. No restriction on diet or activities is given. Tylenol for analgesia is all that is required. In the older children, ibuprofen or codeine may be necessary. Patients with long-standing hernias, large hydroceles or formation of fibrous adhesive tissue around the cord may experience induration in the operative area that eventually subsides. These children deserve extended follow-up as occasionally the testicle on the affected side may be drawn out of the scrotum and requires secondary orchidopexy.

## Outcomes

Recurrent herniation is rare and is seen in less than 1% of cases. More often, residual or posttraumatic hydroceles may be noted. If they do not resolve after several months, aspiration of their contents may expedite resolution.

## Special Considerations

### *Contralateral Exploration (CLE)*

The issue regarding the merits and objections to routine CLE in pediatric inguinal hernia is still not resolved among pediatric surgeons. Since the incidence of bilateral involvement in the first year or two of life is high (20-40%), most surgeons at pediatric centers perform CLE. Some surgeons extend CLE to mid-childhood (6 years old). The author's experience and many studies support exploration in all preschool children. In certain instances (i.e., strong family history, complicating circumstances like hemophilia or cystic fibrosis), exploration is offered to even older children. Resistance to this practice has been voiced by some European surgeons who report unacceptable complication rates. Either way, the family must understand the pros and cons and be an integral part of the decision making.

### *Operation for Incarcerated Hernias*

If clinically the patient presents with peritonitis and the picture of sepsis, strangulation must be suspected. Antibiotics and massive preoperative resuscitation (rapid) is done. Initially, standard inguinal exposure is carried out, although the abdomen is prepped widely. The sac that is commonly edematous is freed from the cord structures.

**Table 12.1. Guidelines for inguinal hernia repair**

1. The surgical prep includes the lower 1/2 of the abdomen, genitalia, and upper thighs.
2. The incision is relatively short and is positioned in an inguinal skin crease at the level of the internal inguinal ring.
3. The aponeurosis of the external oblique is exposed and followed inferiorly until definite identification of the inguinal ligament is made.
4. The inguinal ligament is followed medially towards the pubic tubercle and the external inguinal ring is clearly identified.
5. The external oblique is divided along its fibers so as to transect the external ring, thus exposing the contents of the inguinal canal. (In small children this step may be omitted and the hernia repaired without opening the ring.)
6. Near the pubic tubercle, the cord and hernia sac are elevated with atraumatic forceps and encircled. Care is taken not to pierce the inguinal floor and produce a direct hernia.
7. A curved Kelly clamp is passed under the cord and sac upon which they now rest.
8. Careful separation of any cremasteric fibers allows identification of the sac that is gently grasped and elevated. With the sac pulled up and medially, the vas and vessels are exposed and gently teased off the sac. The vessels come off easily. The vas is quite intimate with the sac and is always an extraperitoneal structure.
9. Once freed, the cord structures are encircled with a narrow penrose drain in older children (or an Allis clamp in the very young) to protect these structures.
10. If the sac is empty, it can be divided between clamps and each section freed separately. The proximal sac is held at some tension and with gentle pull of the cord structures the areolar tissue between the two is identified and cleared either bluntly with forceps or sharply with scissors. As one reaches the internal ring, the lip of the internal oblique muscles is retracted so that high ligation of the sac can be done.
11. The neck of the sac is suture ligated with either an absorbable or nonabsorbable suture. The floor of the canal is inspected. On rare occasions, additional sutures are required to narrow the internal ring.
12. The distal sac is opened. If a hydrocele of the testis is present it is opened. The testicle is drawn back into the scrotum by gentle pull on the scrotum.
13. Once hemostasis is assured, the external ring, if opened, is reconstructed and the external oblique is gently approximated. At this point, 0.25% marcain is instilled into the wound and subcutaneous tissue for postoperative pain control. Make sure that the testicle is repositioned in the scrotum properly.
14. The skin and scarpa's fascia are closed.

The sac is opened and the bowel inspected. If viability is established (immediately or after a period of observation), the bowel is returned to the peritoneal cavity. Widening of the internal ring may be required at times. If strangulation is the case, a Laroque type (RLQ) incision is made and the peritoneum entered. It is wise to isolate the bowel entering and exiting the hernia such that the intestinal spillage is minimized. Formal resection requires direct anastomosis in most instances unless the patient is most unstable. The hernia ring can be closed either from the inguinal or the peritoneal side. Antibiotics are administered for 48 hours or until the ileus resolves.

### *Femoral Hernias*

Femoral hernias occur inferior to the inguinal ligament, along the femoral canal, medial to the femoral vessels. Femoral hernias are extremely rare in childhood but are more common in females. The diagnosis is most difficult in the very young and in those with excessive adipose tissue. In the lean and cooperative patient, a bulge is noted below the inguinal crease. Unfortunately, most are diagnosed after a routine inguinal exploration in which only a small indirect hernia or no hernia was found. In these cases, the femoral canal must be explored. This is accomplished by incising the transversalis fascia in the Hasselbach's triangle close to the Poupart ligament. The hernia will be identifiable medial to the femoral vein. The Cooper's ligament repair is the treatment of choice. If the diagnosis is made preoperatively, a subinguinal (femoral canal) approach can be used in which the space medial to the vessels is eliminated after reduction of the hernia and its contents.

### *Selected Readings*

1. Lloyd DA, Rintala RJ. Inguinal hernia and hydrocele. In: O'Neill Jr. JA et al, eds. *Pediatric Surgery*, 5th Edition St. Louis: Mosby 1998; 1071-1086.
2. Potts WJ, Riker WL, Lewis JE. The treatment of inguinal hernia in infants and children. *Ann Surg* 1950; 132:566.
3. Rowe MI, Marchildon MB. Inguinal hernia and hydrocele in infants and children. *Surg Clin North Am* 1981; 51:1137.
4. Surana R, Puri P. Is contralateral exploration necessary in infants with unilateral inguinal hernia? *J Pediatr Surg* 1993; 28:1026.
5. Rajput A, Gauderer MWL, Hack M. Inguinal hernias in very low birth weight infants: incidence and timing of repair. *J Pediatr Surg* 1992; 27:1322.

# Varicocele

*Juda Z. Jona*

## **Incidence**

Varicocele results from dilation of the testicular veins within the pampiniform venous plexus. It is rare in children less than 10 years of age. At adolescence, the incidence is 10-15%.

## **Etiology**

Varicocele occurs because of increased hydrostatic pressure within the gonadal veins. This may be due to either incompetent venous valves or venous obstruction. Its relative greater occurrence on the left side is related to the fact that the left gonadal venous drainage is to the left renal veins rather than directly to the IVC as occurs on the right side.

## **Clinical Presentation**

Varicocele occurs predominately in postpubertal teenagers and young adults and occurs almost exclusively on the left side (80-90%). Most boys describe enlargement of the cord and testicle after physical activities, coughing or straining. The lesion is a complex elongated "cord," at times, described as a "tangle of worms." Standing and straining may demonstrate the varicocele. Tenderness is not a common finding. With the patient supine and resting, the swelling will recede. The differential diagnosis includes hernia, hydrocele, and tumor. Diagnostic testing is rarely required for varicocele.

Younger children with Wilms' tumor, neuroblastoma, or hydronephrosis may present with a varicocele which is caused by obstruction of venous return from the testis. In cases of right-sided varicocele (1-7%), the presence of a retroperitoneal mass should be considered. Bilateral lesions occur in 2-20% of patients.

## **Pathophysiology**

A varicocele increases blood surrounding the testis, thereby raising the testicular temperature as heat dissipates from the venous blood. Spermatogenesis is decreased with an increase in testicular temperature. In addition, hormone-like substances secreted by the affected testicle may adversely influence contralateral testicular function.

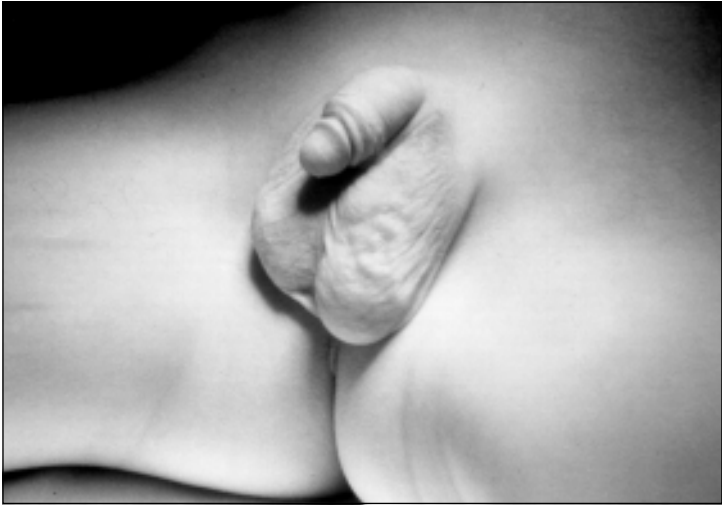

Fig. 13.1. The tortuous, venous channels of a varicocele are easily visualized in the left scrotal sac. This child proved to have a Wilms' tumor involving the left kidney.

### Treatment

Operative interruption of the gonadal vein is curative. Traditionally, this is carried out through an inguinal exposure. Recent reports suggest that these patients can be successfully treated laparoscopically. Using this technique, the main gonadal vein trunk is interrupted in the retroperitoneum. Some surgeons ligate the gonadal artery as well (with the hope of reducing the recurrence rate) and rely on the collateral blood supply (perivas, gubernacular and pudendal vessels) to maintain testicular viability. This technique is known as the Fowler-Stevens maneuver, which is commonly used to treat intra-abdominal cryptorchidism.

### Outcomes

Most varicocele operations are successful and in many fertility is preserved or restored. The risk of recurrence after operative treatment is between 5% and 45%. Reactive hydrocele occurs in about 10-35%. Other surgical complications include testicular atrophy, nerve injury, and injury to the vas deferens. If recurrence occurs, contrast radiography or ultrasound may be required to demonstrate the site of recurrence.

### Selected Readings

1. Palomo A. A radical cure of varicocele by a new technique: Preliminary report. *J Urol* 1949; 61:604.
2. Hutson JM. Undescended testis, torsion, and varicocele. In: O'Neill Jr. JA et al. eds. *Pediatric Surgery*, 5th Edition. Vol. 2. St. Louis: Mosby 1998; 1101-1105.

# Testicular Torsion

*Juda Z. Jona*

## Incidence

The incidence of this condition is hard to estimate, since many occur antenatally. Torsion can strike at any age, however, it is most prevalent in the early teen years.

## Etiology

There are two variations of this condition. Extravaginal torsion is more common in fetuses and neonates and denotes torsion of the spermatic cord along its course but outside the tunica vaginalis. Most babies born with an absent (“vanishing”) testes are victims of this type of prenatal torsion. Absence of testicular fixation is believed to predispose the testicle to this type of torsion. The other variety, intravaginal torsion, is more common in childhood and occurs within the tunica vaginalis. In these cases, fixation of the tunica vaginalis is to the cord and not the testicle. The testicle is suspended within the tunica vaginalis causing a “Bell-Clapper” deformity. Contraction of the cremasteric muscle initiates testicular rotation in these predisposed testicles.

## Clinical Presentation

Prenatal testicular torsion will present with an empty scrotum. Exploration will reveal an interrupted spermatic cord and absent testes. Neonates with unilateral cryptorchidism may have had an in utero torsion. Perinatal testicular torsion will present as a tender mass in the scrotum. Others may present with a red, firm, tender mass of the groin area which may not be distinguishable from an incarcerated hernia. Older children and teenagers will present with a sudden onset of severe testicular pain followed by local swelling and firmness with radiation of pain to the ipsilateral groin and lower abdomen. A history of similar short-lived events may suggest previous episodes of torsion that spontaneously resolved.

On examination, the child is restless and in obvious pain. On inspection, the involved testicle is “high-riding” (Fig. 14.1). Later the scrotum becomes swollen, red and tender. Careful and gentle palpation of the cord and scrotal contents may yield a clue to the diagnosis. In epididymitis, the tenderness will be selectively located in the posterior zone of the testicle and may extend along the distal spermatic cord (best examined against the pubic tubercle). In addition, pyuria may be found. In cases of torsion of the appendix testes, transillumination may demonstrate a “blue

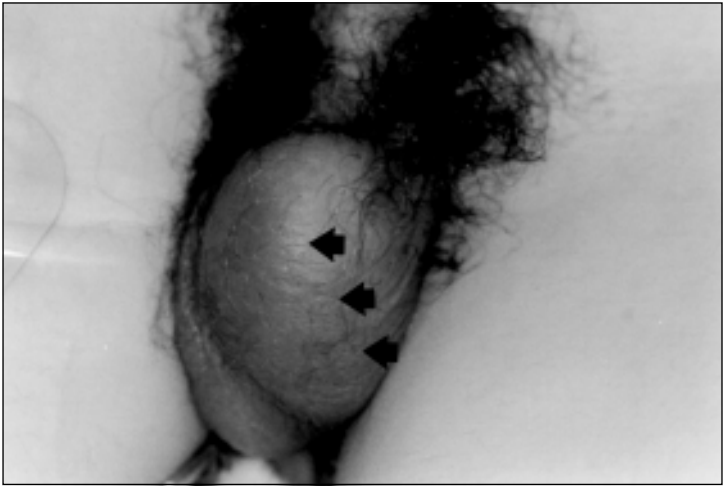


Fig. 14.1. Left-sided testicular torsion demonstrated by swelling and high positioning of the usually lower left testis.

dot" sign on the superior aspect of the testicle. This site will be tender, but otherwise, the testicle and the cords are uninvolved.

### Diagnosis

In most instances, history and gentle examination will yield the correct diagnosis. If the diagnosis is unclear, ultrasonography with doppler and/or technetium scanning are indicated. Ultrasonography is portable, ubiquitous and inexpensive. Unfortunately, it requires pressure on the tender scrotum and is very operator dependent. Radioisotope scanning is the most sensitive test, but may not be readily available, is time consuming and is relatively expensive. Both tests confirm the diagnosis of torsion by demonstrating cessation of blood flow to the involved gonad. Nuclear scans are more specific and can distinguish testicular torsion from inflammation, epididymitis or torted appendix testes.

### Pathophysiology

Torsion results in testicular ischemia. A rotation of  $270^\circ$  or greater will impair blood supply to the gonad. If treatment is not promptly instituted (i.e., within 6-8 hours), ischemic gangrene of the testicle can occur. Spermatogonia are more sensitive to blood flow and oxygen deprivation than Sertoli/Leydig cells, so that in subacute cases androgen production may be preserved but spermatogenesis impaired.

### Treatment

Immediate surgical exploration is the treatment of choice. Delay for confirmatory ultrasound or radionucleotide scanning is not indicated. Exploration is through a scrotal, median raphe incision. The affected testicle is inspected, detorsed, and placed in a warm sponge. Up to 30 minutes observation is acceptable. If doubt



remains regarding viability, the testis is incised to determine the presence of bleeding. The flow of the tunica may be restored to some extent while the parenchyma remains underperfused. Debate ranges regarding the treatment of marginally viable testicle. Some replace it into the scrotum and follow testicular size. If atrophy or hypoplasia ensue, the testicle is removed. Others, fearing adverse effects on the normal testicle (i.e., autoimmunization to spermatogonia), will perform orchiectomy at initial exploration. In all cases, the contralateral testicle is fixed in the scrotum with 4 sutures, also through a scrotal incision. In infants, an inguinal incision may afford some advantages in cases of questionable diagnosis (i.e., incarcerated hernia) or if the torsion has occurred in an undescended testicle.

## Outcomes

Postoperative care in these children is not complicated; however, a torsed testicle may atrophy with time. Long-term follow-up is imperative. Testicular salvage rates are directly proportional to duration of torsion. For torsion less than 6 hours, 85-97% can be salvaged. If the duration of torsion exceeds 24 hours, the chance of salvaging the testes is less than 10%.

## Selected Readings

1. Noseworthy J. Testicular torsion. In: Ashkraft KW, Holder TM, eds. *Pediatric Surgery*, 2nd Edition. Philadelphia: W.B. Saunders Company 1993; 505-600.
2. Hutson JM. Undescended testis, torsion, and varicocele. In: O'Neill Jr. JA et al, eds. *Pediatric Surgery*, 5th Edition, St Louis: Mosby 1998; 1099-1101.

# Cryptorchidism: The Undescended Testes (UDT)

*Juda Z. Jona*

## **Incidence**

Undescended testes afflicts about 1% of males.

## **Etiology**

The testes develop from the primitive urogenital ridge and differentiate into gonads. Then they descend, migrating in the retroperitoneum toward the internal inguinal ring guided by hormones and the gubernaculum. At about 20 weeks gestation, the testes emerge from the external canal. By 36-38 weeks, most “arrive” in the scrotum. Failure of descent is due to mechanical obstacles, improper gubernacular attachment or function, or intrinsic abnormality of the testis. UDT is seen with other anomalies including anorectal and genitourinary anomalies.

## **Clinical Presentation**

Empty scrotum and inguinal mass are common presenting complaints. It is important to know if the testis was seen or felt in the scrotum. The examination must be performed in a comfortable and warm environment. Visual inspection is particularly helpful, since any tactile stimulation of the lower abdomen, upper thighs or genitalia may evoke cremasteric muscle response and retract the testes out of the scrotum. If a mass is seen in the groin, it should be assessed carefully for size, shape and mobility. With constant mild traction, a retractile testis can be coaxed back into the scrotum. The abdomen, upper thighs and perineum must be palpated to ascertain the presence of an ectopic testis. If no gonad is perceived, more careful examination against the pubic tubercle may demonstrate a “cord” (vas) which suggests an atrophic testis. If no remnant of testicular structures are found, abdominal ultrasound may show the absence of the ipsilateral kidney. If absent, the testes is assumed to be absent and surgical exploration is deferred. The evaluation of a phenotypic male without any obvious testes may denote bilateral cryptorchidism or an intersex problem. These infants require more urgent evaluation including chromosome analysis, hormone and steroid assays, and more advanced imaging. Laparoscopy is particularly useful in these situations for diagnosis and initiation of therapy (Fig. 15.1).

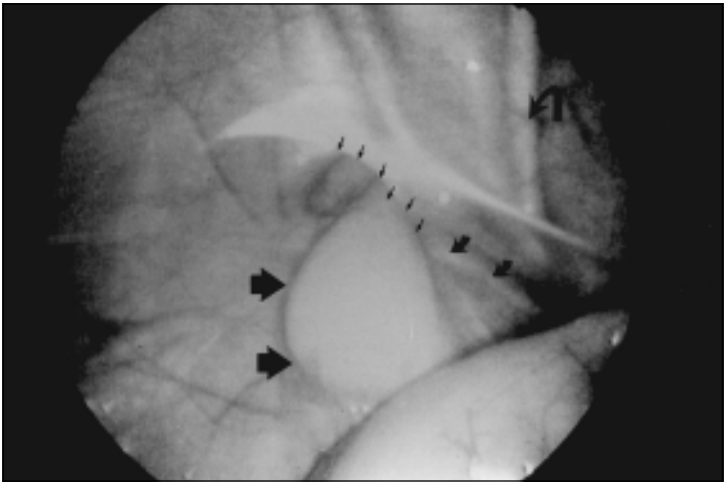


Fig. 15.1. Laparoscopic view of left undescended testis (large arrows) near the internal ring (smallest arrows). The vas is seen medially (medium arrows) and the umbilical artery is seen along the anterior abdominal wall (curved arrow).

## Treatment

Unless bilateral, cryptorchidism can be addressed when the baby has passed his first birthday. However, an associated inguinal intervention (85%), may mandate earlier intervention. In such situations, UDT should be corrected at the time of hernia repair. Definitive correction of UDT best done between 1-2 years of age. By that time, delayed descent can be noted, precise examination is easier to perform, and a period of observation by parents and pediatricians will determine that the problem is UDT rather than retractile testis. Delay beyond two years of age is unwarranted.

The indications for surgery include:

1. the prevention of torsion,
2. reducing the risk of trauma,
3. repair of an associated hernia,
4. improving fertility,
5. examination for tumor, and
6. cosmesis.

Operation is outpatient with general anesthesia. If the testicle is not palpable, laparoscopy should be performed (Fig. 15.2). If the testicle is at or near the internal ring, inguinal exploration is performed. If the testicle is intra-abdominal, the testicular vessels may be divided and the testicle is brought down as a second stage. The important steps of orchiopexy include adhesion lysis, herniorrhaphy, mobilization/transposition of the vessels, and formal orchiopexy.

If the testis cannot reach the scrotum comfortably, it should be sutured to the pubic tubercle and a second stage orchidopexy is performed at 6-12 months.

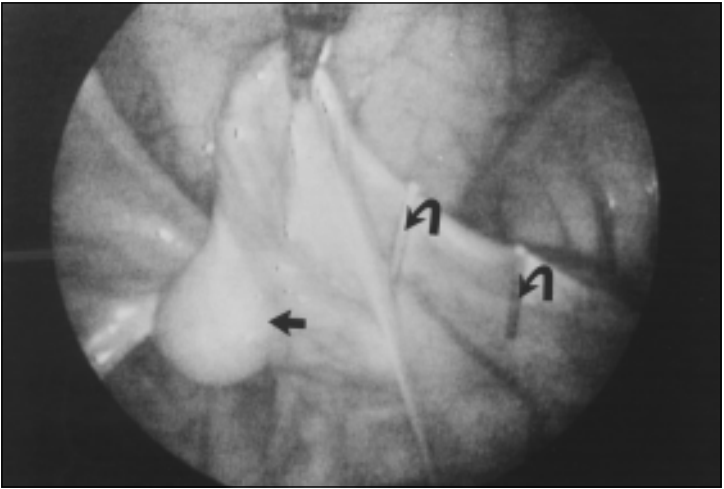


Fig. 15.2. Laparoscopic view of left undescended testis (single arrow) with testicular artery and vein clipped (curved arrows) in preparation for subsequent pull-down procedure.

## Outcomes

Postoperative visits ascertain wound healing, presence of infection or hematoma, and follow the size and position of the testicle. The parents and pediatrician are instructed to perform frequent examinations. Complications of orchidopexy include injury to the vas deferens or testicular vessels (1%), testicular atrophy (< 8%) and a high-riding testicle (5-10%). Fertility after orchidopexy for unilateral UDT is 95%, but only 70% for bilateral UDT. The risk of testicular malignancy in patients with a history of cryptorchidism is 5-10 times greater than the normal population. The risk is greater for bilateral cryptorchidism and intra-abdominal testes.

## Selected Readings

1. Hutson JM. Undescended testis, torsion, and varicocele. In: O'Neill, Jr. JA et al, eds. Pediatric Surgery, 5th Edition. St. Louis: Mosby 1998; 1087-1089.
2. Fonkalsrud EW, Mengel W. The undescended testes. Chicago: Year Book Medical Publishers 1981.
3. Scorer CG. The descent of the testis. Arch Dis Child 1964; 39:605.

# Circumcision

*Lars Göran Friberg and Juda Z. Jona*

Few topics generate as much controversy as whether a child should undergo circumcision or not. In a global sense, this is the most common surgical procedure performed on children.

## Male Circumcision

In the male child, circumcision means resection of the penile foreskin via an encircling skin incision made in the foreskin proximal to the corona. The indication for this is cultural (often religious) or rarely to relieve obstruction due to phimosis. Although it is essentially a cosmetic procedure, considerable effort has been undertaken to prove the benefits of circumcision in the newborn period. The results of all these studies are scientifically very questionable. Complications include bleeding, infection, and meatal stenosis.

The role of the male foreskin is to protect the glans and the meatus. After puberty the foreskin lessens the friction during sexual intercourse. These properties are lost after circumcision. The care of the male foreskin should be **no touch** except for the boy himself or his future sexual partner(s). There is no need to cleanse the inside of the foreskin before puberty. The same goes with girls, where there is no need at all to clean the vaginal cavity.

There have been a considerable number of reports published concerning the retractibility of the male foreskin at different ages. At birth the foreskin seldom retracts but if the meatus is clear allowing free urination, there is no problem. Separation begins when infants experience erection and continues with increasing frequency to puberty. By teenage years, retraction should be sufficient to allow good hygiene, free and easy urination, and comfortable intercourse. Full retractibility is by nature desired only when reproduction starts.

## Female Circumcision

In the female child, circumcision means resection of the external genitalia. This can be done in different ways. In the mildest form, only the tip of the clitoris is resected, but in the Faraonic circumcision the whole clitoris, the minor labia and the major labia are extirpated and the opening is sewn together just permitting voiding and passing of menstrual blood. The indication for female circumcision is for cultural initiation, to be a part of the female society. It is predominantly performed in some parts of Africa.

There is no medical indication for female circumcision. The complication rate is unknown, but bleeding is the most common postoperative complication and is sometimes fatal. The disadvantages are difficulties with future sexual life and birthing, at which time the Faraonic circumcision must be mechanically opened. After giving birth, there is often a desire to be restored to the circumcised status.

To remember: no child has ever asked for circumcision!

## **Phimosis**

### *Incidence*

Phimosis is a condition of circumferential scarring at the tip of the foreskin, which prevents retraction. Incidence is about 1% or 2%.

### *Etiology*

Infection, balanopostitis, or forceful retraction maneuvers lead to scarring of the prepuce. The phimosis usually presents late in infancy and occasionally there is history of urinary tract infection. Physical examination shows obstruction of urinary flow and inability to retract the foreskin. Treatment is plastic surgical procedure to open the prepuce, or in severe cases circumcision.

### *Selected Readings*

1. Rowe MI et al. Male external genitalia. In: Rowe MI, O'Neill Jr JA, Grosfeld JL et al, eds. *Essentials of Pediatric Surgery*. St. Louis: Mosby-Yearbook Inc. 1995; 769-770.
2. International Code of Medical Ethics. Adopted 35th World Medical Assembly. Venice, Italy, Oct 1983.
3. AAP Task Force on Circumcision: Report of the Task Force on Circumcision. *Pediatrics* 1989; 84:388.
4. Baskin LS, Canning DA, Snyder HM et al. Treating complications of circumcision. *Pediatr Emer Care* 1996; 12:62-68.

# Hemangiomas and Vascular Malformations

*Maureen Sheehan and Daniel A. Bambini*

## **Incidence**

Vascular anomalies are relatively common in neonates and infants. Hemangiomas are the most common benign tumor of infancy yet account for less than one third of congenital vascular lesions. Congenital hemangiomas occur in only 1.1-2.6% of term infants; however, that incidence increases to almost 30% in premature infants weighing less than 1000 grams. Although few are evident at birth, 70-90% of hemangiomas are apparent by one month of age. Females are affected 3-5 times more than males. Incidence also varies with ethnic origin. Caucasians have the highest incidence of hemangiomas accounting for 10% of patients; the incidence is much lower in children of African-American or Asian descent.

Vascular malformations, unlike true hemangiomas, are always present at birth although not always apparent. They affect females and males equally. The incidence of each type of vascular malformation is quite variable. Capillary malformations are the most common affecting 3-6 per 1,000 infants. Both clinical management and outcome vary with the type of lesion present.

## **Etiology**

Hemangiomas are neoplastic growths that most often occur sporadically although 10% are familial. The exact etiology remains unknown. The growth consists of a mass of endothelial cell proliferation interspersed with vascular lumens and channels. Hemangioma formation may represent faulty embryonic development of peripheral blood vessels in which endothelial cells undergo neo-vascularization and canalization.

Vascular malformations result from developmental errors of arteries, veins, capillaries, or lymphatics. During the third week of fetal life, mesenchymal cells differentiate into primitive capillary clusters and by the 48<sup>th</sup> day of gestation the capillary clusters connect with feeding arteries and draining veins. Lymphatics are formed from buds off the veins forming a parallel drainage system. Vascular malformations occur as a result of hypoplasia, hyperplasia, or aplasia of any (or a combination) of the developing vascular structures.

## **Clinical Presentation**

Hemangiomas most frequently occur on the head and neck (60%); the trunk is the next most frequent site of occurrence followed by the extremities. Hemangiomas are frequently identified after a period of rapid growth and continue to enlarge

disproportionate to the child's growth over the first 6-8 months of life. During the rapid growth phase, superficial lesions appear bright red while deeper lesions have a purple or blue hue. The period of rapid growth is followed by a stationary phase and ultimately by a period of involution (usually beginning by 18 months of age). The stages are not mutually exclusive, and frequently involution and proliferation occur simultaneously within different areas of the same lesion. During the involution stage, hemangiomas often fade to a blue-gray color and acquire an area of central pallor. The time required for full involution varies: 50% involute by age 5, 70% involute by age 7, and 90% involute by age 9. Despite complete resolution, some skin changes (i.e., pallor, atrophy, or skin redundancy) may persist in 10-20% of cases. Scarring usually does not occur unless the lesion has areas of ulceration.

Vascular malformations are present at birth but not necessarily obvious. The presentation of the lesion differs depending on the etiology of the lesion and location. High flow lesions such as arteriovenous malformations usually become apparent on physical exam with noted warmth, palpable thrill, audible bruit, or visible pulsation. Capillary vascular malformations appear to follow sensory nerve distribution and have a purplish hue. Venous malformations undergo gradual dilation that give the appearance of a growing lesion sometimes mistaken for a hemangioma. Venous malformations are easily compressible and swell with dependent positioning. Lymphangiomatous lesions often require the assistance of gravity to become apparent and frequently lead to increased limb circumference. Lymphangiomas rapidly enlarge when they become infected and seldom undergo full regression after treatment.

## Diagnosis

Hemangiomas (Fig. 17.1) are most often diagnosed based on history and physical exam; further diagnostic testing is usually not warranted. The differential diagnosis of the hemangiomas varies with its stage of growth. During the pre-eruptive state, hemangiomas may be confused for a nevus, port wine stain, or focal dermal hypoplasia. At later stage, they may appear similar to spider angiomas, angiokeratomas, or pyogenic granulomas.

Computed tomography (CT) and magnetic resonance imaging (MRI) are very useful to define the nature of vascular lesions. For hemangiomas, the appearance on CT varies depending on the stage of growth. During the proliferative phase, hemangiomas appear well circumscribed with homogenous enhancement. Hemangiomas undergoing involution appear more lobulated and heterogeneous. The CT appearance of vascular malformations varies depending upon their origin and location. Venous malformations typically have heterogeneous enhancement and sometimes contain calcifications. Lymphatic malformations appear as multiloculated cysts with septa. Musculoskeletal changes such as hypertrophy, distortion, or destruction can also be identified by CT of vascular malformations

MRI and magnetic resonance angiography (MRA) are perhaps the most accurate radiologic studies to evaluate vascular lesions. MRI/MRA differentiate hemangiomas from vascular malformations, easily distinguished high flow lesions from low flow lesions, and correctly identify lymphatic malformations.



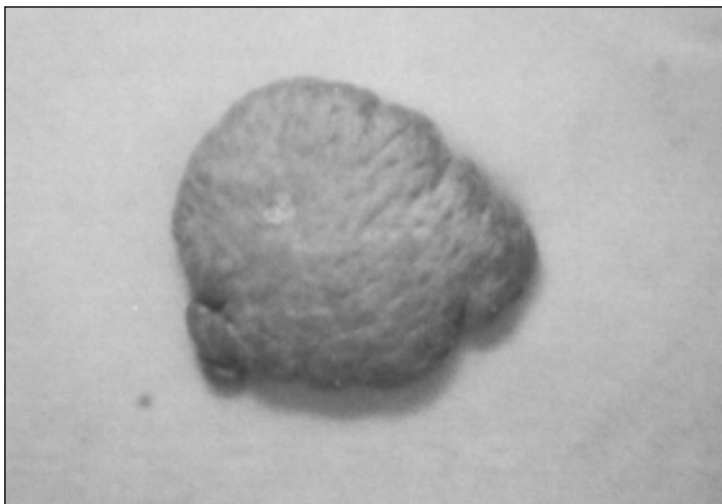


Fig. 17.1. Raised, spongy mass typical of a cavernous capillary hemangioma.

### Pathology

When hemangiomas in the proliferative phase are studied with electron microscopy, a multilaminar basement membrane and an abundance of mast cells are prominent features. Mast cells release heparin which modulates angiogenic factors and promotes blood vessel formation. The endothelial cells of proliferating hemangiomas appear flattened. Uptake of  $^3\text{H}$ -thymidine, a marker for rapid cellular proliferation, is much increased.

Vascular malformations have an increased ratio of endothelial cells to smooth muscle cells of 214:1 as compared to a ratio of 10:1 to 62:1 found in normal vessels. Histologic features include:

1. ectatic capillaries, veins, or lymphatics,
2. thin basement membranes and
3. absence of rapid endothelial turnover.

Lymphatic malformations are sometimes classified as microcystic, macrocystic, or combined. When viewed under the light microscope, these lesions are composed of abnormal vesicles or ectatic channels filled with lymphatic fluid. Capillary malformations are composed of a network of dilated capillaries and venules in varying densities.

### Treatment

The treatment course of hemangiomas is one of observation which allows 70-90% complete involution. Vascular crises require a more aggressive approach as does the rare hemangioma that:

1. involves the visual axis which may cause permanent amblyopia,
2. causes airway obstruction,

3. causes bilateral auditory canal obstruction,
4. causes congestive heart failure,
5. is associated with Kasabach-Merritt syndrome. Surgery to assure a good cosmetic result is considered in patients with pedunculated lesions, bulky lesions (such as on the nasal tip), or ulcerated lesions. Cryotherapy is occasionally used to ablate hemangiomas but frequently leaves hypo-pigmented lesions and atrophic scarring. For large lesions that infiltrate vital structures, corticosteroid therapy for 4-6 weeks is advocated. The dose is high, involution occurs rapidly if at all (< 30% of cases), and the lesion may regrow when the steroids are tapered. Alpha interferon will also produce regression in many hemangiomas that produce risk to life. The treatment however requires months and is slow to produce results.

Treatment for vascular malformations varies dependent on the etiology. Port wine stains are best ablated using laser photocoagulation. Venous malformations are sometimes treated using laser therapy, but may be amenable to compression stockings, sclerotherapy, or surgical removal. Debulking, when appropriate, is effective for lymphatic malformations, however, this treatment is frequently limited by the proximity of lymphatics to important anatomic structures. Antibiotics are necessary to treat lymphatic malformations if they become infected.

Arteriovenous malformations require surgical excision. Simple ligation is ineffective and embolization has generally failed for large lesions but is useful when performed within 24 hours preceding operation to reduce blood loss at the time of excision.

### *Selected Readings*

1. Wahrman JE, Honig PJ. Hemangiomas. *Peds in Review* 1994; 15(7):266-271.
2. Low DW. Hemangiomas and vascular malformations. *Sem Ped Surg* 1994; 3(2):40-61.
3. Silverman RA. Hemangiomas and vascular malformations. *Ped Derm* 1991; 38(4):811-833.
4. Filston HC. Hemangiomas, cystic hygromas, and teratomas of the head and neck. *Sem Ped Surg* 1994; 3(3):147-159.

# Branchial Cysts, Sinuses and Fistulas

*Daniel A. Bambini*

## Incidence

The exact incidence of branchial remnants in children is not known but these lesions occur less commonly than thyroglossal duct cysts and slightly more commonly than cervical vascular or lymphatic malformations. Second branchial remnants and cysts are much more common than those of first branchial origin. Lesions derived from the lower branchial apparatus are extremely rare.

## Etiology

All branchial cysts, sinuses or fistulae are congenital lesions arising from defective development of the branchial apparatus. The branchial apparatus is identifiable in the 4-8 week old human embryo as a series of 6 branchial arches with intervening clefts (ectodermal) and pouches (endodermal). There is normally no communication between the clefts and pouches in the human embryo which are separated by pharyngeal membranes. Many of the final structures of the head and neck are all derived from the branchial arches, clefts and pouches. Branchial fistulas occur when there has been breakdown or abnormal development of the pharyngeal membranes.

Defects in first branchial arch development result in cleft lip/palate deformities, abnormally shaped external pinna, and malformation of the malleus and incus (deafness). Aural atresia and microtia result from failure of the first branchial cleft to develop normally. First branchial cysts and sinuses/fistulae occur near or behind the anterior border of the upper third of the sternocleidomastoid, under the angle of the jaw, or just below the ear. Sinuses or fistulae of first branchial origin extend from an external opening at the posterior submandibular triangle to the external auditory canal. Complete fistulas with an opening at the external auditory canal only occur in 30% of these rare cases. The tract courses very near the facial nerve.

Second branchial defects are most often complete fistulas. The second branchial fistula opens externally along the lower third of the anterior border of the sternocleidomastoid. The tract ascends from this opening along the platysma and courses along the carotid sheath, over the hypoglossal and glossopharyngeal nerves passing between the bifurcation of the carotid artery. The tract passes behind the posterior digastric and stylohyoid muscles and opens on the lateral pharyngeal wall at the level of the tonsillar pillar. Cysts and/or cartilaginous remnants of second branchial pouch or cleft origin occur along the same tract. These cysts may or may not have an associated sinus tract.

Third and fourth branchial anomalies occur extremely rarely and usually occur in the left neck. The external opening of third branchial abnormalities would be expected along the anterior edge of the sternocleidomastoid at the level of the clavicle. The tract passes posterior to the internal carotid artery and then superior to the adjacent 11th cranial nerve to connect with the piriform sinus. Fourth branchial anomalies also would have an opening at the lower neck and a tract extending posterior to the sternocleidomastoid, inferior to the subclavian artery (right) or aortic arch (left), and then cephalad toward the cervical esophagus.

### Clinical Presentation

Second branchial fistulas are more likely to present in the neonate but the external skin opening often goes unnoticed. The parent may first notice a mucoid drainage from the external opening or the area may present as a localized infection. Infection is less common in fistulas and sinus tracts than in cysts. Branchial cysts often go unnoticed until later childhood or adolescence/early adulthood and present as gradually enlarging masses along the anterior border of the sternocleidomastoid. Approximately 10-15% of branchial remnants occur bilaterally. There may be a family history of similar branchial anomalies in 10% of these children. Twenty-five percent of branchial cysts initially present with signs of acute inflammation including tenderness and erythema.

First branchial cysts present as swellings near the ear lobe within the submandibular triangle in children of all ages. There is often a history of recurrent infections and either spontaneous or surgical drainage. These lesions are in close proximity to the parotid gland and underlying facial nerve.

In addition to cysts and/or sinus tracts, these anomalies may include ectopic cartilage and/or skin tags.

### Diagnosis

The diagnosis of branchial remnants including cysts, fistulas, sinuses, tags and cartilage is made by physical exam and history. The location of each lesion is fairly typical. The differential diagnosis of branchial cysts and remnants is that of the lateral neck mass in children. The differential diagnosis of first branchial remnants includes cat scratch disease and other causes of cervical lymphadenitis such as tuberculosis, atypical mycobacterium, histoplasmosis and actinomycosis. Preauricular cysts or sinuses (Fig. 18.1), although in a similar location, are usually anterior to the ear and are not of branchial origin.

Second branchial anomalies must be distinguished from lymphangioma, lymphadenitis, atypical mycobacterium infection, malignant lymph nodes, dermoids, parotid lesions, tumors of the sternocleidomastoid and/or torticollis, cat scratch disease, actinomycosis and hemangioma. The differential diagnosis of first branchial abnormalities. Mycobacterium stains, immune titers, skin testing and cultures may all be useful to exclude these other possibilities. Ultrasonography is occasionally useful to distinguish neck masses as cystic or solid and determine precisely the relation between lesions and the surrounding vital structures of the neck.

### Pathology/Pathophysiology

The tissue lining branchial remnants and cysts is the same for both first and second branchial derivatives. Ninety percent are lined with stratified squamous

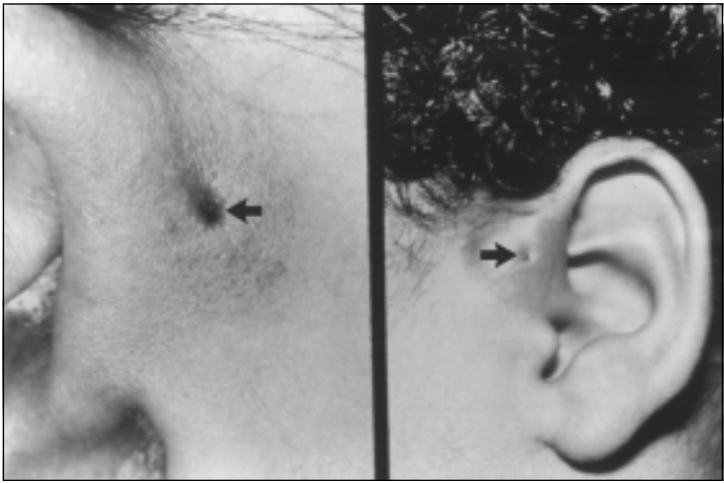

Fig. 18.1. Typical appearance of preauricular pits.

epithelium, but columnar epithelium with or without cilia is possible. Skin appendages are sometimes present as are acute and chronic inflammatory changes when infection has occurred.

### Treatment

All branchial remnants should be completely excised prior to infection. Branchial sinuses require excision to prevent recurrent infection and chronic drainage. Acute infections of branchial cysts are treated with incision and drainage, antibiotics and warm compresses. Excision is performed after the acute inflammatory response has subsided. Second branchial cysts, sinuses or fistulas must be resected with caution to avoid injury to the glossopharyngeal nerve and carotid artery. The facial nerve must be carefully identified and preserved when first branchial remnants are excised. Nerve injury is best avoided by dissecting as close to the tract as possible during the resection.

### Outcome

Recurrence is rare unless the epithelialized tract is not completely excise. Previous infection increases the risk of recurrence. Neoplastic degeneration of branchial remnants can occur and is another reason for early, complete resection.

### Selected Readings

1. Telander RL, Deane SA. Thyroglossal and branchial cleft cysts and sinuses. *Surg Clin North Am* 1977; 57:779.
2. Smith CD. Cysts and sinuses of the neck. In: O'Neill Jr. JA et al, eds. *Pediatric Surgery*, 5th Edition. St. Louis: Mosby 1998; 757-772.

# Thyroglossal Duct Cyst and Sinus

*Daniel A. Bambini*

## **Incidence**

Thyroglossal duct cysts or remnants are the most common midline cervical mass of childhood. While the exact incidence is difficult to estimate, they occur 3 times more commonly than branchial remnant cysts and sinuses. The sex incidence is approximately equal.

## **Etiology**

In the normal embryo, the thyroid anlage develops as an endodermal thickening that creates a diverticulum in the floor of the pharynx between the first and second pharyngeal grooves. Initially the developing thyroid is in close contact with the developing aortic arch. As the embryo elongates, the thyroid diverticulum descends in the anterior neck in close proximity to the developing hyoid bone. A connection to the foramen cecum at the base of the tongue persists as the thyroglossal duct until the thyroid attains its final position in front of the trachea. The upper portion of the thyroglossal duct then disappears during the 5th week of intrauterine life, however the lower portion of the duct may persist as the pyramidal lobe of the thyroid. If all or part of the thyroglossal duct persists beyond fetal life, a cyst or sinus tract can develop.

## **Clinical Presentation**

Thyroglossal duct cysts are rarely present at birth. Two thirds of thyroglossal duct cysts will become clinically apparent in childhood; the majority appearing by 2-6 years of age. The most common presentation is an asymptomatic midline cervical mass with normal overlying skin (Fig. 19.1). Less than 1% will be lateral to midline. Occasionally the cyst can become infected with mouth flora, leading to spontaneous or even surgical drainage. A chronic draining sinus tract may develop.

Physical examination most commonly reveals a nontender, unilocular, rounded firm mass at or near the hyoid bone. However, it can occur anywhere in the midline of the neck between the base of the tongue and the thyroid gland. The mass may be tender if the cyst is infected. The mass, which is tethered to the hyoid, will move in the vertical axis as the patient swallows. The mass will also move with protrusion of the tongue.

The differential diagnosis includes ectopic thyroid, pyramidal lobe of thyroid, dermoid or sebaceous cyst, lymphadenitis, thyroid goiter and lipoma.

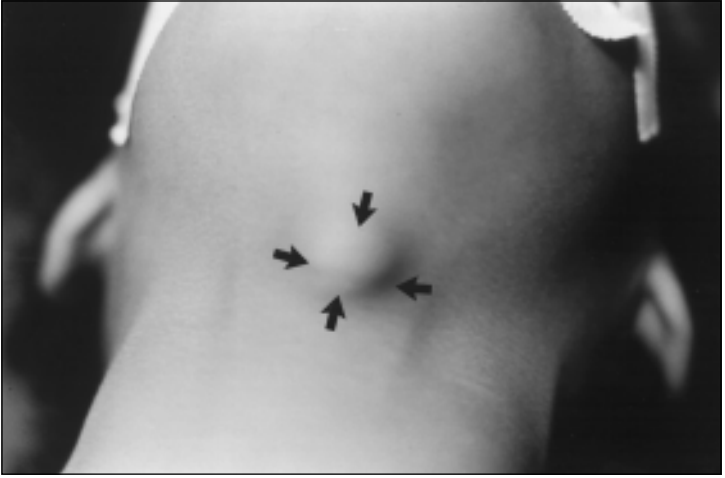

Fig. 19.1. Midline neck mass over hyoid bone characteristic of thyroglossal duct cyst (other common lesion in this location is a midline dermoid cyst).

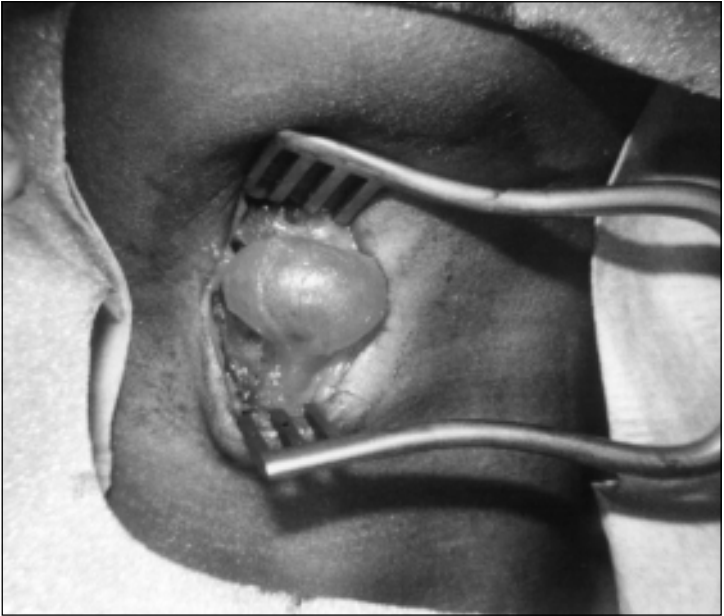

Fig. 19.2. Thyroglossal duct cyst as visualized at the time of surgical excision which includes resection of the central portion of the hyoid bone (Sistrunk procedure).

## Diagnosis

The diagnosis of thyroglossal duct cyst is made primarily on the basis of physical findings. Rarely, if midline ectopic thyroid cannot be excluded, thyroid scan or aspiration biopsy may be helpful. Dermoid cysts are superficial lesions that remain attached to the dermis and are easily distinguished from thyroglossal duct cysts during excisional biopsy.

## Pathology

The majority of thyroglossal duct cysts are lined by psuedostratified ciliated columnar or stratified squamous epithelium. Twenty percent will contain some recognizable thyroid tissue. Chronically infected cysts and sinuses may be composed mostly of granulation tissue or fibrous tissue.

## Treatment

Treatment of a thyroglossal duct cyst is by complete excision of the cyst and its tract. Resection should include the central portion of the hyoid bone and complete excision of the tract to the base of the tongue (Sistrunk procedure). Thyroglossal duct cysts should be removed shortly after discovered and before infection occurs. Infected cysts should be treated with antibiotics and aspiration or drainage with surgical excision delayed until local inflammation subsides. Postoperative care is outpatient and if a drain is used, it is removed at 24-48 hours.

## Outcomes

Recurrence is infrequent (< 5%) if the central portion of the hyoid bone is resected en bloc. In the past, over 95% of recurrent cases were associated with failure to resect the central hyoid bone. The risk of recurrence following resection of a previously infected or drained thyroglossal duct cyst is increased by 50%. Malignant degeneration can occur in thyroglossal duct remnants which may give rise to adenocarcinoma or squamous carcinomas later in life.

## Selected Readings

1. Sistrunk WE. Technique of removal of cyst and sinuses of the thyroglossal duct. *Surg Gynecol Obstet* 1928; 46:109-112.
2. Soper RT, Pringle KC. Cysts and sinuses of the neck. In: Welch K, et al, eds. *Pediatric Surgery*, 4th edition. Chicago: Year Book Medical Publishers 1986; 539-551.
3. Tapper D. Head and neck sinuses and masses. In: Holder TM, Ashcraft KW eds. *Pediatric Surgery*, 2nd Edition. Philadelphia: WB Saunders 199; 923-934.



# Umbilical Anomalies

*Daniel A. Bambini*

Disorders of the umbilicus are not unusual in newborns and infants. In this Chapter, the common anomalies of the umbilicus are discussed including omphalomesenteric (vitelline) duct remnants, urachal remnants, and umbilical hernia. Omphalocele and gastroschisis, which also involve the umbilicus, are defects of the abdominal wall and are discussed in Chapter 77.

## Incidence

Umbilical disorders are frequently encountered in pediatric patients. Umbilical hernia is probably the most common hernia in children and occurs in about 40% of African-American children and in 3-4% of Caucasian children. It is more common in premature infants. Urachal remnants are fairly uncommon affecting approximately one of every 5000 newborns. Omphalomesenteric remnants are less rare lesions. Meckel's diverticulum (Chapter 55) is the most common and is identifiable in 1-2% of all autopsies while a patent omphalomesenteric duct affects 1 in 15,000 live births.

## Etiology

Some disorders of the umbilicus arise from the persistence of normal fetal structures (i.e., omphalomesenteric duct, urachus). Early in gestation, the embryo is connected to the chorion (developing placenta) by a connecting stalk of extraembryonic mesoderm. The omphalomesenteric duct connects the extraembryonic coelom to the intestine (ileum) and normally obliterates and involutes by the sixth week of gestation. Incomplete obliteration can result in variety of omphalomesenteric defects (see below). The urachus is a tubular, fetal structure that connects the developing urinary bladder to the allantoic stalk. Later in gestation, the urachus also obliterates to form the median vesico-umbilical ligament. Urachal remnants can persist if the obliterative process is incomplete but may also occur in association with obstructive lesions of the distal urinary tract (i.e., urethral stenosis, urethral atresia, posterior urethral valves). Umbilical hernias result from failed closure of the facial ring at the umbilicus.

## Clinical Presentation, Diagnosis, and Treatment

### *Omphalomesenteric Duct Defects*

The five omphalomesenteric duct defects are:

1. Meckel's diverticulum (in which the proximal duct has remained patent,

2. umbilical polyp with blind pouch (in which the distal duct has remained patent),
3. vitelline duct cyst (midportion of duct has remained patent),
4. patent omphalomesenteric duct, and
5. persistent fibrous cord. Although the clinical presentation varies with the specific lesion present, all except the persistent fibrous cord present with symptoms specific to the umbilicus. If the omphalomesenteric duct persists as a fibrous cord or band, it can act as a fulcrum for midgut volvulus or herniation of a loop of bowel between the band and the abdominal wall. The clinical picture in this case is intestinal obstruction and/or volvulus.

The patent omphalomesenteric duct (POD) is present from birth but is often (40%) not noticed until the infant is beyond one month of age. Boys are affected more than girls at a ratio of about 7:1. The symptoms are usually drainage of foul-smelling material, bowel contents, feces, or gas from the umbilicus. Inspection of the umbilicus in children with POD or umbilical polyp reveals a "rosette" of pink, bowel mucosa at the umbilical surface. If the omphalo-ileal fistula is large and wide, the ileum can prolapse through it. Vitelline duct cysts frequently present with signs of infection including purulent umbilical drainage and periumbilical erythema, induration, and tenderness. A mass deep to the umbilicus is occasionally palpable. The differential diagnosis includes urachal remnants and umbilical granuloma. Abdominal x-ray with contrast administered via the umbilical opening may show communication with the intestine confirming the diagnosis and excluding the possibility of a urachal lesion. The treatment of patent omphalomesenteric duct, umbilical polyp, and vitelline duct cyst is complete surgical resection and umbilical reconstruction.

### *Urachal Remnants*

Urachal remnants are classified into five distinct groups:

1. completely patent (communicates between umbilical surface and bladder),
2. urachal sinus (opens to umbilical surface),
3. urachal diverticulum (opens to bladder),
4. urachal cyst, and
5. urachal chorda (persists as a cord). Urachal remnants are often lined by transitional epithelium but are frequently composed primarily of granulation tissue.

Children with urachal remnants most frequently present in infancy and early childhood, but rarely present in the neonatal period. The usual presenting symptom in infants with a persistent patent urachus is a report of a thin, watery discharge from the umbilicus. Mucosal prolapse may be visible. The other urachal remnants most commonly present as infection with erythema and purulent drainage from the umbilicus. Low midline abdominal mass and pain are sometimes the presenting features.

The diagnosis of urachal cyst is most commonly confirmed by ultrasound that also determines its size, its relation to the umbilicus and bladder, mobility, and its location within the abdominal wall. Cystoscopy is helpful to identify urachal diver-

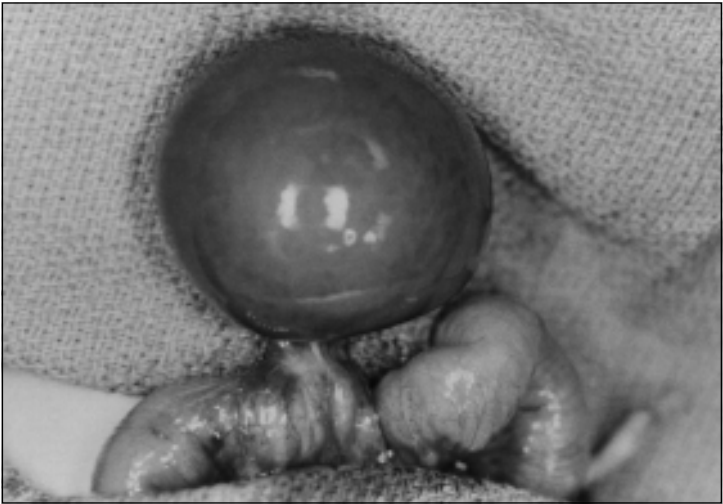

Fig. 20.1. Meckel's diverticulum with large omphalomesenteric cyst at the distal tip.

ticula. Fistulogram if an umbilical puncta is present demonstrates a completely patent urachus or urachal sinus. The differential diagnosis includes the various forms of omphalomesenteric duct remnants, umbilical granuloma, and a variety of inflammatory intra-abdominal processes.

Treatment of these lesions depends on the exact type of remnant and the extent of associated infection and/or inflammation. Urachal fistulas, cysts, and diverticula should be completely resected. Urachal diverticula of the bladder are associated with high risk for chronic urinary tract infection, stone formation, and malignancy. Infected urachal remnants are initially treated with broad-spectrum antibiotics (7-10 days) followed by resection. In some cases, initial incision and drainage may be preferable. Complete resection is then performed after the acute inflammatory reaction subsides.

### *Umbilical Hernia*

Umbilical hernias are present at birth when the fascial ring of the umbilicus has not completely closed. Eighty-five percent of umbilical hernias will close spontaneously by 6 years of age. The diagnosis is made simply by clinical observation. The hernia wall consists of skin and underlying peritoneum and bulges with increases in intra-abdominal pressure. Depending upon the size of the hernia, bowel loops may be contained within it. The size of the fascial defect is variable.

Most surgeons wait until the child is at least 4-5 years of age prior to repair to allow adequate time for spontaneous closure (85%). Hernias with especially large fascial defects may be an exception to the wait-and-see approach as they are less likely to close spontaneously. Complications of pediatric umbilical hernia repair are infrequent. Infection and hematoma are the most prevalent but occur in less than 2% of cases.

## Outcomes

Recurrence after complete resection of noninfected omphalomesenteric or urachal remnants is extremely uncommon. The recurrence rate after resection of infected urachal cysts is near 30%. Urachal remnants have the potential for malignant degeneration to adenocarcinoma or transitional cell carcinoma based on a few case reports but the frequency of this occurrence is not truly established.

### *Selected Readings*

1. Jona JZ. Umbilical anomalies. In: Raffensperger JG ed. Swenson's Pediatric Surgery, 5th Edition. Norwalk: Appleton & Lange 1991; 189-198.
2. Shaw A. Disorders of the umbilicus. In: Welch KJ, Randolph JG, Ravitch MM et al, eds. Pediatric Surgery, Fourth Edition. Chicago: Yearbook Medical 1986; 731-739.
3. Rich RH, Hardy BE, Filler RM. Surgery of the anomalies of the urachus. J Pediatr Surg 1983; 18:370-372.
4. Lassaletta L, Fonkalsrub EW, Toward JA et al. The management of umbilical hernias in infancy and childhood. J Pediatr Surg 1975; 10:405.
5. Haller Jr. JA, Morgan Jr. WW, Stumbargh S. Repair of umbilical hernias in childhood to prevent adult incarceration. Am Surg 1971; 37:245.

# Foreign Bodies of the Gastrointestinal Tract

*John R. Wesley*

## **Incidence**

We have no idea of how many gastrointestinal foreign bodies are ingested annually. It is probable that most children accidentally swallow a foreign body that passes undetected sometime during childhood. However, the National Safety Council estimates that approximately 2,000 people in the United States die each year from the complications of inhaled or ingested foreign bodies. Fatal accidents in the home comprise the majority of this total, and over half of these involve children newborn to age 5 years. Foreign bodies in the tracheal-bronchial tree and esophagus are covered in Chapter 74. The present Chapter deals with diagnosis and management of foreign bodies of the stomach, intestine, rectum, and genital-urinary tract.

## **Etiology**

Infants and children, as a normal part of immature, exploratory activity, or because of curiosity and their developmental need to taste new objects, place a variety of foreign bodies into their mouths or other orifices. These include small toys, eating utensils, pen tops, peanuts, cocktail hot dogs, other chunky or particulate foods, batteries, coins, pins, buttons, screws, ornaments, bones, and beads. If the child is startled, falls, or simply becomes distracted, the foreign body is swallowed.

As with esophageal and intestinal foreign bodies, objects in the rectum are due to both unintentional and intentional actions. In general, the only object commonly found in the rectum of children is a thermometer secondary to squirming while a rectal temperature is taken. Other foreign objects are nearly always a consequence of sexual behavior that is either auto-erotic or performed by a playmate, older child, or adult bent on sexual abuse. In most cases, these rectal foreign bodies have a phallic shape and include bottles, hot dogs, zucchini, broomsticks, and light bulbs. Foreign bodies of the vagina or penile urethra frequently occur as a result of children playing "doctor" or as a result of the desire to satisfy dares by "friends". The types of objects are sometimes imaginative but generally possess a long and thin shape such as pipe cleaners, pens, pencils, metal springs, paper clips, screws, sticks and leaves, paint chips, and swizzle sticks. In younger girls, early exploration and genital stimulation frequently lead to vaginal insertion of foreign objects including toilet paper, toys, or other small, rounded objects.

## Diagnosis

A careful history is the keystone to making the correct diagnosis. Children under the age of 2 years are usually accompanied by a responsible adult who has witnessed an acute choking episode or the swallowing of a now missing object. Children between the ages of 2 and 8 years are not constantly under adult supervision, and an acute choking episode or ingestion of an object may pass unobserved. Children beyond the age of 8 years can usually be relied upon to accurately describe the choking episode, report ingestion of an object, and understand their significance. Following the initial suspicious incident, there is often a symptom-free interval. Once objects reach the stomach or intestine, they cause only vague or intermittent symptoms or cause no further symptoms at all.

## Treatment

### *Gastrointestinal Foreign Bodies*

Once in the stomach, 95% of all ingested foreign bodies pass safely through the gastrointestinal tract and exit without difficulty, usually within 24-48 hours. The size, shape, and characteristics of the object dictate initial management: either continued observation or efforts at immediate retrieval.

In general, round or cuboidal objects without sharp edges or projections pass through the stomach and intestine easily causing little difficulty and concern. Objects of this type most commonly include coins, buttons, marbles, closed safety pins, and small toys (Fig. 21.1) These patients need no hospitalization but should return if they develop abdominal pain, vomiting, bloody stools, or if the object has not been identified in the stools in 4-5 days. Roentgenograms document the progress of the object, or whether it has passed unnoticed. Surgical removal is indicated for continued abdominal pain, vomiting, significant bleeding, or failure of the object to pass in 4-5 weeks.

Of greater concern are those patients who have swallowed elongated, slender, yet relatively blunt objects. These include pencils, pens, bobby pins, long nails, small tools, and chicken bones. Although most of these pass without difficulty, failure of passage is highest in this category. Problems occur at fixed points or sites of anatomical narrowing or angulation such as the pylorus, the C-loop of the duodenum, the ligament of Treitz, and the ileocecal valve. The rigid nature of the object makes it difficult to negotiate these areas. The ends of the objects, even though not sharply pointed, may impinge on the bowel wall causing damage or perforation. These patients may be admitted to the hospital or observed carefully as outpatients. Progress of the object is followed by serial roentgenograms (Fig. 21.2) Operative removal is indicated if significant abdominal pain, tenderness, or bleeding is present, or if the object fails to change position.

Of greatest concern are those patients who have swallowed foreign bodies with sharp edges or points. These include pins, needles, tacks, jacks, open safety pins and pieces of glass. Such a patient should be hospitalized and followed carefully, with daily roentgenograms to monitor the progress of the object and frequent physical examinations for tenderness. The patient's stools are strained for the object and tested for blood. Abdominal pain, tenderness, elevated temperature, and rectal bleeding are warning signals, but continued progress of the foreign body is still a good




Fig. 21.1. Examples of foreign bodies commonly swallowed or aspirated by children.

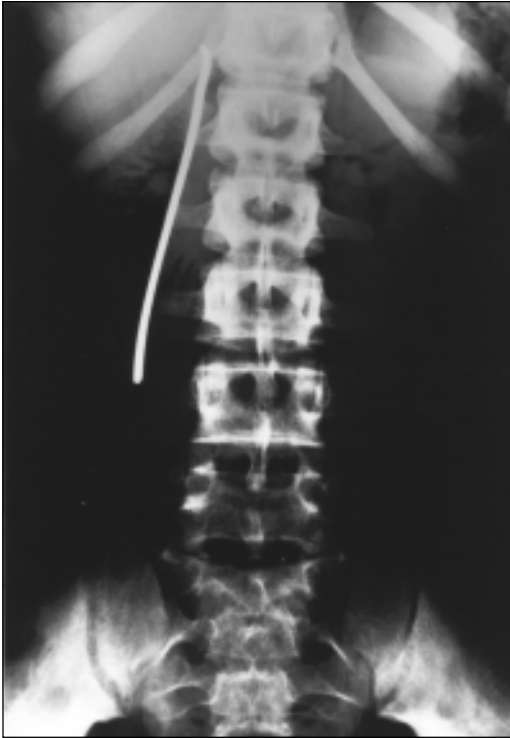


Fig. 21.2. Spoon handle swallowed by a retarded child; passed without difficulty in 3 days.

reason for nonoperative management. Surgical intervention is reserved for patients with significant bleeding or signs of peritonitis. Operation is also indicated when the object has failed to move over several days. Fortunately, most straight pins, needles, and open safety pins will pass uneventfully.

Finally, battery ingestion poses a special problem, and is becoming increasingly more common as "button-size" batteries in watches, hearing aids, cameras, and calculators are more accessible to the pediatric population (Fig. 21.3). Because batteries may leak or burst within 24 hours of ingestion and cause corrosive alkali burns or poisoning from mercuric salts, they are removed endoscopically while still in the stomach. Once they have passed into the duodenum, they are removed surgically if they do not progress rapidly through the intestine as indicated by roentgenograms taken at 6-hour intervals. Intestinal perforation has been reported from a small battery lodged in a Meckel's diverticulum, and death in a 16-month old infant from corrosive esophageal perforation has followed ingestion of an alkaline battery. Dietary aids to protect mucosa and help passage are generally not effective and not recommended. An exception is the use of mineral oil to possibly aid the passage of a particularly bulky object. Cathartics are always contraindicated.

### *Rectal, Penile, and Vaginal Foreign Bodies*

A few but nevertheless surprising number of objects find their way into the rectum of teenagers and young adults. Dildos, coke bottles, light bulbs, and umbrellas have been removed (Fig. 21.4) and there are undoubtedly other equally surprising objects that go unreported. The basic tenant in dealing with these situations is to expect the unusual. Pain, bleeding, obstipation, and embarrassment usually bring the patient to the emergency room. The history is either unbelievably scant, or inappropriately complex, and frequently associated with sexual experimentation, hazing, and alcohol intoxication. Sigmoidoscopy with rectal lubrication and dilatation is the keystone to extraction. Occasionally a light general anesthetic is required. Perforation may require a temporary diverting colostomy.

A variety of small elongated objects have been reported in the penile urethra including pipe cleaners, thermometers, and swizzle sticks (Fig. 21.5). The same historical and etiological factors hold true as described for rectal foreign bodies. A pelvic roentgenogram will demonstrate the object. Cystoscopy is generally required for removal.

Vaginal foreign bodies should be considered whenever evaluating a prepubertal girl with lower genital tract symptoms. An intermittently bloody, foul-smelling vaginal discharge is the classic complaint of the patient with a vaginal foreign body. Small wads of toilet paper are the most common foreign bodies, but objects such as pencil erasers, pins, beads, nuts and leaves are also found. Physical examination is best carried out with the child in the knee-chest position unless anesthesia is required. Gentle vaginal lavage with saline solution can remove bits of toilet paper. In general, small objects can be most easily palpated on rectal examination and removed if the examiner places his finger in the rectum and then applies gentle outward pressure. However, if the object is large or sharp, or simple maneuvers fail, the patient will require examination and removal of the foreign body under general anesthesia.

A forgotten tampon is the most common intravaginal foreign body in menarchial females. Obviously the patient's age and hormonal status should be considered





Fig. 21.3. Examples of ingestible batteries with dime to indicate relative sizes.

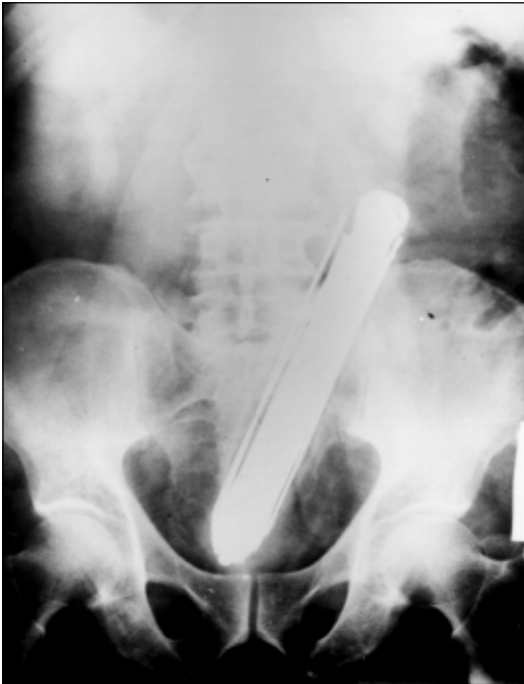

Fig. 21.4. Umbrella inserted into the rectum under obscure circumstances. Reprinted with permission from Davenport HW. *Physiology of the digestive tract*, 3<sup>rd</sup> edition. Chicago: Year Book Medical Publishers, 1971.

first in the differential diagnosis of vaginal discharge. Although physicians are often reluctant to raise the question, every child with genital complaints (and his/her parents) should be asked directly whether there is a possibility of any sexual contact or sexual abuse. If the history provides few diagnostic clues, then the physical examination and cultures will be the physician's best guide to proper management.

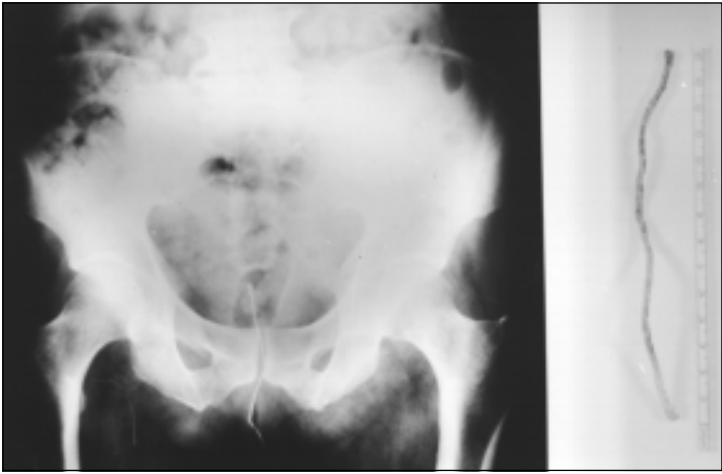


Fig. 21.5. A pipe cleaner inserted into the penile urethra removed by cystoscopy.

### Prevention

The best approach to the management of foreign bodies is prevention. Children are great imitators who frequently see adults holding pins, needles, or nails in their mouths or talking, laughing, and walking around while eating—all practices that should be condemned. Infants and children under the age of 5 should be denied access to buttons, screws, coins, beads, pins, small toys, and jewelry. All toys should be inspected for loose parts, and bean shooters, dart guns, and similar playthings should be prohibited. All nuts, seeds, carrots, and popcorn should be withheld from the diet of children under the age of 4 years. Food for children should never contain small bones; cherry, plum, prune, or peach pits; watermelon, orange, or grape seeds; or stems from fruits. Physicians should be alert for loose deciduous teeth prior to any surgery. When foreign body aspiration or ingestion does occur, an understanding of the principles of management and a willingness to move ahead swiftly with the appropriate therapy greatly reduces the mortality and morbidity of this common health problem.

### Selected Readings

1. Kosloske AM. Foreign bodies. In: Buntain, WB, ed. *Management of Pediatric Trauma*. Philadelphia: W.B. Saunders Co. 1995; 459-477.
2. Wesley JR: Management of foreign bodies in various orifices. Part I: Etiology and Foreign bodies of the ears, nose, larynx, trachea, bronchi, and esophagus. *Emer Med Rep* 1984; 14:101-108.
3. Wesley JR: Management of Foreign bodies in various orifices. Part II: Foreign bodies of the intestine, rectum, urethra, vagina, and prevention. *Emer Med Rep* 1984; 15:109-116.
4. Temple DM, McNeese MC. Hazards of battery ingestion. *Pediatr* 1983; 71:100-103.
5. Paradise JE. Vaginal discharge. In: Fleisher G, Ludwig S eds. *Pediatr Emer Med*. Baltimore: Williams and Wilkins 1983; 262-265.

# Hypertrophic Pyloric Stenosis

*Richard Fox and Daniel A. Bambini*

## Incidence

Hypertrophic pyloric stenosis (HPS) is a disease of newborns with an incidence of 1 in 300 to 1 in 900 live births. It is most commonly identified in Caucasians of northern European descent. Throughout the world, HPS appears to be less common in Africans, African Americans, and Asians. HPS is more common in infants with blood types B and O. Seasonal variation in the incidence of HPS has been reported; more infants present during the spring and fall months.

Although a genetic predisposition to HPS is suspected, the exact mode of inheritance is unknown. Males are affected four times as often as females, and first born males are at highest risk. Family history is relevant. When parents (mother or father) have had HPS it occurs in 5-20% of their male children but in only 3-7% of their female children. Children whose mothers had HPS develop pyloric stenosis 3-4 times more frequently than children whose fathers had HPS. Finally, monozygotic twins are more likely to be concordant for HPS than are dizygotic twins.

## Etiology

Despite extensive clinical and laboratory research, the cause of pyloric stenosis remains unknown. Researchers have investigated the role of many factors (i.e., ganglion cells, maternal factors, gastric acidity, nutritional factors, prostaglandins, nitric oxide, hypergastrinemia, etc.) suspected as contributors to pyloric muscle hypertrophy, yet no conclusive etiology has been described.

## Clinical Presentation

Infants with HPS generally present between the second or third week of life to two months of age. Rare cases have been reported throughout childhood and into adult life. Symptoms begin as mild regurgitation that gradually progresses to nonbilious vomiting. With time, the emesis becomes more frequent and forceful (i.e., "projectile"). Infants are generally consolable and hungry after vomiting episodes. In 3-5% of cases, the vomitus will be brown or even bloody secondary to an associated esophagitis/gastritis.

In HPS, dehydration, weight loss, and failure to thrive are the result of uncorrected fluid losses and inadequate nutrition caused by a nearly complete gastric outlet obstruction. Gastric secretions contain significant quantities of potassium, hydrogen ion, and chloride. Although the kidney can initially compensate for mild electrolyte losses, with prolonged emesis and dehydration, a hypokalemic,

hypochloremic, metabolic alkalosis develops. Indirect hyperbilirubinemia is observed in 1-2% of patients and is caused by a decrease in hepatic glucuronyl transferase probably as a consequence of starvation.

Physical examination often reveals a hungry child with signs of dehydration (i.e., sunken fontanelles, pale mucosal membranes, poor skin turgor, lethargy, hypotonicity, poor capillary refill). Visual inspection of the abdomen may reveal peristaltic waves traversing from left to right across the upper abdomen. Nasogastric or orogastric decompression of the stomach offers symptomatic relief and empties the stomach of retained formula/milk and mucous facilitating palpation of a hypertrophied pylorus ("olive"). A meal of sugar water can be administered to satiate the crying infant. As the child relaxes, palpation of the pyloric mass is often easier.

The differential diagnosis of HPS is extensive and includes all causes of nonbilious emesis in the neonate. Anatomic anomalies that mimic pyloric stenosis include duodenal stenosis, antral/pyloric webs or duplications (those 10-15% with obstruction proximal to the ampulla of Vater). Functional problems in the differential include gastroenteritis, gastroesophageal reflux with/without hiatal hernia and achalasia. The metabolic differential includes congenital adrenal hyperplasia (CAH) and inborn errors of metabolism. Intracranial pathologies, including intracerebral bleeding and hydrocephalus are also associated with "projectile" vomiting.

## Diagnosis

The hypertrophied pylorus ("olive") is palpable on clinical exam in about 75-90% of infants with HPS. If the "olive" cannot be felt or the diagnosis is in doubt, an abdominal ultrasound is beneficial. A pyloric muscle thickness greater than 4 mm or pyloric channel length greater than 14mm confirms the diagnosis. Ultrasonographic detection of pyloric stenosis has a false negative rate of 5-10%. If ultrasonography is nondiagnostic, an upper gastrointestinal study (UGI) can be performed. UGI may be beneficial to exclude reflux, distal obstruction and malrotation as sources of emesis. The radiographic findings on UGI that suggest HPS include: the "string sign" from the narrowed pyloric channel, the "double track" sign from the folding of the rugal folds, and the pyloric "beak" or "shoulder" signs from the pyloric bulge into the antrum.

## Pathology

Gross pathologic findings include a firm, bulbous pylorus with a smooth and shiny serosal surface (Fig. 22.1). On cut section, the mucosa is pushed inward effectively obliterating the pyloric channel. The lumen of the duodenum attains its full size immediately distal to the hypertrophied pylorus unlike the proximal gastric lumen which demonstrates progressive narrowing. Microscopic examination of the pylorus reveals hypertrophy and hyperplasia of the circular pyloric muscle fibers. Edema and nonspecific inflammatory changes are observed in the mucosa and submucosa.

## Treatment

The mainstay of treatment is surgical pyloromyotomy, a procedure formalized by Ramstedt in 1912. Initial management of infants with HPS includes fluid resuscitation appropriate to the degree of dehydration and severity of electrolyte

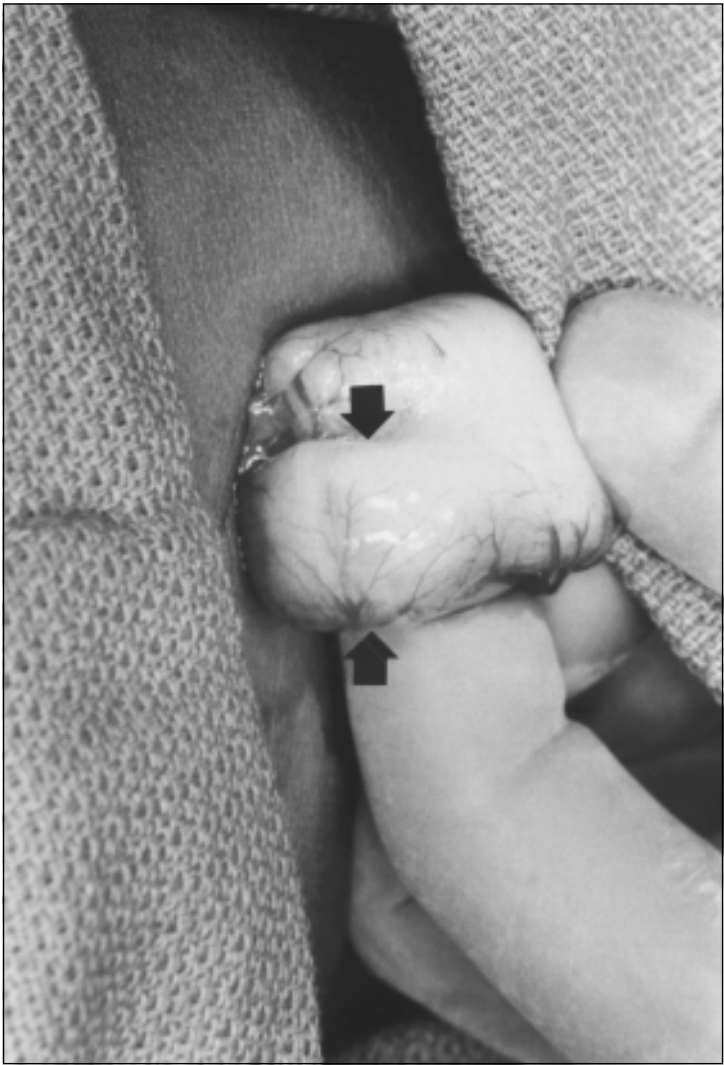

Fig. 22.1. Hypertrophied pyloric muscle characteristic of a neonate with hypertrophic pyloric stenosis.

abnormalities (i.e., hypochloremia, hypokalemia, alkalosis). A typical resuscitation plan includes initial rehydration with normal saline (10-20 cc/kg boluses) until urine output is established, followed by gradual potassium replenishment (i.e., D51/2 NS with 20 meq KCl/l at 1.5-2 times maintenance rate) until electrolyte abnormalities are corrected. Most infants can be operated upon within 24 hours of admission.

Pyloromyotomy is performed under general anesthesia. The traditional incision, as described by Ramstedt, is a transverse right upper quadrant incision. Periumbilical incisions are occasionally used and cosmetically superior, but have higher risk for wound infection. The stomach is identified and the pylorus is delivered through the incision. The hypertrophied pylorus is incised from the gastroduodenal junction proximally to just beyond the extent of the tumor, being careful not to violate the duodenal or gastric mucosa. The incised muscle is split further by dividing the remaining circular muscle fibers using the blunt edge of a knife handle or other spreading device. The intact mucosa bulges between the divided muscle edges. The divided pylorus is grasped on each side of the pyloromyotomy and gently manipulated to and fro to confirm complete separation of the muscle fibers. The pylorus is replaced into the abdomen after the mucosa is closely reinspected for leak or bleeding.

Feeding is started 6-8 hours postoperatively. A pyloric feeding regimen is used to gradually initiate and advance enteral intake. Most regimens begin with sugar water followed by increasing concentrations and volumes of the child's formula. Occasionally, infants will continue to have small amounts of emesis when feedings are initiated postoperatively. Parents should be forewarned and reassured regarding this potential, usually self-limited, postoperative problem. The feeding volume is advanced every few hours. The infant is discharged when po intake is adequate to maintain hydration and meet estimated nutritional needs.

### Outcomes

Infants tolerate pyloromyotomy very well. Average hospital length of stay is 1-3 days. Overall mortality is approximately 0.3%. Two uncommon complications of pyloromyotomy are gastric/duodenal perforation and incomplete separation of muscle fibers. Although perforations are easily repaired at the time of surgery, an unrecognized duodenal perforation is a devastating complication presenting as diffuse peritonitis and/or intra-abdominal abscess. Incomplete pyloromyotomy results in prolonged postoperative feeding intolerance. Recurrence of HPS is extremely rare.

### Selected Readings

1. Ramstedt C. Zur Operation der angelorenen Pylorus Stenose. *Med Klinik* 1912; 8:1702.
2. Schwartz MZ. Hypertrophic pyloric stenosis. In: O'Neill Jr. JA et al, eds. *Pediatric Surgery*, 5th edition. St. Louis: Mosby 1998; 1111-1117.
3. Benson CD, Lloyd JR. Infantile pyloric stenosis: a review of 1120 cases. *Am J Surg* 1964; 107:429-433.

# Intussusception

*Vinh T. Lam*

## Incidence

Intussusception primarily affects infants and toddlers, although it can also occur prenatally or during the neonatal period. Intussusception rarely occurs in adults. The estimated incidence in the United States is about 1.5-4 cases per every 1,000 live births. Males are affected more than females at a ratio of 3:2. Male predominance is even greater in the 6-9 month age group.

Incidence peaks during two seasons of the year: spring/summer and middle of winter. This seasonal variation correlates with times of increased number of cases of viral gastroenteritis and upper respiratory infection.

## Etiology

Intussusception is most commonly idiopathic and no anatomic lead point can be identified. Several viral gastrointestinal pathogens (rotavirus, reovirus, echovirus) may cause hypertrophy of the Peyer's patches of the terminal ileum which may potentiate bowel intussusception. Ileocolonic intussusception is the most common type of intussusception in children (Fig. 23.1).

A recognizable, anatomic lesion acting as a lead point is only found in 2-12% of all pediatric cases. The most commonly encountered anatomic lead point is a Meckel's diverticulum. Other anatomic lead points include polyps, ectopic pancreatic or gastric rests, lymphoma, lymphosarcoma, enterogenic cyst, hamartomas (i.e., Peutz-Jeghers syndrome), submucosal hematomas (i.e., Henoch-Schonlein purpura), inverted appendiceal stumps, and anastomotic suture lines. Children with cystic fibrosis are at increased risk of intussusception possibly due to thickened inspissated stool.

Postoperative intussusception accounts for 1.5-6% of all pediatric cases of intussusception. Most of these patients develop small bowel intussusception following operations that include retroperitoneal dissection as part of the procedure. Postoperative intussusception (Fig. 23.2) is the most common cause of intestinal obstruction in the first postoperative week.

## Pathology/Pathophysiology

The pathophysiology of the intussusception is that of bowel obstruction and progressive bowel ischemia. As the intussuseptum becomes invaginated within the intussusciens, the bowel wall and mesentery of the intussuseptum is compressed causing venous and lymphatic occlusion, venous stasis, and edema. As the edema

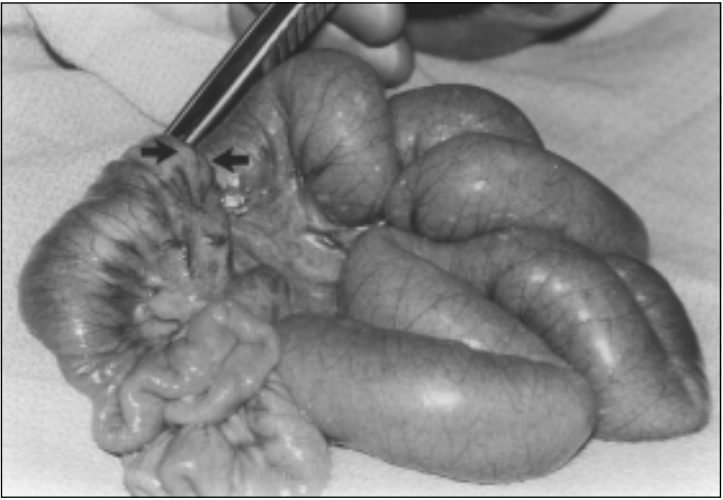

Fig. 23.1. Ileocolonic intussusception (most common form of intussusception) at laparotomy after barium reduction had failed.

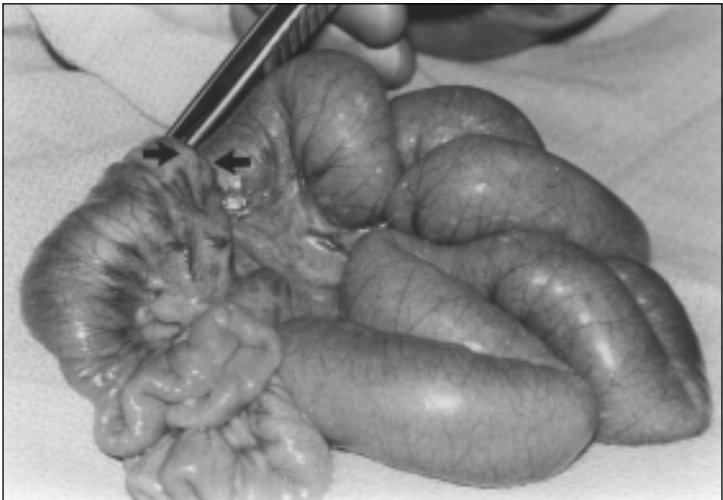

Fig. 23.2. The rather rare enteroenteric intussusception, often the cause of an immediate postoperative obstruction, possibly secondary to disordered peristalsis as the postoperative ileus resolves.



increases and venous outflow becomes obstructed, arterial inflow is compromised. Inadequate perfusion leads eventually to ischemic bowel necrosis.

### Clinical Presentation

Intussusception is primarily a disorder of infancy and occurs most commonly between 5–10 months of age. Two thirds of children with intussusception are less than 1 year of age at presentation. The principle signs and symptoms of intussusception are:

1. vomiting (85%),
2. abdominal pain (83%),
3. passage of blood or bloody mucous per rectum (53%),
4. a palpable abdominal mass, and
5. lethargy. The classic triad of pain, vomiting, and bloody mucous stools (“red current jelly”) is present in only one third of infants with intussusception. Diarrhea may be present in 10–20% of patients.

The abdominal pain of intussusception is frequently acute in onset, severe, and intermittent. During episodes of pain the infant will often draw his/her knees up to the abdomen, scream inconsolably, and become pale and diaphoretic. Between pain episodes, which may last only briefly, the child may be quiet and appear well. With time, the child may become more ill and appear lethargic with increasing abdominal distention, vomiting, and progression to shock with cardiovascular collapse.

Physical exam of the abdomen occasionally identifies a “sausage-shaped” mass at the right upper quadrant or mid-abdomen. The right lower quadrant may feel empty and the cecum may not be palpable in the right iliac fossa (sign of Dance). Rectal exam may reveal a palpable mass if the intussusception has passed far enough distally. Prolapse of the intussusceptum from the anus is a rare event (1–3%). Fever and leukocytosis are common findings. Tachycardia becomes more prominent as hypovolemia ensues.

The differential diagnosis includes intestinal colic, gastroenteritis, acute appendicitis, incarcerated hernia, internal hernia, and volvulus.

### Diagnosis

If the diagnosis is suggested by history and physical exam, several radiographic studies can confirm the diagnosis. Early in the course of the illness, abdominal plain x-ray may show a normal or nonspecific bowel gas pattern. Later, abdominal films will show a more obvious pattern of small bowel obstruction with a relative absence of gas in the colon. In 25–60%, abdominal plain films demonstrate a right upper quadrant soft tissue density that displaces air-filled loops of bowel.

Ultrasonography of the abdomen is a reliable means to identify intussusception. Two ultrasonographic signs of intussusception are:

1. the “doughnut” or “target” sign on transverse views, and
2. the “pseudokidney” sign on longitudinal views.

Barium or air contrast enema is the “gold-standard” diagnostic study for infants with suspected intussusception (Fig. 23.3). It is both diagnostic and therapeutic in identifying and reducing intussusception (see below).

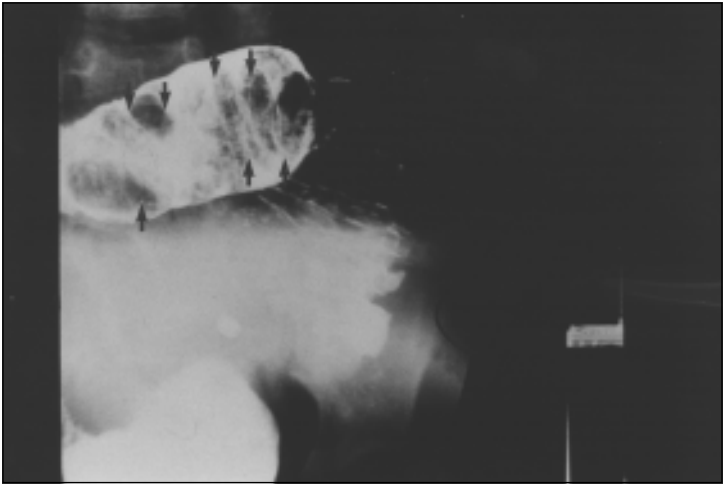


Fig. 23.3. Ileocolonic intussusception within the transverse colon as demonstrated by barium enema.

### Treatment

Once a presumptive diagnosis of intussusception is made, the child should have

1. an intravenous line placed for rehydration,
2. a nasogastric tube placed for decompression, and
3. intravenous antibiotics started. A complete blood count, chemistry panel, and type and screen are obtained.

Hydrostatic barium enema or pneumatic enema is used to confirm the diagnosis and to reduce the intussusception. Hydrostatic reduction is contraindicated if the child has signs of peritonitis or gangrenous bowel. A surgeon should be present at the time of attempted reduction. In performing barium enema to reduce intussusception, the barium column should be no higher than three feet above the patient. Each attempt should persist until reduction of the intussusception fails to progress for a period of 3-5 minutes. A maximum of three attempts should be made. Successful complete reduction of the intussusception can be observed when the intussusceptum passes through the ileocecal valve producing free flow of contrast into the distal ileum. For pneumatic reduction, air is delivered into the colon via a transanally placed foley catheter. An initial pressure of 80 mmHg is raised to a maximum pressure of 120 mmHg. Reflux of air into the terminal ileum, seen fluoroscopically, signifies reduction of the intussusception.

If the intussusception is successfully reduced, the child is admitted for overnight observation. Oral diet is resumed on the next morning. If the intussusception cannot be completely reduced, operative intervention is indicated.

Surgery is indicated in children with:

1. clinical evidence of dead bowel,
2. peritonitis,

3. septicemia,
4. evidence of an anatomic/pathologic lead point,
5. failed enema reduction.

Surgical exploration for intussusception is performed through a right lower quadrant transverse incision. Retrograde pressure is applied by squeezing the intussusceptum within the intussusciptens in a proximal direction. No "pulling" attempts should be made at the ileal end. Following successful reduction, it is important to assess bowel viability and search for anatomic lead points. Appendectomy is usually performed but optional. Local or segmental resection is indicated if:

1. the intussusception cannot be reduced,
2. the segment of bowel appears infarcted or nonviable, or
3. a lead point is identified. Primary anastomosis can usually be performed with minimal morbidity.

Fever, probably related to cytokine release and/or bacterial translocation, commonly occurs following reduction of intussusception whether performed surgically or nonoperatively and should be anticipated.

## Outcomes

Hydrostatic barium enema can successfully reduce intussusceptions in 50-75% of cases. Success with air insufflation for reduction is even better and may be as high as 95%. The recurrence rate of intussusception after successful reduction (whether hydrostatic or surgical) is about 5-7%. Recurrence may be slightly lower with reduction using air insufflation. The mortality rate of intussusception is less than 1%. Mortality increases with delay in diagnosis, inadequate fluid resuscitation, perforation, and surgical complications.

## Selected Readings

1. Young DG. Intussusception. In: O'Neill, Jr. JA et al, eds. *Pediatric Surgery*, 5<sup>th</sup> Edition. St. Louis: Mosby 1998; 1185-1198.
2. Ravitch MM. Intussusception in infancy and childhood: an analysis of seventy-seven cases treated by barium enema. *N Engl J Med* 1958; 259:1058.
3. Hirschsprung H. Tilfaelde af Subakut Tarminvagination. *Hospitals-Tidende* 1876; 3:321.
4. Stringer MD, Pablot SM, Brereton RJ. Paediatric intussusception. *Br J Surg* 1992; 46:484.
5. Raffensperger JG, Baker RJ. Postoperative intestinal obstruction in children. *Arch Surg* 1967; 94:450.

## Disorders of the Spleen

*Harry T. Papaconstantinou and Dai H. Chung*

The spleen has several major functions. Hemopoietic production of the fetal spleen continues until approximately 5 months of infancy, and the spleen is a storage, as well as removal site for pathologic erythrocytes, leukocytes and platelets. The splenic white pulp, which has the largest collection of lymphoid tissue, plays an important immune function by producing immunoglobulins (IgM) as well as opsonizing proteins (tuftsin and properdin). These proteins enhance neutrophil phagocytosis and stimulate complement production. Circulation through the red pulp allows splenic phagocytes to remove opsonized microorganisms with or without specific antibodies.

### Anomalies

Accessory spleens are present in 16% of the children undergoing splenectomy and 25% of autopsy series. They are usually located near the splenic hilum, the tail of the pancreas, the greater curvature of the stomach and, less frequently in the splenocolic or splenorenal ligaments, the greater omentum, and the bowel mesentery. An aggressive approach to remove all accessory splenic tissues is taken in those patients undergoing splenectomy for hematologic and autoimmune diseases. Missed accessory spleens can hypertrophy and manifest hypersplenism as late as 25 years after splenectomy.

Asplenia, congenital absence of the spleen, is a syndrome often associated with cyanotic congenital heart disease (i.e., transposition of the great vessels, truncus arteriosus, anomalous venous return) and intestinal malrotation. Circulating erythrocytes contain nuclear remnants (called Howell-Jolly bodies) usually removed by the spleen. These patients have an increased susceptibility to serious infection.

Polysplenia is characterized by a normally functioning, multilobed spleen. Polysplenia syndrome often accompanies absence of the inferior vena cava, preduodenal portal vein, midgut malrotation, aberrant hepatic artery, situs inversus, and biliary atresia. In fact about 10% of infants with biliary atresia have polysplenia syndrome.

### Splenectomy

Childhood diseases sometimes treated with splenectomy include congenital hemolytic anemia (spherocytosis), chronic autoimmune disorders, hypersplenism, splenic masses (cysts and tumors), and splenic trauma. The most frequent indications for splenectomy in childhood, excluding trauma, are hereditary spherocytosis and refractory idiopathic thrombocytopenic purpura (ITP). Splenectomy for staging

Hodgkin's disease was performed routinely in the past; however, the practice is now controversial due to the development of sensitive radiographic diagnostic tools and the association of secondary acute myeloid leukemia (AML) in splenectomized Hodgkin's patients receiving chemotherapy.

Splenectomy can be readily performed through a left upper transverse abdominal incision. First, the ligamentous attachments of the spleen are divided. The spleen is then delivered through the wound and the short gastric vessels are divided. Reflecting the spleen laterally, the splenic hilum is mobilized from the tail of the pancreas, and the splenic artery and vein are individually ligated and divided. Recently, laparoscopic splenectomy has become a common approach with possibly decreased morbidity compared to the open procedure. The common complications following splenectomy in the acute period include atelectasis, pancreatitis, and hemorrhage. The presence of Howell-Jolly bodies on peripheral smear reflects total splenectomy.

## Hematologic Disorders

### *Hereditary Spherocytosis*

Hereditary spherocytosis, the most common congenital hemolytic anemia, is transmitted as an autosomal dominant trait. In this disease, red blood cells have an abnormal spherical shape due to the deficiency of ankyrin, that is required for assembly of the structural plasma membrane protein spectrin. This structural deficiency results in membrane rigidity. Lack of the biconcave red cell shape leads to trapping and destruction in the splenic pulp.

Clinically, patients present with varying degrees of anemia, jaundice, fatigue and splenomegaly. The chronic anemia is usually mild, but infection can lead to a crisis of rapidly developing severe anemia with generalized symptoms of headache, nausea and abdominal pain. Jaundice tends to parallel the severity of anemia. Children with long standing severe symptoms may exhibit signs of growth failure and cholelithiasis as a result of chronic hemolysis. The development of biliary tract calculi increases with age and may reach 50% in adolescents.

Diagnosis is strongly suggested when there is a family history of spherocytosis and a child presents in an anemic crisis. Peripheral blood smear reveals the presence of spherocytes in combination with an increased reticulocyte count (5-20%) and a negative Coombs test. Red blood cells exhibit an increased osmotic and mechanical fragility in hypotonic saline. Infusion of labeled  $^{51}\text{Cr}$  demonstrates decreased red blood cell trapping and destruction in the spleen.

Hereditary spherocytosis is the most common indication for elective splenectomy. Splenectomy is performed soon after diagnosis if symptoms are marked or there has been a hypoplastic crisis. However, unless clinical symptoms are severe, splenectomy should be deferred until 4-6 years of age because of the increased susceptibility to sepsis. Neonates with severe hemolytic anemia and high bilirubin levels may require urgent splenectomy to prevent brain damage due to kernicterus. The gallbladder is examined by ultrasound preoperatively. If stones are present, combined cholecystectomy with splenectomy is performed.

### *Idiopathic Thrombocytopenic Purpura*

Idiopathic thrombocytopenic purpura (ITP) is an immune-mediated hemorrhagic syndrome in which antibody-sensitized platelets are destroyed in the reticuloendothelial system. In children, the peak incidence is between 4 and 8 years of age, with a prevalence of 1-13 per 100,000 patients. This is a generally benign, self-limiting illness that occurs a few weeks after a viral upper respiratory tract infection. Patients with ITP have increased circulating platelet-associated IgG, and the spleen is both the source of antiplatelet antibodies and the site of increased platelet destruction.

Patients with the acute form of ITP usually present with the sudden onset of ecchymosis, petechiae, and less frequently with epistaxis, bleeding gums, and hematuria. Central nervous system hemorrhage occurs in 1-3% of patients and is an ominous sign with poor outcome. In the chronic form of ITP, the onset is insidious, with cyclic remissions and exacerbations of symptoms, such as easy bruising and petechiae. Splenomegaly is unusual in children with chronic ITP (2%) and is usually a manifestation of another underlying disease such as lymphoma. Bone marrow aspirates are not indicated in these children, but if performed, show an increase in the number of large megakaryocytes without platelet budding. Circulating antigens or antibodies resulting from an infection may alter the platelet membrane, or immune complexes may adsorb to the platelet surfaces resulting in opsonization and destruction of immature platelets.

Approximately 75% of children with acute ITP will experience spontaneous remission with normal platelet counts within 3 months of diagnosis. Ten to 20% of patients may progress to the chronic form, which is defined as lasting > 6 months. Acute ITP is primarily treated with limitation of antiplatelet drugs and pharmacologic treatment with corticosteroids. Intravenous gammaglobulin (IVIG) may be used in patients at higher risk for hemorrhage. Oral prednisone is administered at 2 mg/kg/day in divided doses for 1 to 3 weeks. Corticosteroids function by:

1. preventing phagocytosis of antibody-coated platelets,
2. diminishing binding of IgG to the platelet,
3. enhancing platelet production, and
4. decreasing antiplatelet antibody synthesis.

Infusion of IVIG, 400 mg/kg/day for 5 days, leads to a rapid rise in platelet count in children with both acute and chronic disease, and functions to saturate immune binding sites on mononuclear phagocytes, thereby inhibiting clearance of platelets bound with autoantibodies. Chronic ITP patients should be worked up thoroughly for other autoimmune diseases and/or connective tissue disorders (i.e., lupus erythematosus). Treatment is based on the severity of symptoms and thrombocytopenia. Corticosteroids and IVIG are also the primary medical therapy for chronic ITP. Plasmapheresis, anti-Rh(D), and  $\alpha$ -interferon may also be beneficial therapies. Approximately 18% of children with chronic ITP will require splenectomy for refractory disease. Preoperatively, the patients receive vaccinations against encapsulated organisms. Long term remission nears 80% postsplenectomy but the remaining 20% require administration of further medication to include cytotoxic immunosuppressive drugs.

## Thalassemia

$\beta$ -thalassemia, which is also known as Mediterranean anemia or erythroblastic anemia of childhood, is a condition in which anemia results from a defect in the erythrocyte. Frequent blood transfusions are required and patients often present with splenomegaly. Splenectomy is indicated when the need for blood transfusions increases markedly along with persistent elevation of reticulocyte count as well as severe hypersplenism.

## Cysts and Tumors

Benign tumors are rare and include splenic hamartomas, hemangiomas, adenomas and lipomas. If symptomatic, partial splenectomy may be indicated. Lymphomas are the most common malignant tumors involving the spleen. In children, lymphoma is far more commonly found as metastatic disease to the spleen. Angiosarcoma is the primary malignant tumor of the spleen and frequently is metastatic at the time of presentation.

The various splenic cysts include congenital cysts (Fig. 24.1), pseudocyst (generally arising after trauma), and parasitic cysts commonly caused by *Echinococcus granulosus*. For all these conditions, symptoms indicate the need for splenectomy or partial splenectomy.

## Hypersplenism

Anemia, leukopenia, and thrombocytopenia due to increased destruction of cells characterize hypersplenism. Patients have splenomegaly and evidence of bone marrow hyperplasia. In most cases there is some condition that produces splenomegaly and finally hypersplenism. Spherocytosis, ITP, Gaucher's disease, sarcoidosis, Hodgkin's disease, portal hypertension, and parasitic infections (i.e., schistosomiasis, visceral leishmaniasis, malaria) are all examples of disease processes complicated by hypersplenism. In most instances, the indications for splenectomy are relative and require careful judgment.

## Postsplenectomy Sepsis

After splenectomy, individuals are more susceptible to fulminant bacteremia after splenectomy due to the following changes:

1. decreased clearance of bacteria from the blood,
2. decreased levels of IgM, and
3. decreased opsonic activity.

Overwhelming postsplenectomy sepsis (OPSI) is characterized by septicemia with frequent meningitic involvement. The risk of sepsis is greatest in young children and 80% of cases occur within 2 years after surgery. The overall incidence of OPSI is 4.25%, but varies with age and underlying disease. Splenectomy for trauma and incidental operative injuries carries the lowest risk (1.5-2%). The highest risk occurs in patients with thalassemia and reticuloendothelial disorders (10-11%). OPSI risk is 2-8% in patients with congenital hemolytic anemias or ITP. Regardless of the incidence, mortality rates of OPSI approach 50%. Death can occur within 12-24 hours after the onset of symptoms and is frequently associated with adrenal hemorrhage (Waterhouse-Friderichsen syndrome). Prodromal signs are minimal; the patients typically present with cardiovascular collapse and high fever.

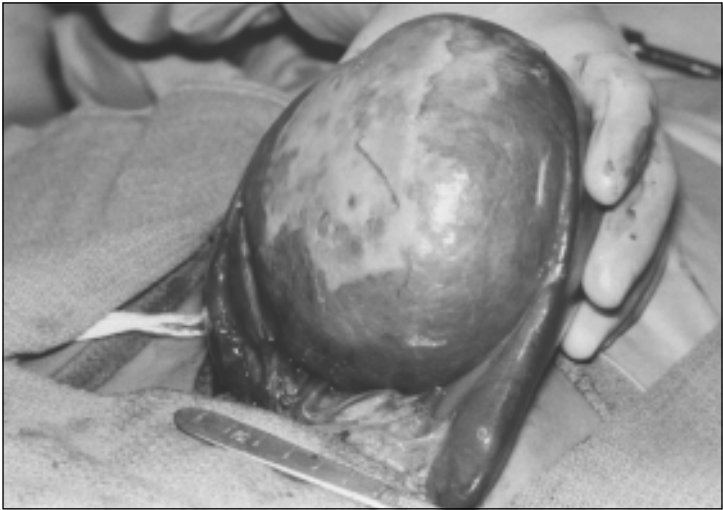

Fig. 24.1. Large, posttraumatic splenic cyst shown at surgical excision

*Streptococcus pneumoniae* is responsible for the majority (50%) of reported OPSI cases. *Hemophilus influenzae*, *Meningococcus*, *Escherichia coli*, and *Staphylococcus* are the next most common offending bacteria.

Prevention is the key to overcoming problems related to OPSI. All patients undergoing splenectomy require immunization with polyvalent capsular polysaccharide antigens of pneumococci (Pneumovax), *H. influenzae*, and meningococci. The vaccines should be administered 2 weeks prior to operation; however, if splenectomy is urgent or emergent, they may be given in the postoperative period. Pneumovax, which provides protection against 85% of all pneumococcal infections, can provide adequate antibody levels for 3-5 years. Prophylactic penicillin is also given to asplenic patients for several years, especially in younger children with additional prophylaxis required at the time of high-risk procedures such as dental work.

### *Selected Readings*

1. Holdworth RJ, Irving Ad, Cuschieri A. Postsplenectomy sepsis and its mortality rate; actual versus perceived risks. *Br J Surg* 1991; 78(9):1031-1038.
2. Imbach P, Kuhne T. Immune thrombocytopenic purpura ITP. *Vox Sang* 1998; 74(Suppl 2):309-314.
3. Lane PA. The spleen in children. *Curr Opin Pediatr* 1995; 7:36-41.



# Rectal Prolapse and Anal Disorders

*Steve Szczerba*

Anorectal problems ranging from simple constipation to chronic and intractable constipation, fistulae, fissure, prolapse, etc. are very common and bothersome in childhood. This Chapter deals briefly with the more frequently encountered problems.

## **Constipation**

Childhood constipation is definable as delay or difficulty in defecation to the point of distress in the child. Encopresis is defined as overflow incontinence or repeated soiling of underwear with stool that occurs in a child over 5 years of age.

### *Incidence*

Soiling is reported in 3% of children older than 4 years of age. Most studies reveal a male predominance (6:1 ratio) and 50% familial incidence.

### *Etiology*

Various disorders can cause constipation and the most common etiologies are very age dependent. No organic etiology is identifiable in most children (Table 25.1). In infants less than 1 year of age anatomical and dietary factors predominate. In older children, behavioral and dietary factors predominate. In children with neuromuscular disorders, constipation is a very common problem. Contributing factors often include:

1. lack of coordination between abdominal muscle contraction and anal relaxation,
2. difficulty passing stool in a supine position,
3. decreased fluid intake.

### *Clinical Presentation*

Chronic constipation develops typically between 2-4 years of age. In 50%, constipation develops before toilet training. Episodes of constipation often increase when the toddler is beginning to gain control over defecation. Typically, children with constipation report chronic, recurring, nonspecific abdominal pain. Further questioning may reveal problems such as poor toilet training, enuresis, stools of very large caliber, and soiling. In cases of typical, functional constipation, soiling occurs during periods of activity. The child often reports no sensation of fullness or urgency. Chronic encopresis may occasionally present as chronic diarrhea. The child mistakenly

**Table 25.1. Causes of constipation in children**

<b>Common Causes:</b>	Normal variation Dehydration Excess cow's milk Dietary change:   Change of formula Change to cow's milk Introduction of solids Anal fissure Perianal streptococcal infection Dysuria Reluctance to use an unfamiliar bathroom
<b>Anatomical Conditions:</b>	Anterior anus or rectum Hirschsprung's disease Congenital rectal stenosis Colonic stricture (after NEC) Imperforate anus Spina bifida occulta Spinal cord tumor Tethered spinal cord
<b>Systemic Disorders:</b>	Hypothyroidism Diabetes mellitus Lead poisoning Hypercalcemia Diabetes insipidus Cystic fibrosis Neurologic immaturity
<b>Miscellaneous:</b>	Meconium plug MEN IIb Intestinal pseudoobstruction Visceral myopathy Child abuse (Munchausen's by proxy) Chagas disease Neurofibromatosis
<b>Medications:</b>	Diuretics Anticonvulsants Supplemental Iron

appears to be straining to have a bowel movement when he or she is actually straining to retain stool.

Physical exam reveals a slightly distended, nontender abdomen. Stool is easily palpable in the lower left quadrant. Inspection of the perineum is performed to evaluate for anal fissures, cellulitis, anterior ectopic anus, or other anorectal disorders. Digital rectal exam often reveals a shortened anal canal with decreased sphincter tone. The rectum is dilated and full of stool. The differential diagnosis includes all etiologies listed in Table 25.1. Hirschsprung's disease is considered, especially in children with failure to pass meconium within the first 24-48 hours of life.

### *Diagnosis*

Primarily, history and physical examination make the diagnosis. An abdominal x-ray should be done to evaluate the intestinal gas pattern and rule out vertebral anomalies. A contrast enema is useful to delineate anatomic or functional causes of constipation. To be most useful, it should be performed without a bowel prep or a digital rectal exam. Functional constipation will cause the colon and rectum to dilate to the rectal verge. CT, MRI and ultrasound can sometimes be useful adjuncts to evaluate anatomic abnormalities but are not used routinely.

Anal manometry with electromyography helps differentiate functional constipation from neurological problems. Electrostimulation of the perineum is sometimes useful to determine the location of the anus relative to the sphincter complex in constipated children suspected of having an abnormally positioned or anteriorly displaced anus. Tissue biopsy may be necessary to rule out Hirschsprung's disease.

### *Pathophysiology*

Functional constipation usually begins with a painful bowel movement from a large stool, anal fissure, or a perianal or perirectal abscess. The child then fears discomfort and stool is voluntarily held in the rectum by the external anal sphincter. As the rectum dilates around the bolus of feces, the urge to defecate disappears. The cycle of stool withholding causes rectal relaxation, reflex relaxation of the internal anal sphincter, and dilation of the rectosigmoid. Continence then depends on conscious contraction of the external anal sphincter. When the child is involved in play or is distracted, liquid stool passes around the fecal bolus and leaks past the external anal sphincter and stains underclothes (encopresis).

### *Treatment*

The treatment for chronic or acute constipation in the older child is a three-step process that is outlined in Table 25.2. In summary, the treatment for constipation is removal of stool in the rectum and the use of a combination of laxatives and behavior training to keep the rectum empty and prevent stool reaccumulation. This allows the rectum to return to its normal size and regain normal sensory and muscular function. Adjunctive pharmacologic therapies can include oral administration of cisapride, a prokinetic agent, and mineral oil.

### *Outcome*

Approximately 60-70% respond during the first few months of treatment. Maintenance treatment for chronic constipation must be continued for at least 6 months to a year.

Recurrence is common. The 5-year relapse period for children with chronic constipation is approximately 20-40%.

## **Rectal Prolapse**

### *Incidence*

Rectal prolapse is a relatively common, self-limited problem in young children. An exact childhood incidence is not known. Boys and girls are equally affected.

**Table 25.2. Management plan for constipated child****Step 1. Eliminate impacted stool**

Mild to moderate impaction

1. Bicosydyd suppository
2. Enemas of saline, mineral oil, or hyperphosphate
3. Oral mineral oil as a stool softener
4. Increase of dietary fiber with dietary adjustments and supplements (Metamucil, etc.)

Severe impaction

1. Digital disimpaction
2. General anesthesia and disimpaction
3. Combination therapy as for mild impaction
4. Polyethylene glycol-electrolyte solution by nasogastric tube

**Step 2. Establish a bowel regimen**

Achieve a bowel movement every day.

1. Oral mineral oil
2. Increased dietary fiber.
3. Increase supplemental liquids (water, juices etc.)
4. Utilize the gastro-colic reflex by sitting on toilet after meals.
5. Use a foot stool if feet dangle
6. Repeat enemas or suppository if the child goes 2 days without a bowel movement

**Step 3. Maintain a healthy pattern for 6 months**

1. Once the proper dose of laxative is established and the child has a soft, comfortable bowel movement daily, maintain the laxative and bowel regimen for 6 months.
2. If symptoms return, return to Step 1.

***Etiology***

There are two types of rectal prolapse: mucosal or full-thickness. Most cases of rectal prolapse are idiopathic. Unlike adults, prolapse is only rarely associated with chronic debilitating illness, traumatic injury, or malnutrition. However, rectal prolapse is a well-known complication of cystic fibrosis (see below), and this diagnosis should be excluded in all children presenting with this problem. In addition, children with neuromuscular problems or bladder exstrophy often develop prolapse.

***Clinical Presentation***

The peak age of occurrence of rectal prolapse occurs during the years 1-3. It is frequently an intermittent problem, therefore a thorough history from the parent is required. Most parents note the prolapse after defecation, however crying, coughing or straining may also precipitate episodes of rectal prolapse. In some children, prolapse occurs with each bowel movement, but abnormal patterns of defecation, such as a constipation or diarrhea, often contribute. Mucosal bleeding from the surface of the prolapsed bowel is not uncommon.

Upon examination of the anal region, rectal prolapse appears as a swollen rosette of tissue that is slightly longer posteriorly than anteriorly. Sigmoid intussusception can also have a similar appearance but is distinguishable by digital rectal exam. Prolapse of mucosa alone may present with radial mucosal folds at the anal junction. When the prolapse is full thickness, circular folds are seen in the prolapsed mucous.

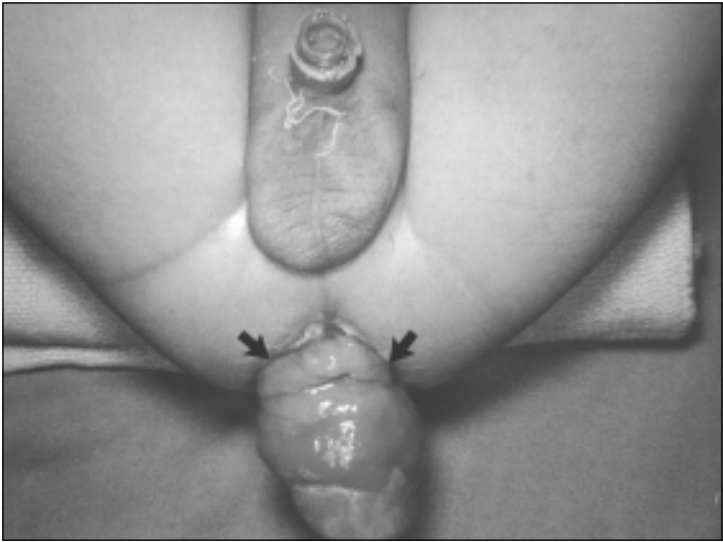

Fig. 25.1. Rectal prolapse with substantial mucosal edema shown in the prolapsed segment.

A rectal exam should be performed after the prolapse is reduced. If there is a history of rectal bleeding, proctoscopy is indicated.

In addition to sigmoid intussusception, conditions to be considered in the differential diagnosis are cystic fibrosis and conditions associated with tenesmus, such as parasites, polyps, inflammatory bowel disease, and proctitis. Approximately 20% of children with cystic fibrosis will develop some degree of rectal prolapse.

### *Diagnosis*

The diagnosis is made by history and physical alone. Occasionally, colonoscopy or contrast enema may be required to evaluate for lead points such as polyps. All children should be tested for parasites (stool specimens for ova and parasites) and cystic fibrosis (sweat test for chloride analysis).

### *Pathophysiology*

At younger ages, anatomical and social factors may contribute to the development of rectal prolapse. In infants and toddlers, the rectal mucosa is loosely adherent to the underlying muscles. There is increased demand on the perineal musculature for continence and toilet training. Additionally, flattening of the developing sacrum redirects intraabdominal pressure toward the anus.

### *Treatment*

Acute prolapse can easily be reduced by pushing the tip of the herniated bowel into the anus. Once edema has developed, a gentle squeezing pressure may be required. Parents must be taught to reduce the prolapse promptly if there is recurrence. Tapping of the buttock has been used but is not always effective. To limit recurrence, one

must treat the precipitating cause and limit straining. Improvement in diarrhea or constipation, delaying or limiting toilet training and medical treatment for parasites or cystic fibrosis usually resolve the problem in 1-2 months. Rarely, if rectal prolapse persists after conservative management, surgical intervention may be required. Sclerosing injections under general anesthesia in four quadrants linearly into the rectal submucosa is one technique. Rarely, full thickness rectal prolapse may be resistant to sclerosing techniques and an operation is indicated. Cerclage, creating a temporary anal stenosis of the external anal sphincter, is a simple and usually effective technique. Posterior presacral rectopexy is a more invasive surgical treatment but is effective. Surgical intervention should be reserved for only the most severe cases refractory to simpler interventions.

### *Outcomes*

Sclerosing techniques are up to 90% effective. Bleeding, infection, stricture and abscess formation may complicate attempted sclerosis or surgical interventions. Recurrence rates after surgery are low, however, constipation may be a complication.

## **Anal Fissure**

### *Incidence*

An anal fissure is a tear in the mucosa and the anoderm lining the anal canal. These lesions are common in infancy and are the most common cause of bright red blood per rectum in that age group (see Chapter 53).

### *Etiology*

Anal fissures occur in the setting of constipation and passage of large, hard stools that cause a mechanical tear of the anal mucosa. Diarrhea can cause a chemical irritation from stool alkalinity. Pain associated with anal fissures may potentiate constipation and seems to be related to hypertonicity of the anal sphincters.

### *Clinical Presentation*

Anal fissures in children most commonly occur during infancy. The usual presenting symptom in that age group is bright red blood per rectum. Crying with bowel movements and hard stool streaked with bright-red blood are the common findings observed by the parents.

Gently spreading the anus (also having the older child bear down), exposes the dentate line and the longitudinal tear comes into view. Fissures are most commonly located in the posterior midline and distal to the dentate line. An unhealed fissure may become infected and evolve into a chronic ulcer. If this occurs a sentinel skin tag forms distal to the fissure, and the anal papilla may hypertrophy. Fissures are sometime multiple and may occur anteriorly. Fissures located laterally suggest Crohn's disease or immunodeficiency states. Chronic anal fissures in older children may indicate inflammatory bowel disease.

### *Diagnosis and Treatment*

Anal fissures are diagnosed from history and physical. Acute fissures respond to gentle anal dilation, stool softeners, laxatives, and Sitz baths. If fissures are secondary to underlying conditions, treatment is directed to these conditions as well. Fissures

associated with inflammatory bowel disease may be treated with metronidazole. Topical anesthetic ointments after each bowel movement reduce sphincter spasm and pain. A hypertonic anal sphincter may be treated with botulinum toxin and topical nitroglycerine or a lateral subcutaneous internal sphincterotomy. Chronic anal ulcers are surgically excised eliminating granulation/scar tissue while preserving the sphincters. Leukemia and chronic immunosuppression are contraindications to surgical intervention since such fissures fail to heal until these problems are addressed.

### ***Outcomes***

Most acute fissures respond to conservative measures and heal within 10-14 days. Recalcitrant fissures respond to lateral internal sphincterotomy. This procedure quickly relieves symptoms in 95% of cases and recurrence is less than 5%.

### **Perianal and Perirectal Abscess**

Infants are commonly affected with infections and abscesses in the perianal area. Infected diaper rash is the most common cause of superficial abscesses. Staphylococcal or gram negative enteric organisms are the most common organisms involved. Deeper abscesses of the anal canal or perirectal tissues arise from crypt infections. These infections are usually caused by enteric and anaerobic organisms.

### ***Clinical Presentation***

Girls and boys are equally affected when less than 1 year of age. With children older than 1 year, males are more commonly affected. Parents frequently report the presence of a perianal mass and sitting intolerance. For perianal abscesses, examination of the anus reveals a tender, erythematous mass lateral to the anus. Perirectal abscesses are frequently associated with fever and malaise in addition to sitting intolerance.

On careful digital exam even deep perirectal abscesses may be palpable as a fluctuant mass. Crohn's disease may present as a perirectal abscess and should always be considered. Rarely, infected rectal duplications or dermoid cysts can present clinically as perirectal abscesses. Type III sacrococcygeal teratomas have been mistakenly identified and treated as perirectal abscesses. If the diagnosis is not obvious, CT scan of the abdomen and pelvis with oral, rectal and IV contrast will demonstrate most perirectal abscesses.

### ***Treatment***

Superficial perianal abscesses can be treated with Sitz baths. Typically antibiotics are not required. If the area becomes fluctuant, incision and drainage may be offered. Deeper infections require immediate drainage under general anesthesia along with intravenous antibiotics.

### ***Outcomes***

One third of superficial perianal abscesses resolve without surgery but the majority require surgical drainage. One third of these abscesses recur. Nearly 30-50% of infants presenting with perianal abscesses actually have fistula-in-ano. Deeper infections heal well after incision and drainage. As with the superficial lesions, recurrence is not uncommon.

## **Fistula-In-Ano**

Although crypt abscesses are the usual cause of a fistula-in-ano, perianal abscesses may be the inciting infection. In patients with perianal abscesses, up to 50% will develop a fistula.

### *Clinical Presentation*

Children with fistula-in-ano have pain with bowel movements and frequently have recurrent perianal infections that drain mucus. When the mucus stops draining, a small, indurated pustule will become evident. Occasionally dark stool may be seen inside the tract. The clinical scenario and the physical exam are adequate to make the diagnosis.

Classically, the cause of fistula-in-ano is a crypt abscess that extends to the perianal skin. The fistula tract is usually intersphincteric (tracking between the internal and external sphincters) or transsphincteric (penetrating through the external sphincter muscle tissue) connecting the crypt to the external perianal skin. In infants, the fistula almost always extends straight radially from the involved crypt and opens on the skin laterally. Goodsall's rule does not apply in infants.

### *Treatment*

Treatment is surgical. Antibiotics are used if there is associated cellulitis. Most surgeons perform a fistulotomy to open the track over its entire length. A lacrimal probe is passed through the tract and the overlying tissue is opened to the fibers of the sphincter muscle. The tract lining is curetted and the wound is left open. Post-operatively, Sitz baths, wound care and stool softeners are used. Rarely, a seton is used for high, transsphincteric fistulas. Typically an 0-silk or a rubber band is pulled through the tract with the probe. The seton is tightened or manipulated over the course of a few weeks. The muscle fibers are slowly cut, allowing the fistula to be unroofed without risking incontinence. If the tract is well developed with granulation tissue, a fistulectomy is an alternative to fistulotomy.

## **Hemorrhoids**

Hemorrhoids in children are unusual. Four to five percent of children with portal hypertension may develop symptomatic bleeding rectal varices. The clinical presentation is variable with thrombosis occurring most frequently in teenagers. Hemorrhoid thrombosis is frequently associated with heavy physical activity. Symptoms may be a report of a perianal mass that prolapses, rectal bleeding, or perianal itching. Children with hemorrhoids frequently have an anal ulcer with a prominent skin tag, rectal prolapse, or rectal polyp. Rectal duplications can rarely present as an external hemorrhoid. Physical exam and history are usually adequate to establish the diagnosis.

### *Treatment*

When bleeding occurs in children with portal hypertension, sclerotherapy may be attempted, however, direct oversewing is the definitive therapy. In children with thrombosed hemorrhoids therapy depends on timing of presentation. If seen within the first 24 hours of symptoms, incision and clot removal provides immediate relief if pain is the presenting symptom. After the first day, spontaneous resolution is underway. Rest, analgesics, stool softeners, and Sitz baths are then the treatment of



choice. Hemorrhoidectomy, the surgical procedure of choice, is reserved for chronic hemorrhoids that do not respond to medical therapy. It has a low recurrence rate (< 0.5%). Hemorrhoid surgery is contraindicated in most children who are immunocompromised. Sclerotherapy or rubber-band ligation are recommended over formal hemorrhoidectomy in children with hemorrhoids and concomitant inflammatory bowel disease.

### Condyloma Acuminata

Perianal condyloma acuminata are caused by human papillomavirus subtypes 6, 11, 16, and 18. Sexual abuse is associated in 60-90% of cases, however, vertical transmission from nongenital skin of mother to infant is a possibility. Perianal warts appear anytime from infancy to adulthood. Condylomata are found mostly on the moist perineum in the perianal area. They appear as single or multiple sessile or pedunculated, red, papillary excrescences. The diagnosis is made merely by clinical appearance.

Topical treatment with podophylline or bichloroacetic acid is the treatment of choice for a small number of warts. Podophylline is diluted 1:4 with a tincture of benzoin and applied to the individual warts on the perineum weekly. It should not be applied to warts in the anal canal. The perineum needs to be washed at 2 hours after application. Bichloroacetic acid may be used in the anal canal and is also applied weekly. The warts turn white after application. Dilute sodium bicarbonate solution is used to neutralize excess acid after application. When warts are numerous or involve the anal canal, surgical therapy is more effective. Fulguration with electrocautery, carbon dioxide laser ablation, or excision are the commonly used approaches. One must be careful to minimize the loss of normal epithelium. Despite therapy, the recurrence rate of condylomata is very high.

### Selected Readings

1. Squires RH Jr. Common problems in pediatric gastroenterology. *Comprehensive Therapy* 1996; 22(12):767-75.
2. Abrahamian JF, Lloyd-Still JD. Chronic constipation in children: a longitudinal study of 186 patients. *J Pediatr Gastroenterol Nutr* 1984; 3:460.
3. Stafford PW. Other disorders of the anus and rectum, anorectal function. In: O'Neill JA Jr., Rowe MI, Grosfeld, JL et al, eds. *Pediatric Surgery*, 5<sup>th</sup> ed. St. Louis: Mosby-Year Book 1998; 1449-1460.
4. Sempsky WT, Rosenstein BJ. The cause of rectal prolapse in children. *Am J Dis Child* 1989; 142:338.
5. Ashcraft KW, Garred JL, Holder TM. Rectal prolapse—17 year experience with the posterior repair and suspension. *J Pediatr Surg* 1990. 25:92.
6. Wyllie GG. The injection treatment of rectal prolapse. *J Pediatr Surg* 1979; 14:62.
7. Abercrombie JF, George BD. Perianal abscesses in children. *Ann R Coll Surg Engl* 1992; 74:385.
8. Poenaru D, Yazbeck S. Anal fistula in infants: etiology, features, management. *J Pediatr Surg* 1993; 28:1194.
9. Shafer AD, McGlone TP, Flanagan RA. Abnormal crypts of Morgagni: The cause of peri-anal abscess and fisutula-in-ano. *J Pediatr Surg* 1987; 22:203.
10. Heaton ND, Davenport M, Howard ER. Symptomatic hemorrhoids and anorectal varices in children with portal hypertension. *J Pediatr Surg* 1992; 27:833.

## **Section IV: Pediatric Trauma**

# Initial Assessment and Resuscitation

*Matthew L. Moront*

## **Organization**

The initial assessment is organized into three distinct phases of care:

1. the primary survey,
2. the transition phase, and
3. the secondary survey.

### *Primary survey*

The purpose of the primary survey is to rapidly identify immediately life threatening injuries and prioritize the management of these injuries. Life threatening problems identified in the primary survey are addressed immediately as they are identified. The use of a systematic, standardized series of steps allows everyone involved to anticipate and participate in an organized manner without a need for lengthy explanations and without duplication of effort.

The primary survey is conducted expediently in the following sequence:

1. Airway and C-Spine Stabilization
2. Breathing
3. Circulation
4. Disability (Neurologic)
5. Exposure and protection from hypothermia

### *Transition Phase*

The transition phase bridges the gap between the Primary and Secondary surveys. This is the time for reassessment of the patient's status. Many essential tasks are accomplished during this phase. Consultants are contacted and trauma radiographs are obtained. If transfer of the child to a trauma center is indicated, this process is begun immediately.

Interventions such as gastric and bladder decompression, venipuncture for blood type and crossmatch, and additional intravenous access procedures are performed. If hemodynamic or clinical instability occurs at any time during the evaluation and treatment process, a complete re-evaluation from the beginning is performed.

### *Secondary Survey*

The secondary survey is a comprehensive evaluation of the patient to identify and initiate treatment for all injuries.

## Primary Survey

### Airway

Establishing and maintaining a secure airway is the highest priority in the care of an injured child. Protection of the cervical spine through proper immobilization is essential until an injury can be excluded.

### Assessment

Airway assessment begins as the child arrives by noting the child's color, respiratory rate, mental status, and chest wall movement. Children with head injuries or an altered level of consciousness (i.e., Glasgow coma scale (GCS) score of 8 or less) are considered unable to protect their airways and require immediate intubation.

### Treatment

All injured children receive high-flow supplemental oxygen and cardiorespiratory monitoring. Initial airway interventions include maneuvers as simple as clearing the mouth and hypopharynx of secretions or foreign bodies. Other measures to secure a protected airway include the jaw thrust maneuver, nasal or oral airway placement, and endotracheal intubation. With careful assessment and early intervention, a surgical airway is rarely necessary. A surgical airway is required when all other interventions have failed or in cases of severe maxillofacial trauma.

Endotracheal intubation is best performed in a controlled setting by clinicians experienced in pediatric airway management. Medications commonly used to provide amnesia, analgesia, sedation, and muscle relaxation for intubation include:

- |               |              |                  |
|---------------|--------------|------------------|
| 1. Atropine   | (0.01 mg/kg) | (min dose-0.1mg) |
| 2. Lidocaine  | (1 mg/kg)    | head injuries    |
| 3. Thiopental | (3-5 mg/kg)  | sedation/amnesia |
| 4. Fentanyl   | (2 mcg/kg)   | analgesia        |
| 5. Vecuronium | (0.1 mg/kg)  | paralysis        |

Children with serious head injuries require lidocaine prior to intubation. Hypoxia and hypotension contribute to secondary brain injury and must be avoided.

Gastric decompression and bladder catheterization are necessary in intubated and paralyzed children and are accomplished as soon as possible following intubation. A portable chest radiograph confirms tube placement and excludes hemothorax or pneumothorax.

### Reassessment

The ability of an injured child to protect and maintain his/her airway must be constantly reconfirmed. The initial assessment provides stimulation that helps maintain a satisfactory level of consciousness. A careful reassessment is required after the initial resuscitation, but before leaving the trauma bay to ensure no change in the child's ability to protect or maintain his/her airway. Airway edema, anemia, hypovolemia, and increasing intracranial pressure can all cause delayed airway compromise if not recognized and treated early.

## ***Breathing***

### **Assessment**

Assessment of breathing includes an evaluation of respiratory mechanics to insure adequate ventilation. As with the airway assessment, this begins with a visual inspection of the child for signs of increased work of breathing or asymmetrical chest wall movement. Other visual clues suggesting respiratory compromise include anxiousness due to hypoxia, nasal flaring, chest wall retractions, tachypnea, or a flail segment. The chest is palpated for signs of crepitus, penetrating injuries, tenderness, rib fractures or chest wall instability.

Auscultation of the chest follows which includes evaluation for symmetrical breath sounds in all lung fields. Normal heart tones and good air movement without stridor or wheezing suggests adequate respiratory mechanics for oxygenation and ventilation.

The chest wall of a child is more pliable than that of an adult. The ribs are more cartilaginous, there is less musculature, and the mediastinum is less well fixed. Significant underlying parenchymal injury can occur in the absence of rib fracture or chest wall contusion.

### **Treatment**

Treatment of the most common thoracic injury, pulmonary contusion, is largely symptomatic and supportive. The same is true for rib fractures, even those associated with a flail chest. Careful monitoring combined with aggressive pain management is frequently all that is necessary. Children with large flail segments that cause respiratory compromise may require endotracheal intubation and mechanical ventilation if pain control does not allow adequate respiratory effort. Other common thoracic injuries include pneumothorax and hemothorax. Both are treated with a thoracostomy tube placed in the fifth intercostal space along the anterior or mid-axillary line.

A tension pneumothorax compromises venous return of blood to the heart if not immediately decompressed. Placement of a 16 or 18 gauge needle in the second or third intercostal space along the mid-clavicular line is lifesaving in this situation. This must be quickly followed by a thoracostomy tube to prevent reaccumulation of the pneumothorax.

Thoracostomy tube placement for hemothorax may return a large amount of blood requiring surgical hemostasis. Initial chest tube output of greater than 20 cc/kg or sustained output of greater than 2 cc/kg/hr for more than four hours may require surgical exploration for hemorrhage control.

### **Reassessment**

Any intubated child requires repeated reassessments to insure proper endotracheal tube position. Auscultation is performed after any patient movement for additional testing such as computed tomography scans, radiographs or operative intervention.

## *Circulation*

### **Assessment**

Assessment of circulation involves evaluation for indicators of inadequate tissue perfusion and identification of sites of active hemorrhage. Unlike adults, a child can maintain a normal blood pressure despite losing 25-40% of his blood volume. Other signs that indicate reduced circulating volume include:

1. an altered level of consciousness,
2. cool mottled extremities,
3. delayed capillary refill,
4. narrowed pulse pressure,
5. tachycardia, and
6. tachypnea.

### **Treatment**

As a rapid assessment is being carried out, 2 large bore peripheral intravenous catheters are placed. No more than 90 seconds is taken to secure peripheral venous access. Children in shock often exhibit peripheral vasoconstriction so that obtaining intravenous access can be a formidable challenge. A systematic stepwise approach is required to prevent unnecessary delays in fluid resuscitation and restoration of circulating volume. It is ideal if blood samples can be drawn for a type and crossmatch and labs at the time that the venous access is placed.

Alternative access opportunities include saphenous vein cutdown, femoral vein access via Seldinger technique or direct visualization, and placement of an interosseous catheter for unconscious children in extremis. Lacerations demonstrating significant hemorrhage are controlled with direct pressure.

Fluid resuscitation begins with a 20 cc/kg bolus of Lactated Ringers solution, followed by a reassessment of vital signs, mental status, distal perfusion, etc. A second bolus of 20 cc/kg of crystalloid is administered if signs of inadequate tissue perfusion persist. A third bolus of Lactated Ringers solution can be given if necessary, but further fluid requirements are met with a bolus of 10 cc/kg of type specific packed red blood cells. Persistent fluid requirements, acidosis, or hemodynamic instability suggest ongoing hemorrhage.

## *Disability*

### **Assessment**

A rapid evaluation of mental status, and examination for signs or symptoms of head injury or gross peripheral sensorimotor deficit is made. The Glasgow Coma Score (GCS) is noted. The cervical spine cannot be fully evaluated in children with altered mental status; it must be protected until adequate evaluation can be made.

### **Treatment**

Patients with findings or a scene report of diminished consciousness, loss of consciousness, seizures, or posturing are evaluated as soon as possible by computed tomography (CT) of the brain after initial assessment and reevaluation are complete and the patient is stabilized.

## **Reassessment**

Careful reassessment is mandatory in children with head injury. The neurologic exam can evolve during the primary assessment. This is also true for children with spinal cord injuries. Children with suspected head injury require reevaluation every 15-30 minutes. Vital signs are carefully monitored. Hypotension and hypoxia are avoided. Pupils are rechecked, and level of consciousness confirmed. Careful documentation and timing of the findings is extremely important.

### *Exposure*

#### **Assessment**

After stabilization, all children brought to the resuscitation area must be carefully and completely examined for injury. All items of clothes including shoes, socks, and undergarments are removed and the child is carefully rolled to each side while spinal protection is maintained. All areas not easily visualized are exposed. This is especially true of the back, perineum, occiput, and posterior cervical spine. Care is taken not to miss injuries to poorly visualized areas such as limbs splinted to protect intravenous lines or fractures, the area under the cervical collar, and the inside of the mouth.

Quickly after a careful examination is conducted, the child is covered with warm blankets. Care is taken not to prevent child's temperature to fall below 36.5°C. An axillary temperature is taken upon arrival as part of the vital signs and reassessments are made at intervals and when needed. Warmed fluids and blood are used throughout the resuscitation.

#### **Transition Phase**

### *Studies*

Reassessment of vital signs is followed by placement of additional intravenous access if needed, placement of a nasogastric tube and urinary catheter, and ordering labwork and initial radiographs of the chest, pelvis, and c-spine. Assistants are asked to call consultants or initiate procedures to transfer the child to a trauma center. Antibiotics and additional analgesia are administered if indicated. Immunization against tetanus is administered.

#### **Secondary Survey**

In the secondary survey, a systematic and thorough examination of the patient from head to toe is made to detect any peripheral, minor, or occult injury not initially recognized on the primary survey. Elements of the primary survey are re-evaluated in order to gain a sense of clinical improvement or deterioration. Splints are placed on injured extremities, nasogastric and bladder tubes are placed if not done already, antibiotics, ultrasounds, CT scans, and other tests are ordered as indicated.

#### **Tertiary Survey**

The tertiary survey is performed to ensure that an injured child is not discharged with an injury that has gone unrecognized. This is a final check of the child's ability to perform activities of daily living and appropriate movements that were not evaluated previously. Prior to hospital discharge a member of the trauma team goes to the

bedside and conducts an age appropriate physical examination. In a toddler this may simply be watching him put his shirt on or get out of bed. It is essential to examine any extremity that may have been splinted for IV protection. Similarly, the child must be seen to eat and ambulate normally prior to discharge. This survey may identify nonserious injuries that parents would have been concerned about after discharge. By conducting a tertiary survey many simple questions can be answered which will reduce parent anxiety and eliminate frequent phone calls.

### *Selected Readings*

1. American College of Surgeons Committee on Trauma. Advanced Trauma Life Support Course. Chicago, IL: American College of Surgeons 1997.
2. Glynn L, Statter MB. The ABCs of pediatric trauma. In: Arensman RM ed. Pediatric Trauma: Initial Care of the Injured Child. New York: Raven Press 1995; 7-18.
3. Moore EE. Resuscitation and evaluation of the injured patient. In: Zuidema GD, Rutherford RB, Ballinger WF eds. The Management of Trauma. Philadelphia: W.B. Saunders 1985; 5.



# Soft Tissue and Extremity Trauma

*Daniel A. Bambini and P. Stephen Almond*

## **Incidence**

Soft tissue and extremity injuries are common and account for 25% of pediatric trauma. Typically, these injuries involve skin, muscle, tendon, nerve, and/or bone. Most fractures occur as isolated injuries, but frequently skeletal fractures and soft tissue injuries occur in multiply injured children. Male children sustain fractures twice as often as females.

## **Etiology**

Soft tissue and extremity injuries are the result of blunt or penetrating trauma. Motor vehicle accidents, falls, and assaults are the most common blunt mechanisms. Guns, knives, impalement and animal bites (see Chapter 35) are the most common penetrating mechanisms.

## **Clinical Presentation**

Children with soft tissue and/or extremity trauma present with a variety of symptoms. Injuries limited to the skin and subcutaneous tissue present with localized pain and skin disruption. Injuries involving the underlying muscle or tendon may present with hemorrhage or motor deficits. Vascular injuries present with hemorrhage and signs of ischemia (pain, pallor, paresthesias, paralysis, pulselessness, and poikilothermia).

## **Diagnosis**

Extremity injuries are diagnosed during the secondary survey. The extremity is completely exposed and visually inspected for deformities, abnormal angulation, penetrations, abrasions, shortening, swelling, and ecchymosis. Pulse, blood pressure, sensory (light touch and two-point discrimination) and motor examination of the injured extremity is performed and compared to the contralateral extremity. Each joint is passively and then actively moved through its full range of motion. Radiographs are obtained to confirm a fracture and must include at least two views (anteroposterior and lateral views) and the joint above and below the fracture. If there is a questionable finding, contralateral x-rays are indicated.

## **Management**

### *Emergencies*

There are five musculoskeletal emergencies:

1. open fractures,
2. open joint injuries,
3. dislocations,
4. vascular injuries, and
5. neurologic injuries.

Children with open fractures and open joints need antibiotics and operative irrigation and debridement within 6 hours. Dislocations need to be reduced to prevent neurovascular and bone injury. Vascular injuries need to be repaired within 4-6 hours to prevent ischemic injury to muscles and nerves. Fasciotomies should be considered in cases of prolonged ischemia. Neurologic deficits need early attention to determine the cause. Deficits due to ischemia require immediate vascular evaluation whereas deficits due to nerve transection are less emergent.

### *Wound Management*

The principles of wound management include pain relief, irrigation and debridement, and wound closure. Factors influencing decision-making include the mechanism and extent of injury, wound location and degree of contamination (i.e., clean, dirty, foreign body), associated injuries, and patient age. Factors associated with a higher incidence of infection and complications include large wounds (vs. small wounds), high velocity gunshot wounds (vs. stab wounds and low velocity gunshot wounds), clean wounds (vs. contaminated wounds), and wounds closed within 4-6 hours (vs. > 6 hours). Anesthetics are given topically and/or subcutaneously. Lidocaine 1% [with or without epinephrine (1: 100,000-200,000)] is given via 25 gauge needle through the open wound. Antibiotics are given to children with the following injuries/conditions:

1. high-energy mechanism of injury,
2. valvular heart disease,
3. lymphedematous tissue,
4. signs of wound infection,
5. contaminated wounds that are closed primarily, and
6. wounds with devitalized tissue.

### *Muscle and Tendon Injuries*

Most muscle injuries are minor (strain) and complete disruption of the muscle fascicles is unusual. Completely severed muscles require meticulous surgical repair. Most muscle injuries are treated by an initial short period of immobilization followed by active range of motion exercises. Overly aggressive rehabilitation and physical therapy may increase fibrosis and precipitate myositis ossificans.

Tendon injuries and lacerations are best treated by early surgical repair. The diagnosis of tendon injuries in the child with a lacerated hand or wrist can be difficult or impossible because the child is frequently crying, frightened, and uncooperative. Physical findings are frequently unreliable and delayed diagnosis is common. Primary repair is the treatment of choice. If this cannot be accomplished, the skin should be closed and an elective secondary repair is performed within 2-3 days.

## Fractures

Children have anatomic and physiologic features that alter the pattern of fractures observed when compared to adults. The primary anatomic difference is the presence of growth centers that vary with age of development. Pediatric bone is relatively soft making it resistant to fracture but more prone to compression or collapse as seen with "greenstick" or "elevation (torus)" fractures. The periosteum is thicker and more elastic in children than in adults, which also contributes to a relatively greater number of fractures demonstrating periosteal elevation rather than displacement. Healing of fractures occurs at a faster rate in children than in adults. Fractures involving active growth centers (see Epiphyseal and Physeal Injuries) in children may cause growth failure, severe shortening, or abnormal angulation. In most pediatric fractures, growth is stimulated. Children between 2 and 14 years of age with long bone fractures are at risk of limb overgrowth.

Initial management of fractures includes splinting and immobilization. Immobilization reduces pain and minimizes or prevents further soft tissue injury. Splinting should be performed in the emergency department prior to transport for additional studies or procedures. Tight circumferential bandages are avoided in traumatically injured extremities. Pain associated with fractures is often severe and narcotic analgesia is usually necessary, particularly prior to reduction. If large doses of narcotics are used, the child must be monitored for signs of respiratory depression.

Orthopedic surgeons most often provide definitive treatment of pediatric fractures and early consultation is advisable. Two-view radiographs (AP and lateral) to include joints both proximal and distal to the fracture site are obtained. Prior to contacting the orthopedic consultant, it is useful to obtain information regarding the neurovascular status of the involved limb, the complexity of the fracture (i.e., open vs. closed, simple vs. comminuted, displaced vs. nondisplaced), and mechanism or energy/force of injury. Joint involvement should also be assessed.

Most fractures in childhood are treated with cast immobilization. Healing in children is rapid and joint immobilization is less of a problem in children than adults. Displaced fractures that are in close proximity to joints commonly require closed reduction or open reduction with internal fixation. Fractures on both sides of a joint frequently require internal fixation. Femur fractures in children are currently managed using several treatment options including:

1. simple casting,
2. skeletal traction,
3. external fixation,
4. plate and screw fixation,
5. intramedullary (IM) rod insertion, and
6. others.

IM rod insertion is avoided in children less than 10 years of age to prevent damage to the greater trochanteric physis.

Open fractures are always treated in the operating room under general anesthesia. Wound cultures are obtained and intravenous antibiotics are started early. Operative management of open fractures includes meticulous debridement, thorough irrigation, and fixation of the fracture. Delayed wound closure at 42-72 hours after the initial debridement is recommended.

Childhood fractures require close radiographic follow-up to assure that reduction is maintained. Casts may need to be changed often to maintain appropriate alignment of the healing fracture. All fractures should be followed at least 6-12 months after injury to identify potential growth disturbance.

### *Epiphyseal and Physeal Fractures*

The Salter-Harris classification is the radiographic classification system most commonly used to describe physeal injuries in children (Fig. 27.1). Type 1 fractures are usually the result of shearing or avulsion forces and are identifiable as separation of the epiphysis from the metaphysis. This type of injury is most commonly observed in young children but may be found in neonates as a birth-related injury. Type 1 fractures are relatively easy to treat, reduce easily, and heal quickly. Long-term prognosis is excellent because the vascular supply to the epiphysis and physis is not disrupted. Growth is not impaired.

Type 2 fractures are the most common physeal fracture of childhood. The fracture line extends along the physis and crosses the metaphysis producing a metaphyseal fragment. This injury also results from shearing or avulsive force injury. Type 2 fractures are most commonly identified in children beyond 10 years of age. Like Type 1 fractures, the blood supply remains intact and healing is rapid. Although rare, growth arrest can occur with this type of injury. The treatment for Type 1 and Type 2 fractures is closed reduction and casting.

In Type 3 fractures, the fracture line extends along the physis and crosses through the epiphysis to involve the articular surface of the epiphysis. This type of fracture results from shearing or avulsion forces applied to a ligament attached to the epiphyseal fragment. This type of fracture frequently disrupts the vascular supply to the epiphysis and can lead to partial growth arrest. Open reduction and fixation is commonly required with Type 3 injuries.

Type 4 fractures extend through the epiphysis, physis and metaphysis. Like Type 3 fractures, this is an intra-articular fracture. The fracture fragments are often completely separated which may cause the physeal plate to be offset. The blood supply is frequently compromised which may lead to delayed healing or nonunion. Open reduction is necessary to reduce the chance of growth disturbance or premature physeal arrest.

Type 5 fractures result from crush injury to the physis from axial loading forces. These injuries are easily missed because they are clinically stable and may have no associated radiographic findings. They are frequently associated with an ipsilateral diaphyseal fracture. Growth arrest at the involved physis frequently leads to deformity and mismatched extremity length. Treatment may require extensive procedure including bone lengthening, contralateral bone arrest, or bone shortening procedures.

### *Tetanus Prophylaxis*

Tetanus infection, although rare, is most likely to occur following puncture wounds, dirty lacerations, and crush injuries in children with incomplete immunization. In the United States, children currently receive the tetanus immunization series before 7 years of age. Children with clean minor wounds who have completed the primary series of tetanus toxoid or have received a tetanus booster dose within 10 years require no additional therapy. If the immunization history is uncertain or

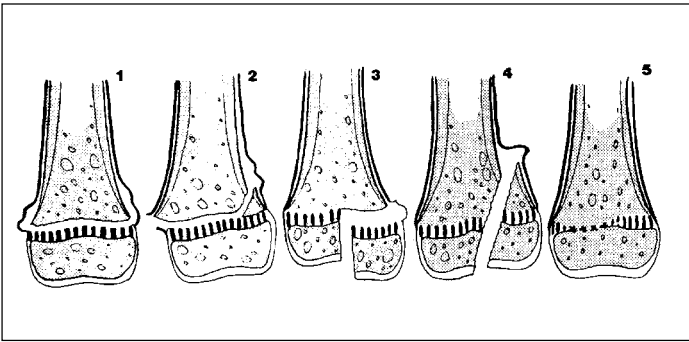


Fig. 27.1. Salter-Harris classification of physeal injuries and fractures.

unknown or more than 10 years have elapsed, a booster dose of tetanus toxoid is administered. For serious or contaminated wounds, a booster dose of tetanus toxoid is administered if one has not been administered within the previous five years. If the immunization history is unknown, children with puncture wounds or contaminated wounds should receive tetanus immune globulin in addition to a booster dose of tetanus toxoid.

### *Selected Readings*

1. Sullivan CM, Stasikelis P, Warren FH. Extremity trauma. In: Arensman RM et al, eds. *Pediatric Trauma: Initial Care of the Injured Child*. New York: Raven Press 1995; 139-157.
2. Salter RB, Harris WR. Injuries involving the epiphyseal plates. *J Bone Joint Surg* 1963; 45A:587-622.
3. Rowe MI, O'Neill Jr. JA, Grosfeld JL et al. Musculoskeletal injuries. In: Rowe MI, O'Neill Jr. JA, Grosfeld JL et al, eds. *Essentials of Pediatric Surgery*. St. Louis: Mosby-Year Book 1995; 214-219.
4. Shafi S, Gilbert JC. Minor pediatric injuries. *Pediatr Clin North Amer* 1998; 45:831-851.
5. Kao SC, Smith WL. Skeletal injuries in the pediatric patient. *Radiol Clin North Amer* 1997; 35:727-46.

# Facial Injuries

*Bahram Ghaderi and Diane Dado*

## Incidence

Maxillofacial trauma in the pediatric population presents many challenges. Although the management principles are the same for all age groups, the reconstruction techniques required for children must take into consideration their developing anatomy, rapid healing, emotional immaturity and their long term potential for deformity as a consequence of altered facial growth.

Numerous studies report the incidence of facial trauma in children as lower than in adults. Pediatric facial fractures account for 1.5-15% of all facial fractures. Most studies suggest an overall male preponderance, especially among adolescents. Children under 5 years of age have a significantly lower risk of facial fracture only accounting for 1-1.5% of the total. However, most data was collected prior to wide availability of computed tomography (CT). It is likely that the incidence of pediatric facial fractures is significantly higher than reported.

The nose and the mandible are the two most prominent features of the pediatric face and are the structures most often fractured in children. Midfacial fractures are rare in children. Associated injuries are common which reinforces the importance of a complete initial assessment.

## Etiology

There are many causes of pediatric facial injuries. They include traffic related accidents, falls, sports injuries, and child abuse. Child abuse is a rare cause but should be considered in every case, especially in children with recurrent injuries.

## Clinical Presentation

The diagnosis of pediatric facial fractures can be problematic. The clinician must have a high index of suspicion, especially when other major injuries are present. Children are frequently uncooperative with history and physical exam. At times general anesthesia is needed to properly examine and evaluate a pediatric trauma patient. History must often be obtained from parents or observers. Photographs of the child before the incident are sometimes helpful, as are dental records, including any models, from the child's dentist or orthodontist.

Survey of the head and neck should proceed in an orderly fashion. First, the neurological status of the child is assessed by evaluation of the neck, cervical spine, inspection of the eyes, otoscopy, rhinoscopy and finally examination of the face and oral cavity. Important parts of this include assessing function of the fifth nerve and

motor function of the seventh nerve. Facial skeleton examination begins with inspection followed by manual palpation. Facial asymmetry with edema, ecchymosis, periorbital swelling, trismus, and malocclusion are all signs that suggest facial fracture. A complete ophthalmologic and neurologic evaluation is important because of a high incidence of associated injuries to the eyes and nerves of the face.

### Diagnosis

With the advent of the CT scan pediatric facial fractures are no longer difficult to identify. Plain x-rays consistently underdiagnose pediatric facial fractures. Because of higher ratio of cancellous to cortical bone in children, there is higher incidence of "greenstick" type fractures. CT provides detailed information on soft tissue and bony structure with the added capability for three-dimensional reconstruction.

### Pathophysiology

Unlike the adult, the pediatric facial skeleton is a dynamic and evolving structure. A child's face has protective anatomic characteristics that reduce the likelihood of facial fractures. Eighty percent of cranial growth occurs during the first years of life. Although facial growth is also rapid during this phase, only after age 2 does the face begin to grow faster than the skull. The orbit and the brain nearly complete their growth by age 7. Lower facial growth continues into early adulthood. Because children have a high craniofacial ratio, the incidence of skull fractures is higher than that of severe midfacial fractures. In children the facial bones are not weakened by the development of the paranasal sinuses, adding further relative protection from facial fracture. Immature bone has greater elasticity which explains the higher incidence of greenstick fractures in children as compared with adults. The pediatric mandible and maxilla are also rendered more resistant to fractures by the presence of unerupted teeth.

### Treatment

The basic principles of trauma management in the initial assessment of children with facial fractures is followed. Hypovolemic shock can result from blood loss from the highly vascular face of a child. This is a double threat because much of the blood can be lost in the airway. A variety of airway interventions are available. Oral intubation is favored over cricothyrotomies and emergent tracheotomies in the emergency department. If necessary, tracheotomies should be done in the operating room. Once the patient is stabilized from life threatening injuries, a definitive operative plan can be made for reconstruction of facial injuries.

Rigid fixation has greatly improved results in adult facial fractures. Unfortunately, this technique can not be applied indiscriminately in children as it may impair facial growth. There is evidence that the pediatric skeleton has considerable ability to remodel after injury. Conservative management of most facial injuries is warranted. Rigid fixation should be used with caution and reserved for fractures that cause the original features to be difficult to restore by other methods.

Wide versus limited exposure is another controversial issue. Complete exposure of the fracture site is one of the basic tenets of maxillofacial trauma, but some suggest that wide subperiosteal undermining may contribute to restriction of bone growth

from a scarred soft-tissue envelope. Until more experience is accumulated it is reasonable to limit exposure to a minimum to decrease any potential for further injury.

Alloplastic materials are not recommended for use in children. Autogenous bone harvested from the cranium provide excellent material for reconstruction. The timing of bone grafting in children is controversial and should be reserved for severe deformity. It is important in the setting of a severe fracture to discuss with the parents the possibility of secondary reconstructive procedures.

The mixed dentition in children presents a unique challenge for reconstruction. The mandible and the maxilla are filled with tooth buds in various stages of eruption. Injuries to this region can result in maldevelopment of permanent dentition. Extreme care must be taken to avoid further injury by limiting debridement and manipulation.

### *Selected Readings*

1. Kolati PT, Rabkin D. Management of facial trauma in children. *Pediatr Clin North Am* 1996; 43(6):1253-1275.
2. Bantz ML. Pediatric facial fractures. In: *Pediatric Plastic Surgery*. Appleton & Lange, 1997.
3. Ehrlich FE, Heldrich FJ, Tepas III JJ. Craniofacial Injuries. In: *Pediatric Emergency Medicine* Aspen: 1987.



# Head and Spinal Cord Injuries in Children

*David Bentrem*

## Head Injuries

### *Incidence*

Trauma accounts for nearly one third of all pediatric surgical admissions, and approximately one half of these children will have sustained a head injury. One child in 10 will suffer a significant head injury during school years, of which one third require hospitalization. Boys are injured at a rate almost twice that of girls. The peak age incidence for traumatic head injury occurs in teenagers.

Over 85% of brain injuries sustained in childhood are not life threatening. The most common mechanism of head injury in children is falls. The two major causes of severe brain injuries in children are motor vehicle accidents and child abuse. Child abuse is the predominant mechanism of head injury in children less than two years of age. Nonaccidental trauma is suspected and fully evaluated whenever a child presents with brain injury inconsistent with the reported mechanism of injury.

### *Clinical Presentation*

The hallmark of traumatic brain injury is an altered level of consciousness. Both the duration of unconsciousness and the duration of posttraumatic amnesia correlate with injury severity and outcome. The most widely used coma scoring system for head injury is the Glasgow coma scale (GCS). This scale is useful for all age groups, but the verbal score must be modified for children younger than four years (Table 29.1). Traumatically injured children with a GCS of 8 or less have usually sustained severe brain injuries. Children with a score of 9-12 often have moderate brain injuries and are at risk for neurologic deterioration. The majority of head injured children present with a GCS of 13-15 and only mild brain injuries, but still there remains a small, but significant, risk for neurologic deterioration. Cranial nerve abnormalities can result from fracture of the skull base. Clinical signs of basilar skull fracture include "raccoon eyes" ecchymosis, hemotympanum, and cerebrospinal fluid leak (i.e., otorrhea, rhinorrhea).

Children who have sustained a minor impact with no loss of consciousness, and who are appropriately responsive shortly thereafter, are unlikely to have a serious brain injury and can be released to a responsible and informed guardian after a period of observation. However, the presence of other signs or symptoms, including lethargy, irritability, vomiting, headache, or scalp swelling require further assessment of injury. The lack of an adequate history favors hospital admission for observation.

**Table 29.1. Modified Glasgow coma scale (GCS) for age < 4**

	Score
<b>Eye Opening (E)</b>	
Spontaneous	4
To speech	3
To pain	2
None	1
<b>Best Motor Response (M)</b>	
Obeys commands	6
Localizes pain	5
Normal flexion (withdrawal)	4
Abnormal flexion (decorticate)	3
Extension (decerebrate)	2
None (flaccid)	1
<b>Verbal Response (V)</b>	
Appropriate words, social smile, fixes and follows	5
Cries, but consolable	4
Cries, persistently irritable	3
Restless, agitated	2
None	1

Coma Score = E + M + V

### *Diagnosis*

Radiographic studies provide essential information for evaluation of the severity of injury. For clinically well-appearing patients, computed tomography (CT) can be used to identify anatomic lesions as determine risk for deterioration (i.e., subdural hematoma, epidural hematoma, etc.). Early and aggressive intervention can dramatically improve the outcome when instituted before clinical deterioration. It is prudent to obtain CT scans on all children admitted with the diagnosis of head injury. A normal CT scan after head injury is a significant indicator of good outcome.

### *Treatment*

An awake child is admitted to an area where close monitoring of level of consciousness, vital signs, and movement of extremities can be performed. Some children will require intravenous fluids secondary to persistent vomiting. The intake, output, and electrolytes of these children should be measured and monitored closely. A syndrome of inappropriate antidiuretic hormone (SIADH) release and less commonly diabetes insipidus are sometimes observed in children following head injury. Confusion, alteration in level of consciousness, and seizures result from severe hyponatremia.

The initial management of the child with a severe head injury requires establishing a stable, controlled airway. Endotracheal intubation with a nondepolarizing muscle relaxant is performed using in-line cervical traction. All children with severe head injuries are assumed to have a spine injury and maintained in cervical collars until proven otherwise. Serial blood gases are acquired to verify adequate oxygenation and ventilation. Tissue hypoxia and hypercarbia compound any intracranial insult.

Hyperventilation leads to cerebral vascular constriction and is a relatively safe and effective, short-term method to rapidly reduce intracranial pressure.

Acute, expanding extracerebral hemorrhagic lesions causing mass effect are neurosurgical emergencies. Epidural hematomas occur following injury of the middle meningeal artery. They occur more commonly in young people because the dura is not as tightly adherent to the skull. Neurologic outcomes following craniotomy for epidural hematomas correlate with the presence or absence of coma at the time of surgery. Acute subdural hematomas develop from tearing of cortical bridging vessels that frequently result in expanding intracranial masses. As with epidural hematomas, increased intracranial pressure (ICP) often necessitates immediate surgical evacuation. Penetrating injuries and compound skull fractures are also neurosurgical emergencies. As a general rule, skull fractures depressed the thickness of the skull or more are reduced operatively.

For nonsurgical lesions systemic and intracranial pressure monitoring are important. An arterial line allows for monitoring of systemic arterial pressure so that cerebral perfusion pressure (the difference between mean arterial pressure and ICP) can be calculated. A cerebral perfusion pressure of 50-60 mm Hg is ideal. Elevated intracranial pressures frequently require therapeutic intervention to prevent secondary brain injury. Unconscious patients and patients with open depressed skull fractures are started on prophylactic anticonvulsant therapy.

The administration of osmotic agents such as mannitol indiscriminately to all patients with severe head injuries is contraindicated. Hyperosmolar agents can dehydrate the normal brain and may allow hematomas or edematous brain to expand. Mannitol is used when there is clinical or radiological suspicion of mass effect, and the patient is clinically deteriorating.

Most importantly, treatment begins with prevention. The majority of brain injuries in children are preventable. Proper use of seat belts in motor vehicles and wearing of helmets for bicycle riding, in-line skating, skiing and other activities reduces the risk of serious head injuries in children.

## **Spinal Cord Injuries**

The child with a spinal cord injury presents similar management issues as the severely head injured patient. Not only can anoxia and ischemia make the primary injury worse, but failure to provide proper initial management may extend the level of irreversible neurologic damage.

### ***Incidence***

In the United States, fewer than 10% of the 8,000 yearly spinal cord injuries occur in children. Approximately 50% of pediatric spinal injuries result from motor vehicle accidents and 25% result from diving-related accidents. The incidence of spinal cord injury increases with age, particularly after the age of 12. Male children are more frequently injured than females (1.6:1). Younger children have disproportionately increased cervical spine injuries secondary to the relative largeness of a child's head compared to torso. Older children have a distribution of spinal injuries that is similar to adults. Thoracolumbar or lumbar spine injuries are uncommon in children and are most frequently associated with lap belt injuries.

### *Clinical Presentation*

Spinal cord injury presents as neurologic dysfunction below the level of suspected injury. Complete or severe injuries result in a symmetrical flaccid paresis or paralysis with accompanying sensory loss. Lesser injuries may present with transient neurologic dysfunction. Any history of neurologic dysfunction involving the limbs or bowel and bladder is strongly suggestive of spinal injury. Cervical spinal cord injuries sometimes cause hypotension and bradycardia from disruption of sympathetic tone.

### *Diagnosis*

The radiographic evaluation of children with a suspected spine injury poses special problems, and alignment is maintained at all times. Any untoward movement may precipitate permanent neurologic damage and dysfunction. It is extremely important to adequately visualize all seven cervical vertebrae when evaluating for cervical spine injury. In unconscious trauma patients with potential for spine injury, the entire spine is evaluated radiographically. Anteroposterior and lateral view plain films are the initial diagnostic screening test. Almost 2/3 of spinal cord injuries in children have no radiographic abnormality on plain films and clinical exam with consideration of the mechanism of injury are important. Prevertebral soft tissue swelling on the lateral cervical spine x-ray is an important and often subtle sign of injury even when no fracture is apparent. Pseudosubluxation, a normal anatomical variant with anterior displacement of C-2 on C-3, is present in 40% of children younger than seven years of age. It can easily be confused with a cervical fracture/dislocation. Lateral lumbosacral plain films are indicated in all children with lap belt injuries before immobilization is removed. CT scan of the spine is helpful for detecting subtle fracture, soft tissue swelling, and rotary subluxations. CT is also useful to evaluate for suspected C-7 and T-1 injuries where plain radiographs often fail to visualize fractures clearly. Magnetic resonance imaging (MRI) is useful to evaluate the extent of the parenchymal cord injury and the relationship of the cord to surrounding structures.

### *Treatment*

Spinal cord perfusion is optimized by restoring and maintaining normal systemic blood pressure and euolemia. Central venous pressure monitoring is helpful. Gastric decompression and elective intubation is performed in patients with respiratory compromise. Early administration of high dose glucocorticoids may improve neurologic outcome in both complete and incomplete spinal cord injuries. Methylprednisolone is administered as a 30 mg/kg bolus followed by a 23 hour infusion of 5.4mg/kg/hr.

The injured spine is maintained in alignment throughout care. The halo device offers an excellent alternative means of managing cervical spine instability in young children. Surgical therapy for reduction and stabilization is necessary in the presence of complex unstable fractures, irreducible subluxations, and penetrating injury.

The most important factor determining the subsequent outcome of spinal cord injury is the initial extent of the injury. Other than preventing further injury, there is little evidence that any surgical or pharmacological treatment improves outcome.

*Selected Readings*

1. American College of Surgeons Committee on Trauma: Advanced Trauma Life Support Instructor Manual, American College of Surgeons. Chicago 1997.
2. McLone DG, Yoon SH. Head and spinal cord injuries in children. In: Raffensperger JG ed. Swenson's Pediatric Surgery, 5<sup>th</sup> edition. Norwalk: Appleton & Lange 1990; 261-275.
3. Bell WO. Pediatric head trauma. In: Arensman RM ed. Pediatric Trauma: Initial Care of the Injured Child. New York: Raven Press 1995; 101-118.
4. Leberte MA, Dunham WK. Thoracolumbar spine injuries in children. In: Arensman RM ed. Pediatric Trauma: Initial Care of the Injured Child. New York: Raven Press 1995; 119-138.

# Abdominal Trauma

*John Hijjawi and Daniel A. Bambini*

## Classification

Abdominal trauma is either blunt or penetrating. Blunt abdominal trauma represents about 84-95% of pediatric abdominal trauma. The most common mechanisms of injury are motor vehicle accidents and falls. The most commonly injured organs are the kidneys, spleen, and liver. Penetrating trauma is less common (5-15%), usually occurs in adolescents and teenagers, and is more common in urban areas. The most common mechanisms of injury are stab wounds, gunshot wounds, and impalement injuries. The most commonly injured organs are liver, small bowel, and colon.

## Assessment

A team approach is the most efficient means to assess (Chapter 28) and stabilize a critically injured child. The team consists of a pediatric surgeon (team leader), a pediatric anesthesiologist (airway management), and two nurses. The team is assembled in the trauma room prior to the arrival of the patient. While waiting, the team leader contacts the transport team, assigns resuscitation duties, and insures that all team members observe universal precautions. Important prehospital information includes time of the accident, mechanism of injury, condition of other victims, estimated blood loss at the scene, vital signs, a list of possible injuries, and any treatment given en route. The team leader should verify allergies, medications, past medical history, the child's last meal, and events surrounding the injury.

Dividing the abdomen into three nonanatomic areas allows the surgeon to generate a list of potential organ injuries and the need for diagnostic tests. The intraabdominal abdomen is defined by the anterior axillary line laterally, the costal cartilages superiorly, and the pubis inferiorly. It contains portions of the large and small bowel, hepatobiliary system, spleen, stomach, and urinary bladder. The intrathoracic abdomen is between the 4<sup>th</sup> intercostal space superiorly and the costal margin inferiorly. It contains segments of the liver, spleen, stomach, and colon. The retroperitoneal space is defined by the posterior axillary lines laterally and the fourth intercostal space superiorly. It contains the great vessels, duodenum, pancreas, ascending and descending portions of the colon and the genitourinary system.

The abdominal exam begins with visual inspection looking for evidence of penetrating injuries, seatbelt marks, abrasions, or retained projectiles. The perineum is inspected for ecchymosis, hematomas and blood at the urethral meatus. The flanks, back and buttocks are also inspected. Lacerations and/or blood near the vagina or

anus raises the suspicion of abuse. Palpation begins in an area without obvious injury. The surgeon is sensitive to subtle signs of tenderness, rebound, or guarding

The child is log-rolled and the back, spine, buttocks, and anus visually inspected and palpated for tenderness or deformities. The rectal examination is performed last. The purpose of this examination is to assess sphincter tone, mobility and position of the prostate, rectal wall integrity, and for the presence of gross blood.

### Diagnostic Evaluation

Unless an indication for immediate celiotomy exists (Table 30.1), definitive diagnosis requires imaging. Computed tomography (CT) is the preferred radiographic examination for blunt trauma. It is relatively quick, noninvasive, and very specific for solid organ injuries. However, CT requires the child to leave the trauma room, be exposed to radiation, and cooperate. CT is essential to successful nonoperative management of blunt pediatric abdominal trauma.

Ultrasonography is used in the trauma room to screen for solid organ injury. Free, intraabdominal fluid suggests solid organ injury or intestinal perforation and requires an abdominal CT and admission. Compared to CT, U/S is portable, faster, less expensive, easy to repeat, and has no radiation. However, U/S is operator-dependent and nonspecific.

Although the indications for diagnostic peritoneal lavage (DPL) are the same for children and adults, DPL is performed less frequently in children. The technique and interpretation is the same for both groups. Warm Ringer's lactate (10 mL/kg up to a maximum volume of one liter) is instilled, drained from the peritoneal cavity, and sent for cell count, bilirubin, and amylase. Indication for laparotomy are the same as adults (Table 30.2). Compared to CT, DPL is quicker and more sensitive test for intraabdominal injuries. However, it is invasive, nonspecific, does not evaluate the retroperitoneum, and leads to an increase in nontherapeutic laparotomies.

### Splenic Injuries

Splenic injuries are the most common cause of intraperitoneal bleeding. The severity of the injury is graded on CT scan. Grade I is a subcapsular or intraparenchymal hematoma without capsular disruption. Grade II is a parenchymal fracture outside of the hilum. Grade III is a fracture that enters the hilum and grade IV is a shattered spleen. Most children with an isolated splenic injury can be managed nonoperatively. This requires 24-48 hours of monitoring in the pediatric intensive care unit, serial physical examinations, serial hemoglobins, and blood replacement. The child is transferred to the floor when he is hemodynamically stable and not requiring blood transfusion. On the floor, the child is kept on bed rest and started on a diet. Most children are ready for discharge between 7 and 10 days. Indications for laparotomy include blood transfusion > 40 cc/kg (or half the child's blood volume) and a suspected intestinal perforation. At operation, splenic salvage (i.e., splenorrhaphy, partial splenectomy) is possible in over 50-60% of children. Indications for splenectomy include patient instability, associated life-threatening injuries, and grade IV injuries. Splenectomized children are vaccinated against *Pneumococcus* and *Hemophilus influenza* and placed on penicillin to decrease the risk of OPS (overwhelming postsplenectomy sepsis). In addition, parents are told about the risk of OPS and to seek medical attention at the first sign of infection.

**Table 30.1. Indications for laparotomy**

1. Refractory hypotension despite adequate fluid resuscitation.
2. Blood transfusion requirements totaling half the patient's estimated blood volume.
3. Pneumoperitoneum.
4. Positive DPL. (see Table 30.2)
5. Obvious peritonitis on initial or subsequent physical examination.
6. Abdominal distension with associated hypotension.
7. Diaphragmatic injury.
8. Evidence of intraperitoneal bladder rupture on cystography.
9. Evidence of abdominal penetration with gunshot wound to abdomen. No attempt should be made to predict missile trajectory.
10. Evidence of posterior fascial penetration on local exploration of abdominal stab wounds.

**Table 30.2. Interpretation of diagnostic peritoneal lavage (DPL)****Positive lavage if one or more are present:**

1. Aspiration of more than 10 cc gross blood.
2. Grossly bloody lavage fluid.
3. Amylase level of greater than 175u/dl
4. RBC count: >100,000/mm<sup>3</sup> (blunt trauma) or >50,000/mm<sup>3</sup> (penetrating trauma).
5. Presence of bile, stool, or bacteria.

**Liver Injuries**

Liver injuries are the second most common cause of intraperitoneal bleeding and a leading cause of mortality in children with blunt abdominal trauma. Injury severity is graded on CT into one of 6 grades. Grade I is a subcapsular hematoma that is < 10% of the liver surface area or a nonbleeding, < 1 cm laceration of the liver. Grade II is a subcapsular hematoma that covers 10-50% of the liver or a small (< 2 cm), nonexpanding, intraparenchymal hematoma. Grade III is a subcapsular hematoma > 50% of the liver, a bleeding subcapsular hematoma, an intraparenchymal hematoma > 2 cms or a laceration of the parenchyma > 3 cms. Grade IV is a ruptured central hematoma or laceration involving 25-75% of one lobe. Grade V is a laceration involving > 75% of a lobe or hepatic vein injury. Grade VI is hepatic avulsion. Like splenic injuries, most pediatric liver injuries are less severe (Grades I, II, III) and can be managed using a nonoperative approach. Indications for operation include > 50% blood volume replacement and hemodynamic instability. The surgical principles used in the management of complex (Grade III, IV, and V) liver injuries include maintenance of large bore IV access, prompt replacement of blood products, the use of steroids (30 mg/kg bolus), maintenance of normothermia, manual compression of the injury to control blood loss, occlusion of the porta hepatis (Pringle maneuver), finger fracture of devitalized liver to allow direct ligation of bleeding vessels, debridement of devitalized tissue, and abdominal packing with re-exploration in 24-48 hours for uncontrollable, life-threatening bleeding.



## Pancreatic Injuries

Pancreatic injuries are also uncommon and frequently occur in association with other injuries. Blunt trauma (70%) is more common and usually the result of motor vehicle accidents, handle-bar injuries, or sharp blows to the epigastrium. Penetrating injuries are less common (30%). Pancreatic injuries are graded as contusions (grade I), minor lacerations (grade II), suspected pancreatic ductal injury (grade III), or severe crush injuries (grade IV). Grade I and II injuries are managed nonoperatively. Grade III injuries are investigated with preoperative ERCP to rule out a ductal injury. Partial disruptions can be managed nonoperatively, but complete disruptions usually require distal pancreatectomy. Grade IV injuries require debridement of devitalized tissue, external drainage, and treatment of associated injuries. Rarely, Roux-en-Y pancreaticojejunostomy or pancreaticoduodenectomy are required.

## Intestinal Injuries

Intestinal injury is seen in blunt (up to 18%) and penetrating (> 60%) abdominal trauma. Signs and symptoms include abdominal pain, abdominal distension and tenderness, and vomiting. However, 16% of children are asymptomatic. Laboratory tests are not helpful and up to 60% of children do not have free air on plain film or CT. The presence of free fluid in the abdomen without solid organ injury suggests intestinal injury and has been used as an indication for operation in adults. Another option is to admit the child for serial examinations. Indications for operation include signs of peritonitis, extravasation on UGI or CT, free air, or a positive DPL.

## Selected Readings

1. Svoboda JA et al. Severe liver trauma in the face of coagulopathy: A case for temporary packing and re-exploration. *Am J Surg* 1992; 144:717-721.
2. Haller JA. The current status of nonoperative management of abdominal injuries in children and young adults. *Am Surg* 1998; 64(1):24-27.
3. Jerby BL et al. Blunt intestinal injury in children: The role of the physical examination. *J Pediatr Surg* 1997; 32(4):580-4.
4. Patrick DA et al. Ultrasound is an effective triage tool to evaluate blunt abdominal trauma in the pediatric population. *J Trauma* 1998; 45(1):57-63.
5. Almond PS et al. Abdominal trauma in children. In: Arensman RM, et al eds. *Pediatric Trauma: Initial Care of the Injured Child*. New York: Raven Press 1995; 79-100.
6. Stylianos S. Controversies in abdominal trauma. *Sem Ped Surg* 1995; 4(2):116-19.

# Genitourinary Trauma

*Kate Abrahamsson and Fawn C. Lewis*

## Renal Trauma

### *Incidence*

About 90% of all renal injuries in children are due to blunt injury and approximately 10% of all pediatric blunt abdominal trauma involves the kidney.

### *Symptoms*

Contusion is the most common renal injury in children. Flank pain or tenderness and hematuria (microscopic or gross) are the most common findings. Abdominal tenderness, flank mass, hematoma over the flank, or fractured ribs are important signs suggesting the presence of renal trauma.

Hematuria is not always present despite severe renal injury. Children with renal pedicle injuries and/or pedicle disruptions sometimes present without hematuria. Thus, the degree of hematuria does not correlate with the severity of the injury.

### *Diagnosis*

The most sensitive and specific test to evaluate blunt renal trauma is computed tomography (CT) with intravenous contrast. If the patient is unstable or requires immediate surgery, a "one shot" intravenous pyelogram, is helpful to provide information about a suspected renal injury and/or contralateral renal function.

### *Treatment*

Microscopic hematuria in a single urinalysis without associated clinical findings is followed with repeat urinalysis. Persistent microscopic hematuria requires evaluation. Gross hematuria as a result of blunt trauma is evaluated by CT, and if there is no extra-renal indication for operation, the patient is admitted, placed at bedrest, and followed for resolution of the hematuria. Serial abdominal CT scans or ultrasound is helpful to evaluate for stability and resolution of hematomas. Short term complications (secondary bleeding, abscesses, urinomas) and long term complications (arteriovenous fistulae, encysted hematomas, hypertension) are most often seen after injuries with devascularization of segments of parenchyma, extensive hemorrhage and urinary extravasation. Extensive renal injuries sometimes require operative intervention (i.e., repair, nephrectomy, drainage).

## Ureteral Trauma

Ureteral trauma in children is an uncommon injury. Severe flexion or deceleration is the usual mechanism for ureteropelvic avulsion and children with these injuries are evaluated urologically by CT scan with intravenous contrast. It is important to remember that hematuria is rarely seen with ureteral injury. The treatment of this lesion is immediate surgical repair.

## Bladder Trauma

### *Incidence*

Bladder rupture is seen in 10-15% of all patients with pelvic fracture but also occurs without pelvic fracture after severe blunt force to the abdomen with a distended urinary bladder.

### *Symptoms*

The usual symptoms and signs of bladder rupture are diffuse lower abdominal pain and tenderness and microscopic hematuria. If blood is present at the urethral meatus, injury of urethra or bladder neck is considered and retrograde urethrography is performed prior to insertion of a catheter into the bladder.

### *Diagnose*

Bladder rupture is diagnosed by cystogram. Oblique and postevacuation views are required.

### *Treatment*

Extraperitoneal bladder rupture is managed by catheter drainage. Cystography is performed after 7-10 days. If there is no extravasation, the catheter can be removed. If there still is extravasation the catheter is left in place an additional 7 days and cystography is repeated. If a laparotomy is performed for other intra-abdominal and pelvic injuries, a suprapubic catheter is placed through a small cystostomy incision to allow decompression and drainage. Intraperitoneal bladder rupture requires laparotomy. This injury is usually occurs in association with injury of other intraperitoneal organs. Intraperitoneal urine is rapidly absorbed leading to azotemia and acidosis. A suprapubic catheter and a urethral catheter are inserted. Cystography is performed after 7-10 days. If there is no extravasation the urethral catheter is removed and the suprapubic catheter is left until normal voiding is established.

## Urethral Trauma

### *Incidence*

Urethral trauma is divided into posterior and anterior urethral injuries. Posterior urethral trauma is associated by severe blunt trauma. About 5% of males with pelvic fractures have injuries to the posterior urethra and 10-30% of these patients also have bladder rupture. Any child with known or suspected pelvic fracture must also be suspected of having injury to the lower urinary tract. Anterior urethral injuries are rarely associated with pelvic fracture but most often occur following straddle injuries or direct trauma to the perineal area where bulbous urethra is compressed against the ischial rami.

### *Symptoms*

Children with disruption of the urethra usually have a palpable bladder and are unable to void. Frequently, blood is identified at the urethral meatus. For posterior urethral injuries, rectal examination may reveal a pelvic hematoma. Anterior urethral injuries are frequently associated with perineal or scrotal swelling and perineal hematoma.

### *Diagnosis*

Urethral injuries are evaluated with retrograde urethrocystogram. No further instrumentation of the urethra is performed in boys. In females, the urethra and the bladder neck are best evaluated by cystoscopy.

### *Treatment*

A suprapubic catheter is inserted to drain the urinary bladder and antibiotics are administered. Urethral reconstruction is generally not performed until the acute inflammatory process and hematoma have resolved. Complications of urethral injury include stricture, incontinence and impotence.

## **Scrotal Trauma**

### *Incidence*

Trauma to scrotum occurs infrequently and severe injuries are unusual because of the size and mobility of the testes in boys. Injury occurs when the scrotum is compressed against the inferior pubic ramus.

### *Symptoms*

The diagnosis is obvious as pain and swelling of scrotum occur quickly. Testicular torsion can cause symptoms similar to those observed after scrotal trauma. Other causes for painful scrotum are torsion of appendix of the testis, epididymitis, contusion of the scrotal wall and scrotal hematocele with or without rupture of the testis.

### *Diagnosis*

Scrotal ultrasonography is helpful but can never absolutely exclude the diagnosis of testicular torsion.

### *Treatment*

For scrotal wall contusion without testicular injury, symptomatic treatment is recommended. If the testicle is ruptured or a large hematocele is observed or, exploration is indicated to repair the torn tunica albuginea, control bleeding, drain any hematocele and salvage the testis if possible. Testicular exploration is also indicated if testicular torsion is suspected. Antibiotics are administered to avoid secondary infection. Penetrating injuries require debridement if tissue damage is extensive.

## **Labial Trauma**

Straddle injuries may cause severe hematomas and labial trauma. Anesthesia is often required to perform an adequate investigation of vagina and/or urethra. When the hematoma is extensive, there is a risk for urinary retention and urethral catheter drainage is indicated.

## Penile Trauma

Injury to the penis in children is unusual and is most commonly seen after zipper injuries or after the toilet seat falls while the boy is voiding. Operation is rarely needed. Gentle cleansing three times a day is usually the only treatment needed to prevent secondary infection. Severe injuries to the penis are rare and an individualized surgical approach is needed sometimes requiring microvascular repair and skin grafting.

## Sexual Abuse

Sexual abuse is always suspected in children with injuries to the perineal area. Signs in boys include contusion and laceration of penis or scrotum and crush injuries to the testis in boys. In girls, the signs of sexual abuse are labial contusion with introital laceration and bleeding.

## *Selected Readings*

1. Gonzales ET, Guerriero WG. Genitourinary trauma. In: Kelalis PP, King LR, Belman AB eds. *Clinical Pediatric Urology*, 2nd Edition. Philadelphia: W.B. Saunders 1985; 1125–1156.
2. Guice III SL. Urologic Trauma. In: Arensman RM ed. *Pediatric Trauma: Initial Care of the Injured Child*, New York; Raven Press 159–172.
3. Livne PM, Gonzales ET. Genitourinary trauma in children. *Urol Clin North Am* 1985; 12:53–65.

# Thoracic Trauma

*Matthew L. Moront*

## Introduction

Although thoracic injury is uncommon in children, it is associated with mortality rates of 20-30%. Sixty to 80% of children sustaining thoracic trauma have associated injuries and nearly half of these children have concomitant head injury. There is a dramatic difference in the mortality rate of children who sustain thoracic trauma (10-15%) compared to those without thoracic trauma (1-2%). The mortality rate for children sustaining isolated chest trauma is approximately 5%. The majority of children with thoracic injury who die do so as a result of traumatic brain injury.

There are several differences in the types of chest injuries sustained by children as compared to adults. The bones in children are more cartilaginous and pliable, and thus will bend farther before they break. Therefore, children fracture ribs less commonly than adults but are twice as likely to sustain pulmonary contusions. Pulmonary contusion is the most common thoracic injury in children. While pneumothorax is common in both adults and children, the incidence of tension pneumothorax is much higher in children because the mediastinum is more mobile and shifts more easily.

## Immediately Life Threatening Injuries

### *Pneumothorax*

Pneumothorax occurs when air enters the potential space between the visceral and parietal pleuras. Air enters this space from the inside due to a violation of the visceral pleura. Air enters from the outside when the parietal pleura is violated. As air accumulates in the pleural space the lung becomes compressed and the mediastinum shifts away from the side of pneumothorax. With severe mediastinal shift, the venous return to the heart is impaired causing hemodynamic instability and eventual cardiac arrest.

Simple pneumothorax occurs in 30-40% of pediatric thoracic trauma victims. Pneumothorax is most commonly identified in association with a rib fracture but also occurs after blunt or penetrating chest injuries without an associated fracture. Initial symptoms include ipsilateral chest pain, dyspnea, tachypnea, and restlessness. Pulse oximetry is frequently normal despite the presence of a large pneumothorax.

Physical examination reveals absent or decreased breath sounds and hyperresonance to percussion on the affected side and tracheal shift away from the side of the pneumothorax. Jugular venous distention is sometimes observed with tension

pneumothorax, however, this sign is frequently not present in children with hypovolemia. The diagnosis of a tension pneumothorax is clinical; treatment is not delayed while awaiting radiologic confirmation.

Immediate treatment of a tension pneumothorax is needle decompression in the second intercostal space at the mid-clavicular line. Definitive treatment for any pneumothorax is tube thoracostomy in the fourth or fifth intercostal space at the anterior axillary line.

### *Hemothorax*

Hemothorax occurs in 10-15% of pediatric thoracic injuries. The most common cause of a hemothorax is injury to a systemic vessel (i.e., intercostal vessel, internal mammary artery, etc.). Other causes include hemorrhage from the great vessels or the pulmonary hilum (often fatal) and bleeding from the lung parenchyma (5%). As with the diagnosis of pneumothorax, the anterior-posterior radiograph is very helpful for diagnosis. Treatment includes tube thoracostomy which evacuates the blood from the pleural space and expands the lung to tamponade the bleeding.

Children with large hemothoraces require special consideration. Evacuation sometimes reverses the tamponade effect of a large hematoma and results in vascular collapse. Placement of 2 large bore intravenous lines with fluid warmers and the immediate availability of type specific blood and an autotransfusion device is recommended prior to tube thoracostomy. Immediate evacuation of greater than 20 cc/kg of blood or the sustained loss of greater than 2 cc/kg/hr of blood over four or more hours requires exploratory thoracotomy for hemostasis. Failure to evacuate the majority of blood in the pleural space sometimes results in empyema or fibrothorax ("trapped lung") and requires prolonged hospitalization and thoracotomy for treatment.

### *Aortic Injury*

Thoracic aortic injury is an uncommon injury in children and is almost always due to severe deceleration or crush type injury. Injury to the aorta accounts for approximately 2% of the unintentional deaths in children.

Although the risk of traumatic aortic rupture is higher in adults than children, the risk of death from this injury is higher in children. The most common location of aortic injury due to blunt trauma is similar in both children and occurs immediately distal to the takeoff of the left subclavian artery. The descending aorta is fixed at this point, therefore, the shear stress encountered during a sudden deceleration is greatest at this point

Aortic injuries in children are frequently accompanied by multi-system trauma and 75% of the victims do not survive to reach a hospital. Of those children who reach the hospital alive, over 50% will die within 24 hours. The overall mortality for this injury is 90%.

The diagnosis of aortic injury is suspected when there is a history of significant deceleration or crush mechanism of injury accompanied by physical exam findings of profound shock, chest pain, and possible paraplegia. Other signs include hoarseness, dysphagia or spinal injury. Chest radiograph findings suggestive of aortic injury include:

1. mediastinal widening,
2. prominent aortic knob,

3. first rib fracture or scapular fracture,
4. elevated left mainstem bronchus,
5. deviated esophagus (deviated NGT),
6. left pleural effusion, and
7. obliterated AP window.

Children suspected of having aortic injury undergo immediate aortography. Recently, dynamic thoracic computed tomography is gaining increased acceptance in some centers as a sensitive diagnostic modality. Treatment includes emergent thoracotomy, usually through a left posterolateral incision, and direct suture repair.

### *Pericardial Tamponade*

Pericardial tamponade is very rare in children; a history of a penetrating wound or of a severe deceleration is common. Physical signs include tachycardia, hypotension, muffled heart tones and distended neck veins. Children who present in hypovolemic shock will not manifest distended neck veins until very late in the presentation, if at all. Although pulsus paradoxus is a prominent feature in adults with this condition, it is often difficult to assess in an injured child. The diagnosis of pericardial tamponade is suggested by an abnormally elevated or steadily increasing central venous pressure. In the hemodynamically stable child transthoracic echocardiogram confirms the diagnosis. The chest radiograph frequently demonstrates a left pleural effusion or an abnormal cardiac silhouette. In the unstable child, pericardiocentesis provides dramatic relief of symptoms and provides definitive diagnosis. Aspiration of blood that does not easily clot confirms the diagnosis and produces rapid clinical improvement.

### *Flail Chest*

Flail chest occurs when two or more adjacent ribs fractured in two or more places causing the injured segment to move paradoxically in relation to the remainder of the chest wall during respiration. Flail chest is a rare condition in children and most commonly occurs as a result of direct blow to the chest wall. Most children sustaining flail chest injuries also have severe underlying parenchymal injuries and hemorrhage. Physical examination reveals an obvious chest wall deformity with palpable crepitus and discordant chest wall movement. Ecchymosis and severe chest wall tenderness are common. Chest radiograph confirms the diagnosis, although the underlying pulmonary parenchymal injury is not always visible on the initial CXR. Treatment requires aggressive and continuous pain control. Endotracheal intubation is sometimes needed in children who are unable to maintain adequate ventilation or oxygenation. Significant amounts of positive end expiratory pressure (PEEP) helps to stabilize the flail segment and treat the underlying parenchymal injury.

## **Potentially Life Threatening Injuries**

### *Pulmonary Contusion*

Pulmonary contusion is an injury to the lung parenchyma resulting from direct trauma that causes hemorrhage, edema, and dysfunction. Pulmonary contusion is the most common thoracic injury in children. In children, compliant chest walls, decreased thoracic musculature, and cartilaginous ribs allow a significant transfer of



kinetic energy to the lung parenchyma without overlying rib or chest wall injury. The pathophysiology of pulmonary contusion includes alveolar, vascular, and epithelial disruption resulting in pulmonary edema, desquamative alveolitis, and the release of inflammatory mediators. Clinically, children with pulmonary contusion exhibit hypoxia, ventilation-perfusion mismatch, and atelectasis.

Extrathoracic injuries associated with pulmonary contusion include splenic laceration and closed head injury. Associated intrathoracic injuries include mainly hemothorax and pneumothorax which occur in over 50% of the children with significant pulmonary contusion. Children with severe pulmonary contusion are tachypneic, hypoxic, and dyspneic. Yet, the initial physical exam is often misleading and these findings are absent in over 50% of cases. The initial chest radiograph usually reveals patchy infiltrates or a small pleural effusion. The radiographic findings typically worsen over the ensuing 48 hours and correlate with the clinical findings.

Treatment is primarily supportive and involves aggressive pain management and pulmonary toilet. Most children with pulmonary contusion do not require intubation or mechanical ventilation. Children who do require mechanical ventilation have a 2-fold increased risk of pneumonia and an increased incidence of respiratory distress syndrome.

### *Diaphragmatic Injury*

Traumatic diaphragmatic injury is very uncommon in children and accounts for less than 2% of all pediatric thoracic injuries. Over 90% of blunt injuries to the diaphragm occur on the left side. Associated injuries are common, especially to the abdominal viscera and pelvis. In children with blunt diaphragmatic rupture, there is also an increased incidence of head injuries. Diaphragmatic injury is suspected and ruled out in all cases of penetrating trauma below the level of the tip of the scapula or the nipple line.

Radiologic findings suggestive of diaphragmatic rupture include:

1. the tip of the nasogastric tube above the diaphragm,
2. bowel gas or gastric bubble in the chest, and
3. obscured or elevated left hemidiaphragm.

Ultrasonography, computed tomography, and contrast studies have all been used to make the diagnosis of diaphragmatic perforation, but all have high false-negative rates for small perforations. Diagnostic peritoneal lavage, thoracoscopy, or laparotomy are the most sensitive methods to identify diaphragmatic injuries. Treatment is surgical repair.

### *Traumatic Asphyxia*

Traumatic asphyxia is a syndrome consisting of cervicofacial cyanosis and subconjunctival and petechial hemorrhages associated with varying degrees of central nervous system and pulmonary dysfunction. It is rare and accounts for only about one of every 18,000 trauma admissions. It is caused by a sudden and forceful anterior-posterior compression of the chest against a closed glottis. A sudden increase in intrathoracic pressure causes rapid retrograde flow through the valveless jugular system with dilation of capillaries and venules. Neurologic symptoms, including disorientation and agitation, usually clear within 24 hours and permanent disability is unusual. Temporary visual loss secondary to retinal hemorrhages may occur but is

rarely permanent. These children have a characteristic cyanotic hue with marked disparity between the cutaneous appearance of the head, neck, and upper extremities as compared to the remainder of the body. Despite its alarming appearance the survival rate for isolated traumatic asphyxia is over 90%. Associated injuries (i.e., pulmonary contusion, intra-abdominal injuries) are responsible for the majority of deaths. Management includes airway stabilization, head elevation, and prevention of hypoxia. The prognosis for the majority of children with this injury is excellent.

### *Tracheobronchial Rupture (TBR)*

Tracheobronchial rupture occurs in less than 2% of children with thoracic trauma. TBR affects older children with males greatly outnumbering females. The mortality rate in children with TBR is approximately 30% and over half of these children sustain severe associated injuries. The mechanism of injury is thought to be either a sudden shearing force or compression causing a rapid increase in transverse thoracic diameter and disruption of the tracheobronchial tree at fixed points near the carina and cricoid. Nearly 80% of TBR occurs within 2cm of the carina and another 15% occur in the more proximal trachea. The immediate management of children with TBR includes securing the airway, ensuring adequate ventilation, tube thoracostomy. Definitive treatment will usually require surgery. In cases with severe air leak compromising ventilation, a double lumen endotracheal tube or selective contralateral mainstem intubation is often helpful.

### *Esophageal Perforation*

Esophageal perforation is a rare injury in children and occurs as a result of penetrating trauma, foreign bodies, or iatrogenic injury. Children with esophageal perforation at the cervical level may present with torticollis, excessive salivation, and refusal to eat. Eighty-three percent of penetrating esophageal injuries occur in the cervical esophagus and 63% have an associated tracheal injury. Other physical signs include subcutaneous emphysema, fever, shock, and a mediastinal crunch on auscultation (Hamman's sign). Cervical and chest radiographs identify foreign bodies and may show pneumothorax, pleural effusion, or pneumomediastinum. Children with intra-abdominal perforation commonly present with rigidity and tenderness. The diagnosis and treatment is usually surgical although nonoperative management is sometimes possible. Overall mortality is approximately 15% but increases substantially if the diagnosis is delayed beyond 24 hours.

### *Selected Readings*

1. Pecllet MH, Newman KD, Eichelberger M et al. Thoracic trauma in children: an indicator of increased mortality. *J Pediatr Surg* 1990; 25:961-6.
2. Eichelberger MR. Patterns of thoracic injury. In: Eichelberger MR ed. *Pediatric Trauma: Prevention, Acute Care, Rehabilitation*. St Louis: Mosby-Year Book, Inc. 1993.
3. Eichelberger, MR. Trauma to the airway and thorax. *Pediatric Annals* 1987; 16:307-316.
4. Borgen PI, Arensman RM. Pediatric Thoracic trauma: Six immediately life-threatening injuries. In: Arensman RM ed. *Pediatric Trauma: Initial Care of the Injured Child*. New York: Raven Press 1995; 53-63.
5. Hancock BJ, Wiseman NE. Tracheobronchial injuries in children. *J Pediatr Surg* 1991; 29:1316-1319.
6. Ali IS, Fitzgerald PG, Gillis DA et al. Blunt traumatic disruption of the thoracic aorta: a rare injury in children. *J Pediatr Surg* 1992; 27:1281-1284.

# Vascular Injuries

*Daniel A. Bambini*

## Incidence

Pediatric vascular injuries are rare. The exact incidence is unknown. Approximately 1% of patients listed in the Pediatric Trauma Registry have suffered major vascular injuries. Eighty percent of these children are greater than 5 years of age. For penetrating vascular injury, the ratio of males: females is 3:1. Eighty percent of these children are greater than five years old at the time of injury. Only about 50% of these injuries will require surgical repair. The distribution of penetrating vascular injuries by most common site is: upper extremity (50%), lower extremity (31%), visceral (10%), neck (7%). Seventy percent of blunt vascular injuries in children are lower extremity injuries. One half of these are popliteal artery injuries. Brachial artery injury is the most common upper extremity blunt vascular injury.

## Etiology

Pediatric vascular injuries are often the result of iatrogenic trauma. For infants under 2 years of age, catheter related vascular injuries are most common. The predominant mechanism in this group is arterial injury during placement of catheters or diagnostic cardiac catheterization.

For older children and adolescents, vascular injuries result from a wide variety of blunt and penetrating injuries. Penetrating trauma is the mechanism of vascular injury in about 75% of this group. Broken glass lacerations, gun shot wounds, and knife injuries are the three most common types of penetrating injuries leading to major vascular damage. Vascular injury from blunt mechanism occurs less commonly and a high index of suspicion is required to identify these injuries. Crush injuries, displaced fractures, and joint dislocations are the blunt mechanisms most often associated with vascular injuries. About 30% of long bone fractures in children have associated vascular injury. The specific fracture/dislocations having the greatest risk for vascular injury are: mid/distal femur fractures, elbow/knee dislocations, tibial plateau injuries, and midshaft humerus fractures.

## Clinical Presentation

Vascular injury is suspected in all children with penetrating injury near or in proximity to major vessels or severe blunt injuries to the extremities ( i.e., crush, fracture/dislocation at joints, long bone fracture, etc.). The clinical signs of vascular injury are pain, pallor, pulselessness, parasthesia, and paralysis. Massive bleeding from an open penetrating wound is also highly suggestive. Absent pulse(s) distal to

the site of injury is the most conclusive sign of major vascular injury, yet distal pulses remain palpable in at least 20% of children so injured. Delay in diagnosis is common (25%) with vascular injuries of the extremities in children but chronic ischemia is rare (6%) as is the need for amputation (3-4%). Blunt or penetrating trauma can result in a spectrum of pathologic vascular problems including: contusion with vascular spasm, intimal tear, complete or partial transection, pseudoaneurysm, arteriovenous fistula, entrapment, thrombosis. The most common blunt vascular injury is an intimal tear with thrombosis.

## Diagnosis

Although arteriography is commonly used in adults to evaluate suspected vascular injuries, it is infrequently used or necessary in pediatric patients. The complication rate of diagnostic angiography in young children is high; and it should be used very selectively. The diagnosis of vascular injury is for the most part based on clinical judgment; the extent of vascular injury is determined at surgical exploration as indicated.

In general, patients with wounds associated with vigorous arterial bleeding, pulse deficits, or expanding hematomas are taken to the OR expeditiously to control hemorrhage and repair major vascular injury. A penetrating wound in "proximity" to major vessel is not of itself an indication for surgical exploration. Angiography is useful in this group to identify vascular injuries that require operative intervention. In addition angiography is indicated and commonly used to evaluate for major vascular injury with:

1. penetrating zone I or II neck injuries,
2. pelvic fractures with massive bleeding,
3. failure to regain distal pulses after reduction of long bone fracture,
4. multiple penetrating extremity wounds,
5. severe crush injuries,
6. fractures/dislocations at the elbow or knee.

## Treatment

The specific surgical intervention required to treat major vascular injuries depends upon the type of lesion, anatomic location, as well as presence of other associated injuries. The principles of general vascular surgery apply as well to children as to adults. Vessels are repaired primarily whenever possible, but autologous vein or PTFE conduits are necessary or useful at times. Small, nonvital vessels often are simply ligated. Obviously, surgical repair is performed as expeditiously as possible to restore blood flow quickly and limit ischemic tissue damage.

For extremity vascular injuries requiring operative repair, fasciotomy is often necessary to treat or prevent compartment syndrome. Compartment syndrome develops acutely in the postoperative period secondary to ischemia-reperfusion injury of muscle/soft tissue. Early signs of compartment syndrome after vascular repair include increasing severity of extremity pain, increased swelling and tenderness below area of injury, pain increased with passive movement of toes/fingers, compartmental pressures measured greater than 30 mmHg. Fasciotomy should be performed as soon as possible to treat compartment syndrome to limit soft tissue loss and myonecrosis. Early fasciotomy is considered for cases of:

1. combined artery and vein injury,
2. arterial injury with severe soft tissue damage,
3. progressive postoperative edema,
4. prolonged (> 5 hr) cold ischemia time,
5. early signs of compartment syndrome.

### **Outcomes**

Penetrating vascular injuries in children result in amputation in only 3-4% of cases. Blunt extremity vascular injuries are often more difficult to identify and delayed diagnosis is frequent. Amputation rates for blunt vascular injuries of the extremities are much higher than that of penetrating injuries: lower extremity (25%) vs. upper extremity (17%). Vascular injury is a marker for overall increased severity of injury. The mortality rate in traumatized children with major vascular injuries is about 20% compared to a rate of 2-3% in all other injured children without vascular injury.

### ***Selected Readings***

1. King DR, Wise W. Vascular injuries. In: Buntain WL ed. *Management of Pediatric Trauma*, 1st Edition. Philadelphia: W.B. Saunders 1994; 265-276.
2. Evans WE, King DR, Hayes JP. Arterial trauma in children: Diagnosis and management. *Ann Vasc Surg* 1988; 2:268-270.
3. Richardson JD, Fallat M, Nagaraj HS. Arterial injuries in children. *Arch Surg* 1981; 116:685-690.

# Burns

*P. Stephen Almond and Heron E. Rodriguez*

## Incidence

Two million people are injured and 12,000 die each year in the United States due to burn injuries. About 500,000 are evaluated in emergency rooms, 75,000 are hospitalized and 25,000 are admitted to burn centers. One third are children under 6 years with most being less than 2. Males and those in lower socioeconomic groups are at higher risk.

## Etiology

Burn injuries are caused by thermal energy, electricity, or chemicals. Thermal injuries are the result of scald (85%) or flame (13%) burns. Electrical and chemical burns are less common (about 2%). Child abuse is documented in about 8% of burn injuries and is suspected but not proven in another 8%.

## Pathophysiology

The body's response to a burn can be divided into an ebb phase and a flow phase. The ebb phase is initiated by the burn. The burn destroys the skin, disrupting its thermoregulatory and barrier function. Evaporative and heat losses are increased and bacteria have direct access to the blood stream. It is estimated that 200 ml per m<sup>2</sup> of burned body surface area are lost every hour. In addition, inflammatory mediators including interleukin (IL)-1, IL-6, tumor necrosis factor (TNF), prostanoids, and oxygen free radicals are released resulting in increased capillary permeability, edema, and further loss of intravascular volume. The flow phase is characterized by the body's homeostatic response to the burn. The hypothalamic temperature regulatory center is reset, leading to an increase in metabolic rate, hyperthermia, and a hyperdynamic state. Activation of the limbic system by pain, fear and thalamic relay of nociceptive stimuli results in an increase in circulating catecholamines. Cortisol and ACTH levels are increased leading to increased gluconeogenesis, proteolysis and lipolysis. Glucagon secretion is increased and facilitates gluconeogenesis, glycogenolysis, lipolysis and ketogenesis. Peripheral resistance to insulin can also occur. Antidiuretic hormone (ADH) secretion is increased and the renin-angiotensin-aldosterone system is reset at an elevated level that is burn-size-dependent. The result is fluid retention, edema, and dilutional hyponatremia. Increased glomerular filtration and diuresis start 3-4 days after the injury.

## Management

Burn patients should be evaluated and treated according to ATLS protocols, with several special considerations. First, the burn process is halted by removing all clothing and any objects that can retain heat, chemicals, or act as a tourniquet. Chemical burns should be copiously irrigated with water. Neutralizing agents can be dangerous and, in general, should not be used. Second, hypothermia is prevented and pain diminished by providing a warm, draft-free environment and covering the child with a clean dry sheet. Finally, the possibility of an inhalational injury or carbon monoxide poisoning is considered in any child with prolonged smoke exposure, loss of consciousness, carbonaceous sputum, singed facial hair, or signs of thermal injury to the oropharynx. In these children, carbon monoxide levels drawn and early intubation is strongly considered.

## Airway, Breathing, Circulation

Burn victims are evaluated in warm, draft-free environments by physicians observing universal precautions. All jewelry and clothing are removed, and humidified 100% oxygen is administered. Patients are evaluated for signs (facial burns, carbonaceous sputum, singed nasal hair and tachypnea) or symptoms (burned within a confined space, altered level of consciousness, and hoarseness) suggestive of an inhalation injury or carbon monoxide poisoning. Fiberoptic bronchoscopy is diagnostic for an inhalational injury and can be used as an aid to intubation. Airway patency, however, does not guarantee adequate oxygenation or ventilation. Carbon monoxide and smoke inhalation interfere with oxygenation and are treated by manipulations of  $\text{FiO}_2$  and PEEP (positive end expiratory pressure). Circumferential, third degree chest burns restrict ventilation and are treated with escharotomies. Two large bore intravenous lines are started in the upper extremities, preferably (but not necessarily) through nonburned areas. Lower extremity lines have a higher rate of infection.

## Secondary Survey

A thorough head-to-toe evaluation is performed. The eyes are inspected for corneal injury. All skin is inspected and a neurovascular exam of the extremities is performed to rule out vascular insufficiency or compartment syndrome due to a circumferential, third degree burn. The child is log-rolled to inspect the back.

## Fluid Resuscitation

The Parkland (Ringers lactate at 4 ml/kg/%BSA) and Shriners (Ringers lactate at 5000 ml/m<sup>2</sup>/BSA burned plus 2000 ml/m<sup>2</sup>/BSA total/day) formulas provide guidelines for fluid resuscitation. One half the calculated fluid is given during the first 8 postburn hours and the second half over the following 16 hours. These formulas serve only as guides and are adjusted based on hemodynamic status and urine output (minimum 1 cc/kg/hr). In electrical injuries with extensive muscular injury, myoglobinuria requires alkalinization of the urine (by adding sodium bicarbonate to the IV fluids), osmotic diuretics (mannitol), and a higher urine output to prevent the myoglobin from crystallizing in the renal tubules. Only rarely is invasive hemodynamic monitoring required.

## Burn Wound Care

The wounds are gently cleansed and ruptured blisters debrided. After the initial debridement, the burn diagram is completed. The depth (Fig. 34.1) and size of the burn are determined using either the rule of nines or the Lund-Browder chart (Fig. 34.2). Transfer to a burn center is determined by American Burn Association criteria (Table 34.1).

Topical agents are used to control microbial wound colonization and reduce burn wound sepsis. Silver sulfadiazine is easily applied, causes no pain, and is the mostly widely used agent. Its disadvantages are the rapid appearance of plasmid-related resistance to sulfonamides and other antibiotics, limited eschar penetration and occasional transient neutropenia. Silver nitrate is an effective antimicrobial with no gram-negative resistance but, induces electrolyte imbalances and does not penetrate eschar. Mafenide acetate penetrates the burn eschar rapidly. It is a strong inhibitor of carbonic anhydrase and frequently causes metabolic acidosis and its application can cause pain.

If circumferential burn eschars act as a constricting tourniquet, escharotomies should be performed. Full thickness burns covering 25% BSA or less should be excised and grafted without delay. For deep burns too extensive to be excised and grafted in one procedure, staged excisions can be performed. Another alternative is early complete excision with the use of a temporary skin substitute to cover the wounds. Deep partial thickness burns can be treated with excision and grafting or with expectant therapy with similar long-term results.

The diagnosis of burn wound infection is clinical. Focal brown or black discoloration and conversion of a partial-thickness injury to full-thickness necrosis are the most reliable signs of burn wound infection. The diagnosis is confirmed by wound biopsy. The wound is cleansed of all antimicrobial preparations. The biopsy includes eschar and underlying viable tissue. A portion is put in formalin and sent to pathology and the remainder is sent for culture. More than 100,000 bacteria per gram of tissue and bacteria within viable tissue are suggestive of burn wound infection. A concurrent positive blood culture for the same organism suggest burn wound sepsis. Identification and treatment of burn wound infections minimizes the depth of the burn wound and graft loss.

## Nutrition

The hypermetabolism of the postburn period requires aggressive nutritional support. To meet the increased energy expenditures, supplemental caloric intake is needed. Metabolic energy expenditure (MEE) by indirect calorimetry is the best method for determining caloric requirements. MEE multiplied by a factor of 1.3 gives the number of calories required to maintain pediatric burn patients. Alternatively, several formulas can estimate with fair accuracy the caloric intake needed (see Chapter 7). In general, 20% of total calories should be provided as protein, 20% as fat and the rest as carbohydrates. To achieve positive nitrogen balance, the recommended protein intake for children less than 1 year of age, is 3-4 gm protein/kg and 1.5-2.5 gm protein/kg for older children. Randomized trials show aggressive protein feeding decreases infection rates and improves neutrophil function. Also, burn patients receiving 9% of protein as arginine had lower infection rates and decreased hospital stay. Diets containing 15-20% of nonprotein calories as fat appear to be



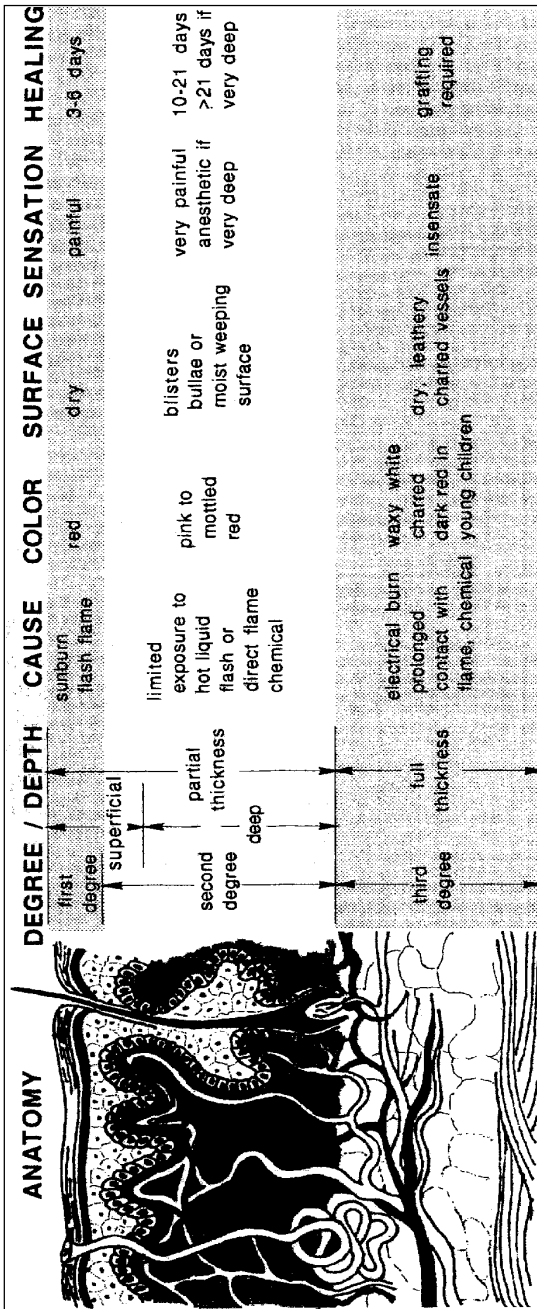


Fig. 34.1. Burn depth classification and characteristics. The initial classification of burn depth is based upon clinical criteria and the surface characteristics of the wound. The initial estimation of burn depth is frequently revised because whether a burn is ultimately partial or full thickness often requires several hours to days. Adapted with permission from Uitvlugt ND, Ledbetter DJ: Treatment of pediatric burns. In: Arensman RM, ed. Pediatric Trauma. Initial care of the injured child. New York: Raven Press 1995; 179.

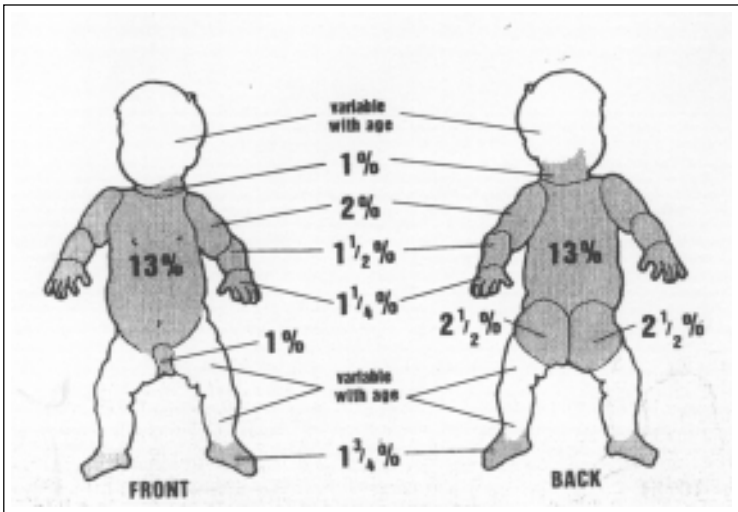


Fig. 34.2. Modified Lund-Browder chart for estimating and recording the total extent of partial and full thickness burns. Adapted with permission from Uitvlugt ND, Ledbetter DJ. Treatment of pediatric burns. In: Arensman RM ed. Pediatric Trauma. Initial care of the injured child. New York: Raven Press 1995; 179.)

**Table 34.1. American Burn Association criteria for referral to a burn center**

Partial-thickness and full-thickness burns greater than 10% BSA in patients under 10 years old

Partial-thickness and full-thickness burns greater than 20% BSA in older children

Partial-thickness and full-thickness burns involving face, eyes, ears, hands, feet, genitalia, perineum, or overlying major joints

Full-thickness burns greater than 5% BSA at any age

Significant electrical burns including lightning injury

Significant chemical burns

Inhalation injury

Burn injury in patients with preexisting illnesses or conditions that could complicate recovery or increase mortality and morbidity

Any burn patient in whom concomitant trauma poses an increased risk of mortality and morbidity should be treated at a trauma center until stable before transfer to a burn center

Children with any burn seen in a hospital without qualified personnel or appropriate equipment for their care

Suspected child abuse or neglect, or patients requiring special social, emotional, or rehabilitative support

optimal, with at least 4% of the total calories in the form of linoleic acid to prevent essential fatty acid deficiency. Larger amounts of fat can have an immunosuppressive effect by stimulating the release of arachidonic acid.

The oral or enteral route or maintaining adequate nutrition is preferred, but if the oral route is not possible, or if the total BSA burned is > 20%, an alternative route should be considered. Enteral nutrition increases gut blood flow, preserves mucosal integrity, maintains bowel function, and prevents bacterial translocation. It has a lower incidence of metabolic imbalances, avoids the potential complications of catheter insertion and catheter-related infections and is significantly less expensive than TPN (total parenteral nutrition). Immediate intragastric feedings after burn injury (within 6-24 hr) have been shown to be safe and effective. Burn patients receiving nasoduodenal tube feedings throughout the operative and perioperative period, have a lower infection rate than those whose feedings are held. Complications related to the enteral nutrition are rare. Increased mortality has been associated with the use of TPN in patients with severe burn injuries.

### **Pain Control**

Pain control in the pediatric population is often under emphasized. Adequate pain relief, especially in burn patients, is essential. For severe burn injuries, this may require the assistance of an anesthesiologist or pain service.

### ***Suggested Readings***

1. Duarte AM. Environmental skin injuries in children. *Curr Opin Pediatr* 1995; 7:423-30.
2. Germann G, Ceded C, Hartmann B. Postburn reconstruction during growth and development. *Pediatr Surg Int* 1997; 12:321-6.
3. Wolf SE, Debroy M, Herndon DN. The cornerstones and directions of pediatric burn care. *Pediatr Surg Int* 1997; 12:312-20.
4. Pruitt BA Jr., McManus AT, Kim SH et al. Burn wound infections: current status. *World J Surg* 1998; 22:135-45.
5. Utvlugt ND, Ledbetter DJ. Treatment of pediatric burns. In: Arensman RM ed. *Pediatric Trauma. Initial care of the Injured Child*. New York: Raven Press 1995; 173-199.
6. Lund CC, Browder NC. The estimation of area of burns. *Surg Gynecol Obstet* 1944; 79:52-8.
7. Bowser BH, Caldwell FT. The effects of resuscitation with hypertonic vs. hypotonic vs. colloid on wound and urine fluid and electrolyte losses in severely burned children. *J Trauma* 1983; 23:916-923.

## Bites and Stings

*Heather Haukness and David Bentrem*

### Animal Bites

In 1992, there were an estimated 52.4 million dogs and 54.6 million cats kept as pets. These large numbers of household pets account for most of the approximately 5 million Americans bitten annually. Animal bites overall account for up to 1% of summer emergency department visits. Animal bite injuries are most often due to dog bites (80%), but cat bites (6%) and human bites (1-3%) are also commonly encountered. Bite wounds that require attention are often to the extremities, especially the dominant hand. Significant cosmetic and functional impairment accompany severe bites. Facial bites are more frequent in children under 10 years old and lead to 5-10 deaths per year secondary to exsanguinating hemorrhage.

Animal bite wounds are frequently contaminated with multiple strains of aerobic and anaerobic bacteria. Between 2-30% of wounds seen in the emergency department become infected. Puncture wounds become infected more frequently than avulsion-type injuries. Osteomyelitis is an infrequent, but severe complication of bite wounds and is always considered when there is joint pain near the site of injury. Patients with a history of asplenia, liver disease or other forms of immunocompromise are at particularly high risk for infection.

Cat bites carry a much higher incidence of infection than dog bites, 35% vs. 4%. Human bite injuries have an even higher infection and complication rate than either cat or dog bite wounds. In general, anaerobic bacteria are recovered from over 50% of all infected bite wounds. *Pasteurella multocida*, *Staphylococcus aureus*, and streptococci are common pathogens in infected dog and cat bites. *Streptococci sp.*, *Staphylococcus aureus*, *Bacteroides sp.*, and *Eikenella sp.* are the most likely organisms recovered from infected human bite wounds.

The medical history that is obtained regarding bite injuries includes:

1. the type of animal,
2. situation in which the bite occurred, and
3. the time course of the injury.

Child abuse must be considered in all cases of human bite injury. In addition, concerns regarding potential exposure to viral diseases such as rabies (animal bites), HIV, hepatitis B, and hepatitis C should be explored. If the bite injury is associated with extensive tissue damage or is older than 8 hours, gram stain and aerobic/anaerobic cultures should be obtained prior to starting antibiotic therapy. All wounds are copiously irrigated and devitalized tissue is surgically debrided. Immobilization and

elevation of affected limbs helps reduce swelling and hasten resolution of associated cellulitis. Empiric antibiotic therapy should be given in all cases of:

1. puncture bite wounds (i.e., the majority of cat bites seen in the emergency department),
2. head, hand, foot, or genital bite injuries;
3. bites with associated crush injury, and
4. bites in immunocompromised patients.

The drugs of choice are either oral amoxicillin/clavulanic acid or intravenous ampicillin/sulbactam. In the penicillin-allergic patient, trimethoprim/sulfamethoxazole in combination with clindamycin is an alternative regimen. Tetracycline, although effective against *P. multocida*, is not used in children. Wounds in proximity to bone should have baseline radiographs taken. A tetanus booster is administered if the original 3-dose series is complete and a booster injection has not been given in the previous five years. The primary series tetanus vaccine and tetanus immunoglobulin is administered if the child has not completed the primary 3-dose series.

Wound management options include primary repair or delayed primary closure. Many physicians advise against primary closure, except with facial wounds. Puncture wounds are best allowed to heal by secondary intention. Therapeutic failure is usually from poor compliance with wound care, inappropriate antibiotic choice, or failure to recognize joint penetration. For outpatient therapy, follow-up appointments are mandatory and wounds are seen and re-evaluated within 48 hours. Ultimately, prevention is the best treatment of bite injuries. Children's interactions with pets should be closely supervised to prevent bite wounds. Stray animals should be reported to local authorities.

## Snake Bites

Venomous snakes, usually pit vipers (rattlesnakes, copperheads, or cotton mouths) bite approximately 8,000 people in the United States yearly. Fifty percent of these injuries occur in individuals less than 20 years of age. Snake bites occur more frequently in males, usually on the distal extremity. The highest incidence of snake bite is in the rural Southeast. Envenomization can cause extensive tissue destruction that predisposes to infection. Symptoms are dependent on the dose of venom, the location of the envenomation, size of the child, and whether the venom was delivered subcutaneously or intravenously. Severe pain and edema of the affected area is often associated with systemic symptoms such as nausea, vomiting, and diarrhea; or neurologic symptoms such as fasciculations and paresthesias. Diagnostic laboratory tests include creatinine phosphokinase, prothrombin time, fibrinogen, fibrin split products, and platelet count. Local pressure, immobilization, and a proximal constricting band is applied to impede lymphatic and superficial venous flow without compromising arterial blood flow. The child is monitored closely and large bore intravenous access is established. Antibiotics, analgesics, and a tetanus booster are indicated. If the use of antivenom is anticipated, the child is tested for hypersensitivity to horse serum prior to administration.

## Spider Bites

Arachnid bites, from the black widow or brown recluse spider in particular, are treated with the accepted mainstays of wound care including tetanus prophylaxis and patient monitoring. The decision to use antivenom is based on the severity or rapidity by which symptoms progress. The bite itself is rarely painful. Paresthesias, diaphoresis, and facial edema often occur along with generalized muscle cramps. Muscle spasm can be treated with intravenous calcium or diazepam.

## Stings

Hymenoptera (bees, wasps, & ants) venom is not very potent, however, children are at special risk for severe reaction because of their small size, and therefore, relatively higher systemic concentration. Bees are responsible for one half of stings, and the yellow jacket is most likely to produce anaphylaxis. Reactions range from a direct local tissue response, to serum sickness, to generalized anaphylaxis. The most frequent systemic symptoms are urticaria, syncope, and respiratory obstruction. It is estimated that 8 of every 1000 humans are allergic to insect stings.

Antihistamines, systemic corticosteroids, intravenous epinephrine, and airway protection (i.e., intubation) are often necessary in severe reactions. Otherwise, cold compresses and analgesics provide reasonable symptomatic relief. The stinger is removed by gentle scraping. Sensitized patients should always carry a kit containing tweezers and self-injectable epinephrine. Desensitization has been useful in children with history of severe reaction to stings.

## *Selected Readings*

1. American Academy of Pediatrics. Bite wounds. In: Peter G ed. 1997 Red Book: Report of the Committee on Infectious Disease. 24<sup>th</sup> ed. Elk Grove Village, IL: 1997.
2. Golladay ES. Animal, snake, and spider bites. In: Buntain WL ed. Management of Pediatric Trauma. Philadelphia: W.B. Saunders 1995; 478-493.

# Neonatal Trauma and Birth Injuries

*Daniel A. Bambini*

## **Incidence**

Newborns are most likely to be injured during birth if labor is difficult, presentation is breech, or a forceps delivery technique is used. Traumatic injury accounts for 1-2% of neonatal deaths. Birth trauma is the sixth leading cause of neonatal mortality and causes about 25 deaths per every 100,000 live births in the United States. For every neonatal death that occurs as a result of trauma, another 20 neonates will suffer a significant birth-related injury. This chapter describes several of the birth-related injuries that may be encountered in neonates.

## **Head Injuries**

### *Cephalohematoma*

Cephalohematoma occurs in about 1% of all live-born infants. The risk for developing cephalohematoma is greatest in large, male infants born to primigravid mothers. Forceps delivery is perhaps the greatest risk. Midforceps delivery results in cephalohematoma in about 30% of cases while low forceps and nonforceps delivery have a much lower risk (3.5% and 1.7% respectively). Cephalohematoma is believed to result from shearing forces that disrupt vessels in the plane between the calvarium and periosteum. The edges of the hematoma are usually sharply demarcated and do not cross beyond suture lines. An underlying skull fracture (usually linear) is present in 5-25% of cases, therefore x-rays are indicated. Subgaleal hemorrhage mimics cephalohematoma but often is larger extending beyond suture line boundaries into surrounding soft tissues of the head and neck.

Most cephalohematomas resorb spontaneously within a few weeks to months. Rarely an infant develops anemia (requiring transfusion) or hyperbilirubinemia as a result of cephalohematoma. If the hematoma is extremely large or if ulceration of the overlying scalp appears likely, needle aspiration and decompression of the hematoma is performed using sterile technique. If this is unsuccessful, open drainage is indicated to prevent the disfiguring calcification and skull deformity that may occur.

### *Skull Fractures*

Calvarial fractures in newborns are almost always associated with forceps deliveries. The most common site of fracture is the parietal bone. Most fractures are asymptomatic although fractures may lead to seizures or intracranial hemorrhage.

Many neonates with skull fractures have an overlying cephalohematoma or the scalp is ecchymotic. A depression may be palpable on exam.

Neonatal skull fractures are typically classified as linear or depressed. Linear fractures generally heal within 2 months of injury. Skull x-rays should be obtained at 3-4 months of age to exclude the presence of a leptomeningeal cyst. Leptomeningeal cysts occur after injury to the dura and frequently lead to seizure activity. Neurosurgical intervention is required to treat these lesions.

Depressed skull fractures in neonates are often called “ping-pong” fractures because there is “buckling” of the bone inward without an actual break in calvarial continuity. Computed tomography is indicated to identify penetrating bone fragments or an underlying intracranial hemorrhage. Small fractures are safely observed. Many depressed fractures are elevated using thumb compression. Vacuum extraction may also be successful. The indications for surgical intervention are:

1. penetrating bony fragments,
2. neurologic deficits,
3. signs of increased intracranial pressure,
4. cerebrospinal fluid collection beneath the galea, and
5. failed attempt at closed manipulation.

### *Intracranial Hemorrhage (ICH)*

Infants born after prolonged or difficult labor are at risk for intracranial hemorrhage. Other known risk factors include cephalopelvic disproportion, breech delivery, and mid or high forceps delivery. Frequently the onset of symptoms and signs of ICH (irritability, high-pitched cry, seizures, increased head circumference, bulging fontanelle, etc.) is insidious and may not appear until 24-48 hours after birth. The three common types of ICH are subarachnoid hemorrhage, subdural hemorrhage, and epidural hemorrhage. Head CT and cranial ultrasound are the diagnostic tests used to differentiate the three.

Subarachnoid bleeding in neonates is not uncommon. Many neonates will have erythrocytes in their CSF after birth but the majority will be asymptomatic. In premature neonates, subarachnoid hemorrhage is usually caused by asphyxia. In term babies, subarachnoid bleeding is more likely to be secondary to trauma. The typical presenting feature of significant subarachnoid hemorrhage is an acute onset of seizures usually around 24-36 hours of age. Treatment consists of seizure control, correction of coagulopathies, and transfusion as indicated.

Neonatal subdural hemorrhage is very rare. Vaginal breech deliveries are at the highest risk for producing subdural hemorrhage in newborns. Prolonged deliveries with face/brow presentations may cause excessive cranial molding and subsequent bleeding. The severity of symptoms depends on the amount and location of bleeding. Bleeding is usually from rupture of the superficial cerebral veins. Cerebral contusion is present in up to one half of these infants. Epidural hemorrhage is the rarest type of ICH encountered in neonates. Only about 60-70% of these cases will have an associated fracture of the temporal bone. When the bleeding source is arterial, it causes the infant to rapidly deteriorate with increased intracranial pressure within the first few hours of life. Surgical intervention must be initiated as soon as possible.



## Spine and Cord Injuries

Spine injuries in neonates almost always occur at the cervical spine. Nearly 75% of birth related c-spine injuries are associated with breech or footling presentation at time of delivery. Breech injuries usually occur at the C6-7 or C7-T1 levels and result from traction on the body while the head remains engaged within the maternal pelvis. High cervical injuries (C1-2) can occur with difficult vertex deliveries due to extreme rotational forces. In neonates, complete cord transection can occur even when the dura and bony structure or the cervical spine remains intact with no radiologic evidence of fracture. If a fracture or dislocation is observed on radiologic studies, severe cord injury (i.e., transection) can be anticipated. Depending upon the severity or completeness of the lesion, these newborns may be awake and alert at birth but often have apnea, spinal shock, severe flaccidity, and respiratory failure. Abdominal wall paralysis and areflexia are frequent early findings. Later, the originally flaccid extremities become spastic and hyper-reflexic.

The prognosis is difficult to determine initially and gradual return of neurologic function, sometimes complete, can occur over weeks to months. Therapy is nonspecific and conservative. All efforts should be made to maintain neck immobilization to prevent further injury.

## Facial Fractures

The most common facial fracture in neonates is subluxation of the nasal septum. This lesion only occurs in 2-3% infants but can cause significant respiratory distress in these obligate nasal breathers. The respiratory distress is frequently aggravated or worsened by oral feedings. The treatment is early reduction and fixation. Mandible fractures are also occasionally observed in infants and also require early identification, reduction and immobilization. If undiagnosed, mandible fractures ultimately result in malocclusion, cosmetic deformity, feeding problems, and speech difficulties.

## Eye Injuries

Minor eye injuries (abrasions, conjunctival hemorrhage, etc) are common and occur in 20-25% of normal deliveries. Serious eye injuries occur in less than 0.25% of live births and are almost always a result of forceps delivery. Subconjunctival and retinal hemorrhages are the most common eye injuries. Most resorb within the first 2-3 days of life and are benign. Hyphema, blood in the anterior chamber of the eye, is more serious and requires careful observation and follow-up. If rebleeding occurs or the blood persists beyond 7 days of life, medical treatment with acetazolamide and/or surgical evacuation of the anterior chamber may be necessary to prevent later glaucoma. Corneal cloudiness or haziness is normal in the newborn, but if it persists beyond one week a rupture of the posterior corneal membrane (Descemet's membrane) should be suspected. If left untreated, this can result in permanent leukoma, astigmatism, strabismus, and other problems with vision.

## Nerve Injuries

The most often observed neonatal nerve injuries include injuries to the facial nerve, the recurrent laryngeal nerve, brachial plexus, and the phrenic nerve. Facial

nerve palsy is the most common birth-related nerve injury and is usually associated with forceps delivery. Nearly 75% of facial nerve injuries occur on the left side. Facial nerve injury usually occurs secondary to pressure applied to the nerve at the site where it exits the stylomastoid foramen or where it crosses over the ramus of the mandible. Signs of injury may be subtle and include flattening of the ipsilateral nasolabial fold, a persistently opened eye, and an inability of the neonate to move the corner of the mouth. Spontaneous recovery usually occurs within 1-3 weeks but may take longer. The cornea should be protected with an eye patch and eye drops (1% methyl cellulose) instilled every 3-4 hours.

Vocal cord paralysis is the principal clinical manifestation of recurrent laryngeal nerve injury which is uncommon in neonates. The left nerve is more commonly injured than the right in part due to its longer length and course through the neck. Bilateral vocal cord paralysis in neonates is usually secondary to CNS damage (i.e., hypoxia, hemorrhage). The signs of unilateral vocal cord paralysis include inspiratory stridor and hoarseness with crying. There are typically no symptoms or signs at rest. The diagnosis is made by direct laryngoscopy. Small frequent feedings are recommended to reduce the risk of aspiration. Most of these injuries are reversible and resolve spontaneously within 4-6 weeks.

Brachial plexus injuries and phrenic nerve injuries in neonates are usually due to stretching (traction) injury of nerve roots. Erb's palsy is the most common newborn brachial plexus injury, affects C5-6 nerve roots, and accounts for 60-90% of cases. The signs of Erb's palsy are:

1. arm internally rotated at the shoulder,
2. arm extension at the elbow,
3. forearm pronated,
4. flexion at the wrist, and
5. absent biceps and brachioradialis reflexes.

Klumpke's paralysis is a rare neonatal brachial plexus injury affecting the C8-T1 nerve roots that is frequently associated with a Horner syndrome (ptosis, miosis, anhidrosis, enophthalmos). The prognosis for recovery of neurologic function after brachial plexus injury is quite variable although full recovery is usual in 80-90% of cases. Complete recovery, if forthcoming, usually occurs within 3-6 months. Neonatal phrenic nerve paralysis results from traction injury to the C3-C5 nerve roots and almost always occurs in association with a brachial plexus injury. Eighty percent are right side lesions; less than 1% are bilateral. Phrenic nerve injury may cause diaphragmatic paralysis, respiratory distress, and an elevated hemidiaphragm and/or eventration (Chapter 72). Most of these phrenic nerve injuries resolve spontaneously within 6 weeks. Diaphragmatic plication may become necessary if improvement does not occur by 2 months or life threatening pulmonary complications (pneumonias, respiratory failure, aspiration) ensue.

## **Pneumothorax**

Pneumothorax in neonates usually results from the barotrauma of aggressive positive pressure ventilation or overinflation of the lungs. If respiratory distress is significant, tube thoracostomy is performed. Small pneumothoraces in uncompromised, nonmechanically ventilated infants can be observed and often

resolve spontaneously in 24-48 hours. In mechanically ventilated neonates, tube thoracostomy is indicated for almost all pneumothoraces.

### **Abdominal Trauma**

Abdominal trauma in neonates is very rare. Liver injuries are the most common yet occur in far less than 1% of newborns. Abdominal trauma usually occurs in babies with history of a difficult delivery. The most commonly injured organs are the liver, adrenal gland, spleen and kidney. The risk of injury is increased in the presence of pre-existing organomegaly. The clinical presentation is that expected with intra-abdominal bleeding and includes signs of pallor, irritability, abdominal distention, anemia, and hemodynamic instability. Neonatal liver injuries are extremely difficult to control surgically, and many of these injuries are lethal.

### **Skeletal Fractures**

The most commonly encountered birth-related fractures are of the clavicle, humerus, and femur. Most of these injuries are either midshaft fractures or epiphyseal separations. Less than 1% of all newborn infants sustain a fracture during delivery. Most fractures are easily confirmed by x-ray examination. Clavicle fractures account for 90-93% of neonatal fractures. All infants with clavicle fracture should be evaluated for possible coexisting injuries of the brachial plexus, the cervical spine, and the humerus. Clavicle fractures in neonates usually heal rapidly with complete union at 7-10 days. Specific therapy is usually not necessary.

Seventy-five percent of extremity fractures in newborn infants occur in association with breech delivery. Infants with long-bone fractures usually have a tender, swollen limb that often hangs limply with no voluntary movement. Crepitus is variably present. Epiphyseal injuries of the humerus and femur are usually Salter-Harris type I lesions.

### **Iatrogenic Perforation of the Pharynx or Esophagus**

Pharyngoesophageal perforations occur after difficult endotracheal or esophageal intubations. Traumatic perforations also occur with vigorous passage of orotracheal suction tubes or feeding tubes. The clinical findings associated with pharyngeal perforation with a nasogastric tube closely mimic those of esophageal atresia. In patients with esophageal atresia, the nasogastric tube passes to about 11 cm before reaching the distal end of the blind esophageal pouch. If the tube passes to a shorter or longer distance with some difficulty, the diagnosis of esophageal atresia is considered. Blood at the end of the passed nasogastric tube is common with perforation but not expected with esophageal atresia. A chest radiograph may reveal a pneumothorax, pneumomediastinum, feeding tube within the chest, or a unilateral infiltrate with an abnormal extrapleural air collection. Nonoperative therapy with close observation, broad-spectrum antibiotics, TPN, and selected tube thoracostomy, is usually effective. Clinical deterioration with signs of infection or mediastinitis mandates prompt surgical exploration and drainage.

### **Selected Readings**

1. Perlow JH, Wigton T, Hart J et al. Birth trauma. A five-year review of incidence and associated perinatal factors. *J Reprod Med* 1996; 41:754-760.

2. Krasna IH, Rosenfeld D, Benjamin BG et al. Esophageal perforation in the neonate: an emerging problem in the newborn nursery. *J Pediatr Surg* 1987; 22:784-790.
3. Marchildon MB, Doolin EJ. Birth Injuries. In: Buntain WL ed. *Management of Pediatric Trauma*. Philadelphia: WB Saunders Company 1995; 494-513.
4. Raffensperger JG. Trauma in the neonate. In: Raffensperger JG ed. *Swenson's Pediatric Surgery*, 5<sup>th</sup> Edition. Norwalk: Appleton & Lange 1991; 339-341.
5. Medlock MD, Hanigan WC. Neurologic birth trauma: intracranial, spinal cord, and brachial plexus injury. *Clin Perinat* 1997; 24:845-57.

# Child Abuse

*Matthew L. Moront and Fawn C. Lewis*

## Definitions

The maltreatment of children can be subdivided into 2 major categories:

1. abuse and
2. neglect.

The abuse of a child may be either physical or sexual. Physical abuse is defined as “harm or threatened harm to a child through nonaccidental injury as a result of the acts or the omissions of acts of those persons responsible for the child’s care.” Sexual abuse is defined as “the commission of any sexual offense with or to a child as a result of the acts or omissions by the child’s caretaker.”

Neglect is a more subtle form of maltreatment and is defined as “the harm that occurs through the failure of the caretaker to provide adequate food, shelter, medical treatment, or other provisions necessary for the child’s health and welfare.” Neglect is further subdivided into emotional, physical, or educational neglect.

## Incidence

In 1992 there were almost 3 million cases of possible child abuse or neglect reported in the United States. Substantiation rates varied from 13-72% (average 40%) documenting that over 1 million children were confirmed victims of abuse or neglect during that one-year period, giving an incidence of approximately 2 per 1000 children. The actual prevalence is unknown. In 1992, over 1200 children died as a result of neglect or abuse.

Although both sexes suffer abuse, girls are slightly more affected due to the higher incidence of sexual abuse in female children. Contrary to many published reports children under 2 years of age are the least abused group of children. However, more serious injuries and fatalities occur among this younger age group. Although there are no significant racial or ethnic differences in the incidence of abuse or neglect, socioeconomic factors are important. When families are stratified into those with household incomes greater or lesser than 15,000 dollars annually, families in the lower income bracket demonstrated 4-8 times the amount of abuse or neglect inflicted by families in the higher income bracket.

## Clinical Presentation

When a child is seen with injuries, abuse is suspected if any of the following are present:

1. there is a delay in presentation or the history given is inconsistent with the injuries sustained,

2. parents attempt to explain injuries with mechanisms that are unlikely given the child's developmental status,
3. the primary caregiver is not present,
4. there is a history of unexplained injuries,
5. parents understate the seriousness of the child's injuries and are reluctant to allow hospital admission for further diagnostic testing,
6. parents have visited several area hospitals and arrive at the emergency department in the early morning hours, hoping to draw less attention to the child's injuries, or
7. parents questioned about the specifics of the injury, become hostile and defensive.

In addition, concern arises when the child's physical examination reveals a variety of injuries often in various stages of healing. Table 37.1 lists some of the common physical and clinical findings associated with child abuse.

## Diagnosis

The diagnosis of child abuse or neglect can be difficult to make with certainty. The clinician's role is not one of judge or jury, but rather child advocate. Thus, every effort must be made to remain impartial and collect the facts as accurately and completely as possible. Careful documentation of the exact words parents and caretakers use to describe the events surrounding the suspected abuse is essential. The decision to evaluate a child for abuse is based not only on the history and physical examination, but also on the radiologic findings and the constellation of injuries found. The degree to which these injuries correspond to recognized patterns of injury in abused children influences the medical conclusions drawn.

The most common radiologic findings are those of occult fractures and soft tissue injuries. Fractures occur in nearly one third of physically abused children and over half of all fractures in children less than one year of age are the result of abuse. Occult fractures are identified in various states of healing. Periosteal or new bone growth appears 7-10 days following injury. Soft and hard callus formation occurs at 2 and 3 weeks, respectively. At 6-8 weeks following injury, the original fracture line is completely obscured by callus formation.

Spiral fractures are commonly seen in the tibia, femur, radius, and humerus of abused children and result from a strong twisting of the extremity. Abuse is suspected when the history does not suggest a large amount of rotational force. Rib fractures, especially in children less than 2 years of age, alerts the clinician to the possibility of intentional injury. Rib fractures resulting from intentional injury are usually posterior and occur secondary to the violent compression of the chest.

## Patterns of Injury

### *Head Injury*

Head injuries are the leading cause of fatal child abuse, and 80-90% of these deaths affect children under 2 years of age. Complex skull fractures, bilateral fractures, or fractures that cross suture lines are suggestive of intentional injury.

Shaken impact syndrome (SIS), first described by Caffey in 1974, is characterized by subdural or subarachnoid hemorrhages, retinal hemorrhages, and minimal

**Table 37.1. Clinical and physical signs of child abuse****Head:**

- Retinal hemorrhages in the absence of thoracic trauma
- Unexplained dental trauma or torn frenulum of the upper or lower lip.
- Bilateral black eyes with a history of a single fall or injury
- Traumatic hair loss or swollen ears
- Severe central nervous system injury with a history inconsistent with the extent of injury.

**Skin and Soft Tissue Injuries:**

- Bruises located in areas normally protected, such as the thighs, upper arms, back, and abdomen. Bruising normally occurs over bony prominences (elbows, knees, etc.)
- Bruising of various colors denoting injuries in various states of healing.
- Bruises that resemble the outline of specific objects such as belts, hands, whipping cords, etc.
- Burns that follow a stocking or glove pattern, located on the perineum, or that are well demarcated such as from being dipped into a too-hot tub, or from a hot iron, cigarette, curling iron, etc.
- Human bites of any type with an inconsistent history

**Abdominal Injuries:**

- Evidence of abdominal wall hematoma.
- Bilious vomiting or reports of emesis or diarrhea witnessed only by the parents.
- Injuries to the perineum or genitals. Physical exam consistent with a sexually transmitted disease.
- Chronic weight loss or child small for gestational age.

**Skeletal Injuries:**

- Rib fractures in a child under 2 years of age, particularly posterior rib fractures that often result from direct blows. Lateral rib fractures can occur secondary to anterior posterior crushing.
- Femur fractures in children less than 3 years of age, particularly if the child is preambulatory.
- Fractures located at the metaphyseal-epiphyseal junctions in the long bones.
- Spiral fractures of the femur
- Fractures in various states of healing
- Fractures of the scapula, sternum, spinous process, or lateral clavicle.
- Complex skull fracture after a fall of less than 3 feet in height.

or absent signs of external trauma. Originally thought to occur due to violent shaking of an infant without cranial impact, recent evidence suggests that the rotational forces caused by shaking alone are not severe enough to cause the severity of injury frequently observed in these children. A combination of violent shaking and sudden deceleration caused by cranial impact is necessary to generate the angular acceleration required to cause significant intracranial injury. The SIS is rarely observed in children over 3 years of age. Clinical findings include lethargy, irritability, vomiting, apnea, feeding intolerance, and seizures (40-70%). Retinal hemorrhages are present in 70-95% and are often bilateral or associated with retinal detachment. Retinal hemorrhage is very rarely seen in other clinical situations (i.e., recent vehicular trauma, birth trauma), is not associated with recent cardiopulmonary resuscitation, and is not attributable to birth trauma if the child is beyond 2 months of age.

### *Intra-Abdominal Injuries*

Abdominal injuries are the second most common cause of death in the abused child. Bruising of the anterior abdominal wall suggests potential visceral injury. The organs overlying the spine are particularly vulnerable, especially the duodenum and pancreas.

Duodenal hematomas occur as a result of compression against the vertebral column and present as either a partial or complete bowel obstruction with vomiting and mid-epigastric pain. Upper gastrointestinal contrast studies may reveal a "coiled spring" appearance. The pancreas is also easily compressed against the spine and injured. Blunt trauma to the pancreas causes pancreatitis, pancreatic transection, or pancreatic pseudocyst. Over 50% of pancreatic pseudocysts identified in children are posttraumatic.

Injuries to the solid organs (i.e., liver, spleen, kidney) are less occasionally seen and include rupture, contusion, and subcapsular hemorrhage. Tears to the bowel mesentery and gastrointestinal perforations are also rarely encountered.

### **Burns**

Burn injuries account for approximately 10% of intentional injury cases. Inflicted burns commonly show distinctive patterns of distribution. Burns to the perineum and buttocks often occur as a form of punishment for a child having difficulty toilet training. Burn wounds that have a "stocking" or "glove" distribution most often result from immersion in hot water and are nearly pathognomonic for intentional injury. Deep, repeated, and well-circumscribed burn wounds (i.e., branding injuries) are common and are frequently inflicted with cigarettes, curling irons, and cooking utensils.

### *Treatment*

Management of children with intentional injuries is the provision of both physical and emotional treatment. Medical specialists, social service agents, physical therapists, and psychological support personnel are helpful to manage these children. Child abuse is a family problem and requires a multidisciplinary team to be effective. It is important to answer any questions the child may have concerning what is happening to them and to provide reassurance. Intentionally injured children must be reassured that what has happened is not their fault.

Despite the requirement that all physicians report any suspected cases of child abuse or neglect, formal reporting occurs in only half of these cases. Failure to report is due to concerns over harming reputations, producing undue stress on the family, or discouraging offenders from voluntarily seeking treatment. Good faith reporting laws protect physicians from litigation in unproven cases.

### *Selected Readings*

1. Gonzalez-Ibrahim E. Diagnostic points in child abuse. *Resident and Staff Physician* 1996; 42(12):12-16.
2. Wissow LS. Child abuse and neglect. *NEJM* 1995; 332(21):1425-1431.
3. Duhaime AC, Christian CW, Rorke LB et al. Nonaccidental head injury in infants—the "shaken baby syndrome." *NEJM* 1998; 338(25):1822-1829.
4. Berkowitz CD. Pediatric Abuse—New Patterns of injury. *Emerg Med Clin N Am* 1995; 13(2):321-341.



## **Section V: Pediatric Tumors**

## Renal Tumors

*P. Stephen Almond*

### Incidence

The five most common pediatric renal tumors are Wilms' tumor, clear cell sarcoma, rhabdoid tumor, congenital mesoblastic nephroma, and nephroblastomatosis. Wilms' tumor is by far the most common with an incidence of 8 per million or about 350 cases per year. Children with Wilms' tumor, clear cell sarcoma, or rhabdoid tumor are entered in the National Wilms' Tumor Study Group (NWTs). Wilms' tumors make up 90-95% of NWTs followed by clear cell sarcomas (6%), and rhabdoid tumors (2%). Congenital mesoblastic nephroma is the most common renal tumor of infancy, but less than 100 cases of congenital mesoblastic nephroma have been reported. Nephroblastomatosis or nephrogenic rests are found in 1% of neonatal autopsies, 40% of Wilms' tumors, 8% of kidneys with obstructive uropathy, and 7% of multicystic dysplastic kidneys.

### Etiology

The majority of Wilms' tumors are sporadic. However, deletions in chromosomes 11p13 (10% of cases), 11p15, and 16q have been reported in Wilms' tumor patients and are associated with increased risk of developing the tumor. The *11p13* gene has been named Wilms' tumor gene 1 (WT1); the *11p15* gene is called Wilms' tumor gene 2 (WT2); and the *16q* gene has been named the Wilms' tumor gene 3 (WT3). The gene product of WT 1 is a DNA-binding protein found on fetal kidney and genitourinary tissues. The gene products of WT 2 and WT 3 are unknown. The etiology of clear cell sarcoma, rhabdoid tumors, and congenital mesoblastic nephroma are unclear.

### Clinical Presentation

The majority of children with Wilms' tumor present between the ages of 2 and 4 years with an asymptomatic abdominal mass. Other symptoms include hematuria (10%), hypertension (20%), anorexia, fever, and weight loss. Associated conditions can be divided into syndromic and nonsyndromic. There are four syndromic associations. Denys-Drash syndrome is male pseudohermaphroditism and degenerative renal disease leading to end-stage renal disease within the first year of life. The risk of Wilms' tumor is 90% and the associated chromosomal deletion is 11p13 or WT 1. Klippel-Treunay syndrome includes superficial vascular anomalies, deep vascular anomalies, and limb overgrowth. Beckwith-Wiedemann syndrome includes macromelia, macroglossia, omphalocele, ear fissures, facial hemangioma, and mental

retardation (5%). The risk of Wilms' tumor is 5% and the associated chromosomal deletion is 11p15 or WT 2. WAGR syndrome is the association of Wilms' tumor, aniridia, genitourinary anomalies, and mental retardation. The risk of Wilms' tumor is 30% and the genetic defect is a chromosomal deletion of WT 1.

There are three nonsyndromic lesions associated with Wilms' tumor:

1. aniridia,
2. hemihypertrophy, and
3. genitourinary anomalies.

The incidence of aniridia in Wilms' tumor patients is < 1%. It is due to a deletion of the short arm of chromosome 11. Children with aniridia should undergo physical examination, abdominal ultrasound and urinalysis every 3 months until the age of 5-8 years. The incidence of hemihypertrophy in Wilms' tumor patients is 3%. The most common genitourinary anomalies in Wilms' tumor patients are cryptorchidism (1%) and hypospadias (5.2%).

Children with clear cell sarcoma present between 1 and 2 years of age. Bone metastasis are present in 40% of these children. Children with rhabdoid tumor also present younger (average age 17 months) than those with Wilms' and have a high incidence of associated brain tumors (13%). Children with mesoblastic nephroma present within the first four months of life. Otherwise, the clinical presentation of these three lesions is identical to that of Wilms' tumor.

## Diagnosis

The diagnostic workup includes a chest x-ray and an abdominal ultrasound. The chest x-ray is done to evaluate for the presence of pulmonary metastasis. The abdominal ultrasound shows:

1. the tumors' organ of origin,
2. the consistency of the tumor,
3. tumor in the contralateral kidney, and
4. the extension of tumor into the renal vein and/or inferior vena cava (IVC).

Additional studies include urinalysis, abdominal plain film, and computed tomography (CT) (Fig. 38.1). The urine may contain red blood cells (20% of cases) or hyaluronic acid. The abdominal x-ray may show "eggshell" calcifications. This is in contrast to the "speckled" calcifications seen in neuroblastoma and the "popcorn" calcifications seen in teratomas. CT scan of the chest and abdomen are frequently used to determine:

1. the presence of pulmonary metastasis,
2. the tumors' organ of origin,
3. the condition of the contralateral kidney, and
4. the presence of tumor in the renal vein/IVC.

## Pathology

The histology of Wilms' tumor (Fig. 38.2) is either favorable or unfavorable. Favorable histology is more common (89%) and is characterized by the presence of three components:

1. stroma,
2. blastema, and
3. epithelial elements.

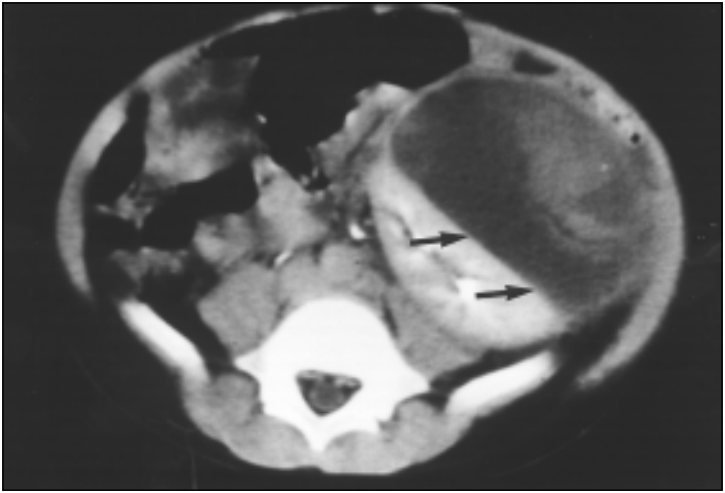


Fig. 38.1. Computed tomography revealing left renal tumor replacing most of the medial portion of the organ (Wilms' tumor).

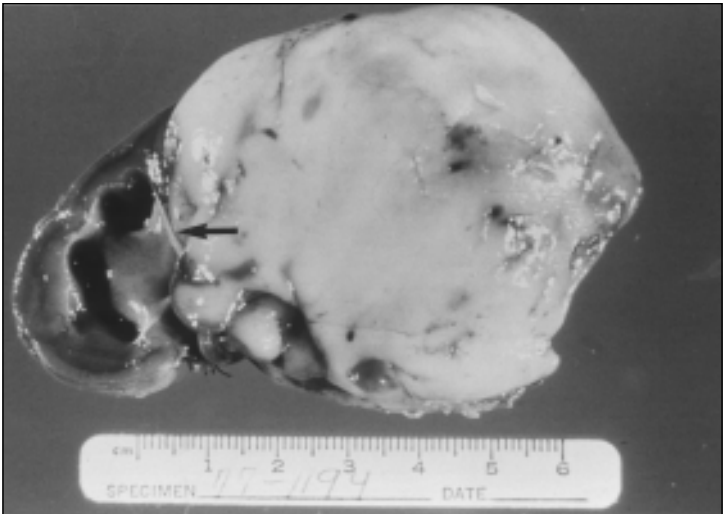


Fig. 38.2. Pathological specimen shows a solid, homogeneous tumor replacing most of the superior pole of a kidney (Wilms' tumor).

Unfavorable histology is less common (11%) and defined by the presence of anaplasia, clear cell sarcoma, or rhabdoid tumor.

Mesoblastic nephroma is a benign, white to yellow-tan lesion that gradually gives way to normal appearing kidney. Microscopically, spindle cells are seen instead of the normal kidney parenchyma. Although generally considered a "benign" or hamartomatous lesion, mesoblastic involvement of the renal vein and a pulmonary metastasis have been reported.

Nephroblastomatosis or nephrogenic rests are microscopic areas of blastema adjacent to normal kidney parenchyma. The natural history of these rests is poorly understood. At present it is thought that these lesions may regress or develop into Wilms tumor.

### Staging

NTWS has five stages. Stage I lesions are confined to the kidney and completely excised. Stage II lesions extend beyond the kidney but are completely excised. Local spillage confined to the flank and preoperative biopsy are acceptable. Stage III lesions are confined to the abdomen but cannot be completely resected. Peritoneal spillage of tumor automatically makes the tumor Stage III. Stage IV lesions have hematogenous metastases to lung, liver, bone, or brain. Stage V indicates bilateral disease.

### Treatment

These children undergo laparotomy and abdominal exploration unless Stage IV or V disease is confirmed. The presence of bloody ascites suggests tumor rupture and stage III disease. Before removing the tumor, the contralateral kidney is manually and visually inspected. Any and all suspicious lesions are biopsied. If the contralateral kidney is normal, an ipsilateral radical nephroureterectomy is performed being careful not to rupture the tumor. Paraaortic lymph nodes are sampled and titanium clips are placed along the margins of resection. If there is bilateral disease and wedge/partial resection of all tumors will result in removal of greater than 1/3 of the total renal mass, biopsy is done and the patient is closed. Afterward, the child is treated with chemotherapy and re-explored in 6 weeks.

All children with Wilms' tumor receive postoperative chemotherapy. Those with stage I and II lesions and favorable histology are treated with actinomycin-D and vincristine. Children with stage III and IV lesions and favorable histology are treated with actinomycin-D, vincristine, and adriamycin (doxorubicin) and postoperative radiation therapy. Children with stage I lesions and unfavorable histology are treated with actinomycin-D and vincristine. Children with stage II, III, and IV lesions and unfavorable histology are treated with three (actinomycin, vincristine, adriamycin) or four (actinomycin, vincristine, adriamycin, cyclophosphamide) drugs and postoperative radiation therapy.

Indications for postoperative radiation therapy include gross residual tumor, tumor spill, positive lymph nodes, peritoneal involvement, stage IV disease, and unfavorable histology. Indications for preoperative chemotherapy include stage V disease, IVC involvement above the hepatic veins, massive tumor, and cytoreductive therapy if other organs are at risk.

Children with congenital mesoblastic nephroma do not require adjuvant therapy.

## Outcome

The overall survival for children with favorable histology is 90%. Children with favorable histology, stage I lesions have a 97% long-term survival. This drops to 60% for children with favorable histology, stage IV lesions. Overall survival for children with unfavorable histology is 50%. Children with unfavorable histology, stage I lesions have an 89% long-term survival. This drops to 14-55% for children with unfavorable histology and any other stage disease.

Congenital mesoblastic nephroma is a benign lesion with an excellent prognosis.

## *Selected Readings*

1. Renal tumors. In: Rowe MI, O'Neill JA, Grosfeld JL et al, eds. Essentials of Pediatric Surgery. St. Louis: Mosby-Year Book, Inc. 1995.
2. Shochat SJ. Wilms' Tumor: Diagnosis and Treatment in the 1990s. *Sem Pediatr Surg* 1993; 2:59-68.

# Neuroblastoma

*Marybeth Madonna*

## Background and Etiology

Neuroblastoma is a tumor derived from neuroblasts. Neuroblasts are derived from neural crest cells and migrate during fetal development to form the autonomic nervous system. There are two paths of migration:

1. along developing nerves to form the sympathetic plexuses, where they form ganglion cells and
2. to the adrenal gland to form the medulla.

Tumors of the neuroblasts can be either malignant or benign. The tumors are named ganglioneuromas, ganglioneuroblastoma and neuroblastoma depending on the degree of malignant potential with ganglioneuromas being completely benign and neuroblastoma being malignant with the ganglioneuroblastoma as an intermediate tumor.

Neuroblastoma is the most common extracranial solid tumor in children accounting for 8-10% of all childhood cancers. This tumor occurs in approximately 1 in 7000-18,000 live births. There are about 550 new cases each year in the United States. There is no ethnic prevalence. There is a slight male predominance with a ratio of 1.2:1 (male to female). The median age at diagnosis is 22 months, and 97% of neuroblastomas are diagnosed in children less than ten years of age. The incidence is biphasic with a peak at less than one year of age and a second peak at 2-4 years. Prenatal or postnatal exposure to drugs, chemicals or radiation has not been unequivocally demonstrated to increase the incidence of neuroblastoma.

Although most cases of neuroblastoma are thought to be sporadic, there is a subset of patients that exhibit a predisposition to develop disease in an autosomal dominant pattern. About 22% of neuroblastomas are thought to be the result of a germinal mutation. The hereditary form of the disease has an earlier mean age at diagnosis (9 months versus 22 months) and has a higher incidence of bilaterality and multifocal tumors (20%). Neuroblastoma is thought to follow a two-mutation hypothesis of tumorigenesis.

## Pathology

Neuroblastomas arise from the primitive pluripotential sympathetic cells that are derived from neural crest cell and normally differentiate to form tissues of the sympathetic nervous system. All fetuses have neuroblastic nodules between 17-20 weeks gestational age. Most regress before birth or shortly thereafter. Neuroblastoma in situ is frequently found in infants three months or younger dying from

other causes. Therefore the cells that form neuroblastoma may be fetal remnants that fail to regress.

Neuroblastomas belong to a group of tumors classified as the “small round blue cell” tumors. Others in this category include Ewing’s sarcoma, non-Hodgkin’s lymphoma, primitive neuroectodermal tumors (PNETs) and undifferentiated soft tissue sarcomas such as rhabdomyosarcoma. Neuroblastomas can be differentiated from other tumors in this category by using immunohistochemistry. These tumors are positive for the marker neuron specific enolase. Neuroblastoma cells have neuritic processes called neuropil. Homer-Wright pseudorosettes are formed by neuroblasts surrounding areas of eosinophilic neuropil. Ganglioneuromas, the benign variety of this tumor, are composed of mature ganglion cells, neuropil and Schwann cells. Ganglioneuroblastomas are a heterogeneous group of tumors with varying degrees of mature ganglion cells. These cells may be focal or diffuse with the diffuse variety associated with less aggressive behavior. These tumors show dense neurosecretory granules as well as microfilaments on electron microscopy (EM).

There have been attempts to determine prognosis based on histologic criteria. The Shimada classification compares patient age and

1. the presence or absence of Schwann cell stroma,
2. degree of differentiation and
3. mitosis-karyorrhexis index (MKI) to differentiate tumors into favorable or unfavorable prognosis.

The Joshi classification considers the presence of calcifications and mitotic rate. A low mitotic rate ( $< 10$  per high power field) and the presence of calcifications predicts a favorable outcome (grade 1). Grade 3 tumors have neither feature and are associated with a poor prognosis.

Several cellular and molecular characteristics have prognostic significance in patients with neuroblastoma. Tumor cells produce varying amounts of DNA. The measurement of this is called the DNA index. For normal cells, the DNA content is diploid and the DNA index is 1. Some neuroblastomas have a high DNA content and are called hyperdiploid (DNA index  $> 1$ ). In younger children, tumors that are hyperdiploid are more likely to have a lower stage of tumor and be responsive to cyclophosphamide and doxorubicin. Hyperdiploid tumors in older children do not have the same favorable outcome. The most consistent specific genetic abnormality identified in children with neuroblastoma is a deletion of the short arm of chromosome 1(1p). This most likely represents a deletion of a tumor suppressor gene.

Neuroblastomas may also show n-myc amplification. This region of amplification is located on the distal short arm of chromosome 2 and contains the N-myc protooncogene. Amplification of n-myc occurs in 25% of patients with neuroblastoma and is associated with advanced stage of disease, rapid tumor progression, and poor prognosis. Molecular studies have demonstrated a correlation between the 1p deletion and n-myc amplification. An important pathway in normal differentiation of neuroblasts involves a differentiation factor called nerve growth factor (NGF) and its receptor (trk A). Most neuroblastoma cell lines are not responsive to NGF. Tumors that have high trk A are associated with a good biological response to therapy and a favorable prognosis. Trk A expression is inversely correlated with n-myc amplification.



## Clinical Presentation

Tumors arise anywhere there are sympathetic nerves from the brain to the pelvis. Most primary tumors occur in the abdomen (65%) (Fig. 39.1). The frequency of adrenal tumors is slightly higher (40%) in children compared to infants (25%). Infants have more thoracic and cervical primary tumors. The clinical presentation depends on the location of the primary. Often the symptoms are few and general. The patients often appear ill and fail to thrive. Those with cervical tumors (Fig. 39.2) present with a mass in the neck or with Horner's syndrome (meiosis, anhydrosis and ptosis). Those with thoracic primaries are diagnosed after a mass is found on a routine chest radiograph. The parents often find abdominal tumors when they are bathing the child. Abdominal tumors are more irregular than Wilms' tumors and more often cross the midline. Pelvic tumors may result in obstructive symptoms (urethral or colonic). Rarely they compress or infiltrate the iliac veins and/or arteries and present with lower extremity edema. Tumors that extend intraspinal in any of these locations may present with neurologic symptoms.

Two specific syndromes sometimes occur in patients with neuroblastoma. Opsoclonus-myooclonus is a constellation of symptoms including polymyoclonia, cerebellar ataxia with gait disturbance, and opsoclonus ("dancing eyes"). More than 50% of children with this syndrome have primary tumors located in the thorax. Although this syndrome is often associated with a favorable outcome, the symptoms may or may not resolve after tumor removal. Rarely, patients with neuroblastoma present with profuse watery diarrhea if the tumor secretes vasoactive intestinal peptide (VIP). The diarrhea resolves once the tumor is removed.

Ninety to ninety-five percent of tumors are biologically active secreting vanillylmandelic acid (VMA) or homovanillic acid (HVA) or other catecholamine metabolites. HVA represents degradation products of the dopamine pathway. More differentiated tumors produce norepinephrine and epinephrine that give rise to VMA. The VMA: HVA ratio has some prognostic implication with levels > 1 indicating tumors with a more favorable prognosis. Ten percent of neuroblastomas secrete acetylcholine and not catecholamines; these tumors tend to be more malignant.

There are two main patterns of metastatic spread in patients with neuroblastoma. The first is lymphatic spread. Thirty-five percent of children with apparently localized disease have lymph node metastasis at the time of presentation. Spread of tumor to lymph nodes outside the cavity of the primary tumor is considered disseminated disease but these patients may have a better outlook than those with other forms of disseminated disease. The other form of metastatic spread is hematogenous. The most common sites of metastasis are bone marrow, bone, liver and skin. Only rarely does neuroblastoma metastasize to lung or brain and these are usually manifestations of end-stage disease.

## Staging

Patients with neuroblastoma are staged based on the extent of primary disease and the presence or absence of metastases. Completeness of surgical resection is also factored into the staging system. There have been two main staging systems in the past but recently a new international staging system has been devised which combines the previous systems (Table 39.1).

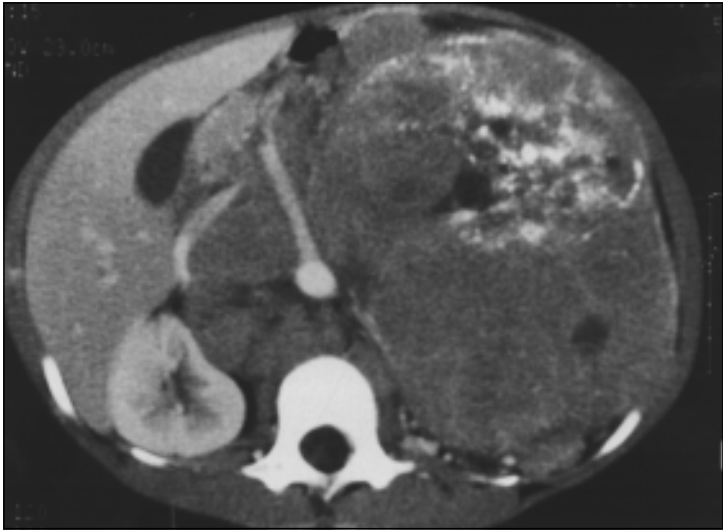


Fig. 39.1. Left adrenal neuroblastoma of large size and with marked calcification demonstrates medial aortic displacement and inferior displacement of the left kidney.

## Diagnosis

The diagnosis of neuroblastoma is based on the clinical signs and symptoms discussed previously. Once there is suspicion that a child has a neuroblastoma confirmatory testing is done. The child's urine is sent for HVA and VMA. The primary tumor is usually assessed with computed tomography (CT) scan which helps determine the extent of disease, invasion into surrounding structures, and lymph node involvement. In children with a primary abdominal tumor, involvement of the liver with tumor can also be assessed. For patients who present with neurologic symptoms, magnetic resonance imaging (MRI) can be helpful to define involvement of the spinal canal or cord. Metaiodobenzylguanidine (MIBG) is a compound resembling norepinephrine that binds to norepinephrine sites and is stored in neural crest cells. When this substance is labeled with  $^{123}\text{I}$  or  $^{131}\text{I}$  it can define the tumor or identify metastases even in those few patients with normal catecholamine levels. To assess for metastases, a bone scan and a plain chest radiograph are obtained. Computed tomography of the chest is only warranted if there are suspicious findings on a chest radiograph. Bone marrow aspirates are done from bilateral iliac crests as are trephine (core) bone marrow biopsies.

The diagnosis of neuroblastoma is confirmed by:

1. Biopsy with unequivocal diagnosis of neuroblastoma by light microscopy or
2. Bone marrow biopsy or aspirate with unequivocal tumor cells and increased serum or urine catecholamines.

Because of the heavy dependency of treatment plans on tumor biology, there is a strong rationale for sampling tumor in most cases.

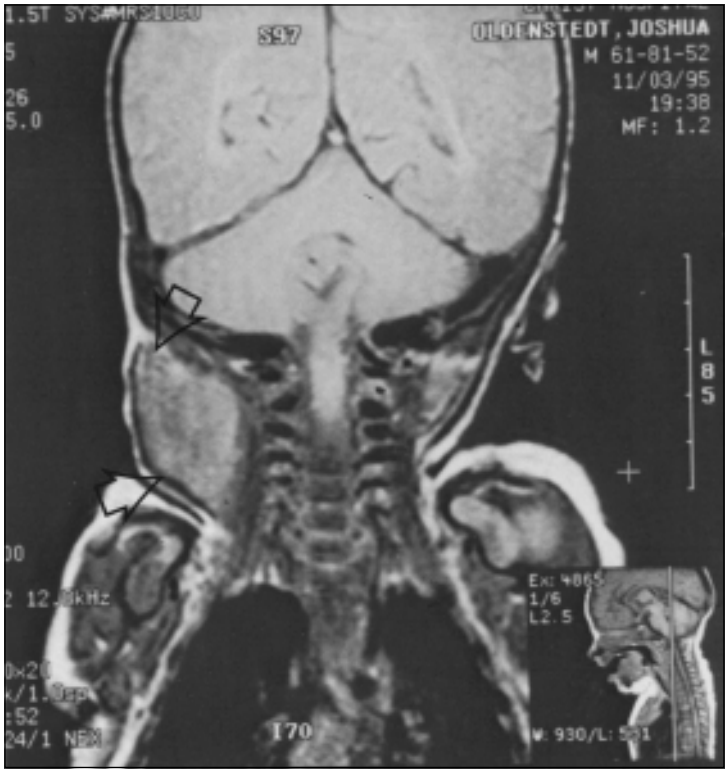

Fig. 39.2. Large white arrows indicate cervical neuroblastoma well shown by magnetic resonance imaging.

## Treatment

Treatment for patients with neuroblastoma involves a combination of surgery, radiation and chemotherapy. The goal of the initial surgical intervention in patients with neuroblastoma is to establish a diagnosis, provide tissue for biological studies (1-5 grams of tissue), stage the tumor surgically and excise completely those tumors where this is feasible. Complete excision should only be undertaken when there is not a concern for undue morbidity to vital organs or the patient. Sacrifice of major organs such as the kidney or spleen should be avoided, especially in children less than one year of age. If there are known distant metastases then the most accessible tissue is obtained for diagnosis and biological studies.

For thoracic tumors, a posterior-lateral thoracotomy is generally used. Attachments to the sympathetic chain and intercostal nerves are often found but en bloc excision of the chest wall is not required. Dumbbell shaped tumors that enter the neural foramina are generally treated initially with chemotherapy. These tumors were historically treated with radiation and laminectomy but had a higher rate of spinal column sequelae than those treated with chemotherapy.

For abdominal tumors, a generous transverse incision is usually employed. Ligation of feeding vessels is attempted early but care must be taken as larger tumors can rotate the aorta and distort the celiac, superior mesenteric and renal vessels. Lymph node sampling is performed regardless of the gross appearance of the nodes as inspection only has been shown to be in error 25% of the time. For sampling, non-contiguous nodes above and below the tumor are sampled. For those tumors in the abdomen and pelvis, contralateral lymph nodes are important. For infants less than one year of age, liver biopsy may be indicated if stage 4S (Table 39.1) disease is suspected.

For those patients who have incomplete resection initially, a delayed attempt at resection of residual tumor is undertaken at the end of induction chemotherapy (12-24 weeks after diagnosis). Surgery is not indicated for those patients who have progressive disease at this time. If there has been some response, the goal is complete resection of residual disease. The efficacy of eradication of the primary tumor at this time is not proven, but survivors have had complete resection more often than nonsurvivors. For patients with stage 4 and 4S, there is a 30% relapse rate if there is complete excision of the primary tumor and a greater than 90% rate in those without excision of the primary tumor.

Complications of surgical intervention include atelectasis, infection, ileus, and complications specific to the resection of the primary tumor. Overall the complication rate is low, estimated at 5-25%. Patients with localized tumors have lower rates of complication. Complications occur most frequently in infants after attempted excision of large tumors.

Chemotherapy is usually multiagent therapy. The most frequently used drugs include cyclophosphamide, cisplatin, doxorubicin and epipodophyllotoxins (teniposide-VM-26 and etoposide-VP-16). In general, drugs are combined so that the noncell cycle specific agents are given followed by the cell cycle specific agents.

Neuroblastoma is considered a radiosensitive tumor but the role of radiation therapy in patients with this tumor is now minimal due to the newer chemotherapy agents. Presently radiation therapy is used for regional lymph node metastasis if complete response is not achieved with chemotherapy, for infants with 4S disease who have respiratory distress from hepatomegaly secondary to tumor involvement, and in those patients who require total body irradiation for bone marrow transplantation.

Bone marrow transplantation is currently considered an investigational therapy for Stage 3 and 4 patients. Autologous bone marrow is given to the patients with or without purging to remove the neuroblastoma cells. Long-term results survival rates approach 40%. In these patients, recurrence most commonly occurs at the primary site of the tumor or in the bone or bone marrow.

## Outcomes

When considered alone, the two most important clinical variables for predicting outcome in neuroblastoma patients are the disease stage and the patient age at diagnosis. Disease free survival of all patients with stages 1, 2, or 4S is 75-90%. Infants less than one year of age with stage 3 and 4 have cure rates of 80-90% and 60-75%, respectively. Those children older than one year of age with stage 3 and 4 disease have 3-year survivals of 50% and 15%, respectively.

**Table 39.1. Staging of neuroblastoma**

<b>Children's Cancer Study Group (CCSG) System</b>	<b>Pediatric Oncology Group (POG) System</b>	<b>International Neuroblastoma Staging System</b>
Stage I: confined to the organ or structure of origin	Stage A: Complete gross resection of primary tumor, with or without microscopic residual disease; intracavitary lymph nodes not adherent to primary tumor; nodes adherent to the surface of or within the primary tumor positive	Stage 1: Localized tumor confined to the area of origin; complete gross excision, with or without microscopic residual disease; identifiable ipsilateral and contralateral lymph nodes negative microscopically
Stage II: Tumor extending in continuity beyond the organ or structure of origin, but not crossing the midline; regional lymph nodes on the ipsilateral side possibly involved	Stage B: Grossly unresected primary tumor; nodes and nodules the same as in stage A	Stage 2A: Unilateral tumor with incomplete gross excision; identifiable ipsilateral and contralateral lymph nodes negative microscopically  Stage 2B: Unilateral tumor with complete or incomplete gross excision; with positive ipsilateral regional lymph nodes; identifiable contralateral lymph nodes negative microscopically
Stage III: Tumor extending in continuity beyond the midline; regional lymph nodes possibly involved bilaterally.	Stage C: Complete or incomplete resection of primary tumor; intracavitary nodes not adherent to primary tumor histologically positive for tumor; liver as in stage A	Stage 3: Tumor infiltrating across the midline with or without regional lymph node involvement; or unilateral tumor with contralateral regional lymph node involvement; or midline tumor with bilateral lymph node involvement.
Stage IV: Remote disease involving the skeleton, bone marrow, soft tissue, and distant lymph node groups	Stage D: Dissemination of disease beyond intracavitary nodes (i.e., extracavitary nodes, liver, skin, bone marrow, bone, etc.)	Stage 4: Dissemination of tumor to distant lymph nodes, bone, bone marrow, liver or other organs (except as defined in stage 4S)
Stage IV-S: As defined in stage I or II, except for the presence of remote disease confined to the liver, skin or marrow (without bone metastases)	Stage DS: Infants less than one year of age with stage IV-S disease.	Stage 4S: Localized primary tumor as defined for stage 1 or 2 with dissemination limited to liver, skin, or bone marrow

Presently, trials are underway to randomize patients into low, intermediate and high risk groups based on age, stage, histology and biologic markers as discussed in previous sections. The therapies would then be streamlined based on the risk group in an attempt to minimize morbidity from therapy while maximizing survival. Low risk patients may get no or minimal chemotherapy, intermediate risk patients would get moderately aggressive chemotherapy with or without a consideration for radiation therapy. High-risk patients, in whom survival has not improved in the past three decades, would get chemotherapy, radiation therapy followed by bone marrow transplantation.

### *Selected Readings*

1. Grosfeld JL. Neuroblastoma. In: O'Neill Jr. JA et al. eds. *Pediatric Surgery*, 5<sup>th</sup> Edition. St. Louis: Mosby 1998; 405-419.
2. Shimada H et al. Identification of subsets of neuroblastoma by combined histopathologic and N-myc analysis. *J Natl Cancer Inst* 1995; 87:1470.
3. Haase GM. Head and neck neuroblastomas. *Semin Pediatr Surg* 1994; 3:194.
4. Black CT. Neuroblastoma. In: Andrassy RJ ed. *Pediatric Surgical Oncology*. Philadelphia: W.B. Saunders Company 1998; 175-211.

# Liver Tumors

*P. Stephen Almond*

## Incidence

Pediatric liver tumors are a sufficiently diverse and uncommon group of tumors that determine the true incidence of each is difficult. Together, they make up about 2% of all pediatric tumors and the majority (75%) are malignant (Table 40.1). This Chapter focuses on hepatoblastoma, hemangioendothelioma, hepatocellular carcinoma, embryonal sarcoma, focal nodular hyperplasia, and mesenchymal hamartoma.

The incidence of each tumor varies with age and gender (Table 40.1). In infancy, hemangioendothelioma is more common followed by hepatoblastoma and mesenchymal hamartoma. Thereafter, hepatoblastoma is more common followed by hemangioendothelioma, hepatocellular carcinoma, sarcoma, and mesenchymal hamartoma.

## Etiology

The etiology of most hepatic tumors is obscure. Hepatoblastomas arise from embryonal tissue and have been associated with trisomy 2, trisomy 20, and chromosome 11 abnormalities. Hemangioendotheliomas occur due to abnormal mesenchymal development leading to large, multiple, thin-walled collections of vessels within the liver. Hepatocellular carcinoma is associated with many chronic liver diseases that are characterized by a continuous cycle of injury and repair, suggesting recurrent injury or faulty tissue repair as etiologies. Embryonal sarcomas and mesenchymal hamartomas are also of mesodermal origin. The etiology of focal nodular hyperplasia (FNH) is unclear.

## Clinical Presentation

Most children present with an abdominal mass, abdominal distension, or gastrointestinal symptoms (i.e., vomiting, anorexia).

## Diagnostic Studies

The preoperative work-up determines the tumor's organ of origin, the extent of the primary tumor, and presence of metastatic disease. Laboratory studies include a complete blood count, prothrombin time, partial thromboplastin time, platelet count, liver function tests, hepatitis profile, and an alpha-fetoprotein level. Children with liver tumors frequently are anemic (60%), have abnormal platelet counts and, in hepatoblastoma and hepatocellular carcinomas, an elevated alpha-fetoprotein level.

**Table 40.1. Incidence of liver tumors for infants (< 1 year old) and children (< 15 years old) and the male to female ratio of each**

	Age		Female/Male
	< 1 year	< 15 years	
Hepatoblastoma	26 %	28%	1:1.6
Hemangioendothelioma	62 %	27%	1.6:1
Hepatocellular carcinoma	0.6 %	16%	1:1.8
Embryonal sarcoma	0.6 %	7.7%	1.7:1
Focal nodular hyperplasia	1 %	5%	3.4:1
Mesenchymal hamartoma	8 %	7%	1:1
Other	1.8 %	9.3%	

Radiographic studies should include a chest x-ray, an abdominal ultrasound and a computed tomography (CT) scan of the chest, abdomen, and pelvis. The chest x-ray and CT of the chest are done to rule out pulmonary metastasis. The abdominal ultrasound is done to determine the organ of origin, the size, location, consistency (solid vs. cystic), and vascularity of the tumor, and the patency of the portal and hepatic veins. A CT scan of the abdomen further defines the extent of the tumor and its relationship to other intraabdominal organs.

### Pathology

Hepatoblastoma (Fig. 40.1) can involve the right (58%), left (15%), or both lobes (27%) of the liver. Grossly, the tumor is usually singular, large, brown, and with areas of hemorrhage and necrosis. Microscopically, they are classified as epithelial, mesenchymal, or anaplastic. Epithelial tumors have both fetal and embryonal cells where mesenchymal tumors have fetal, embryonal, and mesenchymal tissue. The small cell, or anaplastic hepatoblastoma, is characterized by small, blue cells, with little cytoplasm and hyperchromatic nuclei.

Hepatocellular carcinomas are large, multicentric, dark tumors that frequently (up to 80%) involve both lobes of the liver. Microscopically, large, dark cells with many nucleoli and tumor giant cells characterize hepatocellular carcinomas. In contrast, fibrolamellar hepatocellular carcinoma is usually a single mass with a pseudocapsule characterized by tumor cells that are divided into lobules by fibrous stromal bands and containing eosinophilic inclusions.

Embryonal sarcomas are usually singular, large, soft, yellow-colored lesions involving the right lobe (75%). The lesion has cystic and solid components and frequently exudes a light colored, gelatinous material when cut. Microscopically, there is a pseudocapsule surrounding spindle-shaped cells suspended in an "acidic, mucopolysaccharide-rich ground substance." The majority of tumor cells contain round, PAS positive, intracellular inclusions.

Hemangioendotheliomas are well-circumscribed, single or multicentric tumors of various sizes. Microscopically, they are lined by endothelial cells and separated from each other by connective tissue. Mesenchymal hamartomas (Fig. 40.2) are large, complex (cystic and solid) tumors that usually involve the right lobe (75%). Microscopically, the bulk of the tumor is mesenchyme but may also contain cysts,



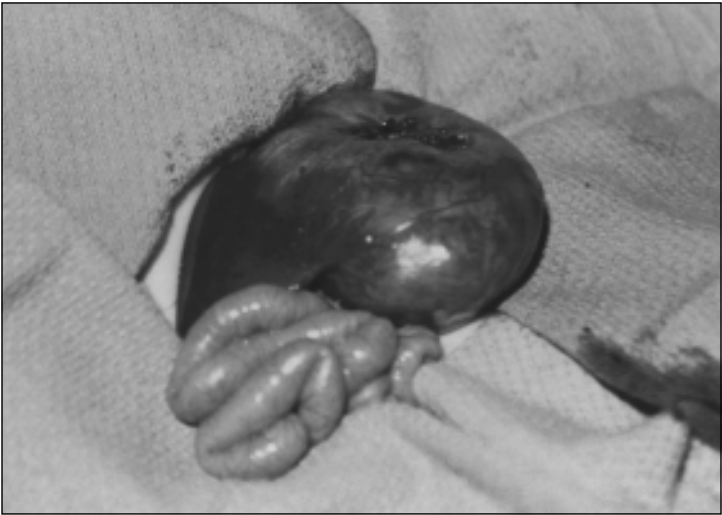

Fig. 40.1. Intraoperative photograph of an intrahepatic hepatoblastoma involving much of the left hepatic lobe.

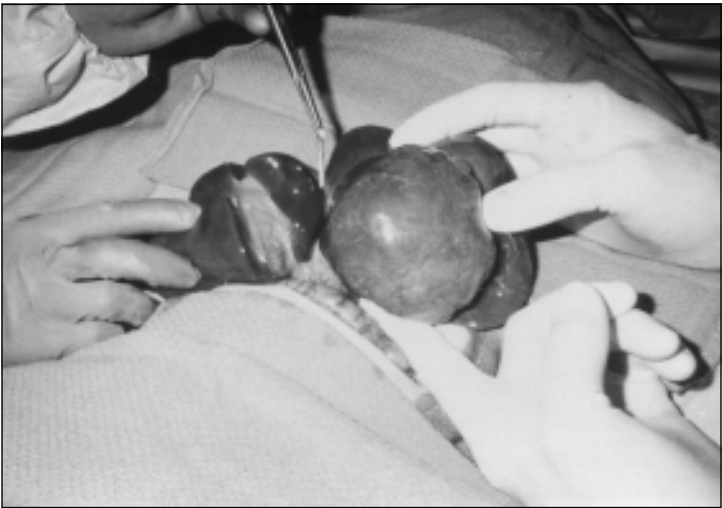


Fig. 40.2. Infrahepatic nodular tumor of the left lobe that proved after excisional biopsy to be a mesenchymal hamartoma.

bile ducts, hepatocytes, and inflammatory cells. Focal nodular hyperplasia is a well-circumscribed, irregularly shaped, firm, light-colored tumor that occurs with equal frequency in both lobes. The surrounding capsule frequently contains large blood vessels. Microscopically, the tumor consists of normal appearing hepatocytes that are subdivided into smaller lesions by fibrous connective tissue septa.

### **Classification and Staging**

The Children's Oncology Group (COG) uses the Intergroup Staging System for the staging of hepatoblastomas and hepatocellular carcinomas. In children with stage I disease, the tumor is confined to the liver and totally resected. In children with stage II disease, the primary liver tumor is resected but there is evidence of microscopic residual disease in the remaining liver or outside the liver. Children with stage III disease have either gross tumor left behind, positive nodes, or tumor spill at operation. Children with stage IV disease have metastatic disease.

### **Treatment**

All children with solid lesions of the liver are explored through a transverse upper abdominal incision. Ascitic fluid is sent for cytology. Suspicious lesions outside the liver are biopsied and sent for frozen section. If possible, the primary tumor is removed and the margins marked with titanium clips. If the tumor is not resectable (i.e., tumor in both lobes, tumor invading the portal vein, or tumor at the hepatic veins), the abdomen is explored to confirm that the tumor is confined to the liver. Children with unresectable tumors confined to the liver should be considered for transplantation.

All children with a malignant tumor receive postoperative chemotherapy. Therefore, a long-term, central venous catheter is placed at the end of the procedure. Children with hepatoblastoma and hepatocellular carcinoma are entered into the COG study group and treated with cisplatin, vincristine, and 5-FU. Children with embryonal sarcomas are treated with vincristine, actinomycin-D, and cyclophosphamide.

Children with hemangioendotheliomas are not routinely explored as the majority spontaneously involute in the first few years of life. In the interim, they are followed closely for signs/symptoms of congestive heart failure, respiratory compromise, and thrombocytopenia (Kasabach-Merritt syndrome). Congestive heart failure is caused by the large arteriovenous shunt within the liver and is treated with digoxin and Lasix. Respiratory compromise is due to compression of the thoracic cavity by the tumor. In these cases the child is supported (i.e., intubated if necessary) while efforts are made to decrease the size of the tumor. Steroid, radiation, alpha-interferon, and embolization have been used for this purpose. Thrombocytopenia is due to platelet trapping within the hemangioendothelioma and has been treated with aspirin, alpha-interferon, and steroids. Indications for operation include cardiac decompensation and suspicion of malignancy. At operation, the hepatic artery and even branches of the portal vein may require ligation.

## Outcomes

For benign liver tumors, complete surgical resection is curative. Survival for children with hemangioendothelioma varies from 32-75%. For malignant tumors, survival is better in children with stage I and stage II disease (vs. stage III and stage IV disease) and hepatoblastoma (vs. hepatocellular carcinoma and embryonal sarcoma). The 2-year survival for children with stages I or stage II hepatoblastoma is 90% vs. 67% for stage III disease. The overall survival for children with hepatocellular carcinoma and embryonal sarcomas is 20%.

## Selected Readings

1. Rowe MI, O'Neill Jr. JA, Grosfeld JL et al. Liver tumors. In: Rowe MI, O'Neill Jr. JA, Grosfeld JL et al, eds. *Essentials of Pediatric Surgery*. St. Louis: Mosby-Year Book 1998.
2. JM Becker, MS Heitler. Hepatic hemangioendotheliomas in infancy. *SGO* 1989; 168:189-200.
3. Chandra SR, Stocker JT. Hepatic neoplasms. In: Stocker JT, Dehnerj LP eds. *Pediatric Pathology, Chapter 19: The liver, gallbladder, and biliary tree*. Philadelphia: JB Lippincott Company 1992; 753-776.
4. Urban CE, Mache CJ, Schwinger W et al. Undifferentiated (Embryonal) Sarcoma of the Liver in Childhood. *Cancer* 1993; 72:251-6.
5. King DR. Liver tumors. In: O'Neill Jr. JA et al, eds. *Pediatric Surgery, 5<sup>th</sup> Edition*. St. Louis: Mosby 1999; 421-430.

# Teratomas

*P. Stephen Almond*

## Incidence

Teratomas are interesting but uncommon lesions, probably occurring in 1 in 20,000-40,000 live births. The exact incidence is difficult to ascertain. The anatomic distribution of these lesions varies between reporting institutions, but the sacrococcygeal lesion appears to be most common.

Sacrococcygeal teratomas account for the majority of cases (45-65%). The next most common locations are: gonadal (10-35%), mediastinal (10-12%), retroperitoneal (3-5%), cervical (3-6%), presacral (3-5%), and central nervous system (2-4%).

## Etiology

Teratomas arise from germ cells or other totipotent cells. Primordial germ cells appear during the third week of gestation in the wall of the yolk sac near the allantois. They move along the dorsal mesentery of the hindgut, reaching the genital ridges by about the sixth week of gestation. Germ cells that do not complete this journey can develop into teratomas. While the totipotent nature of germ cells and their path of migration explain the location and pathology of the more common teratomas (sacrococcygeal and gonadal), intracranial and mediastinal locations are more difficult to explain.

## Sacrococcygeal Teratoma

### *Clinical Presentation*

Sacrococcygeal teratoma (Fig. 41.1) is the most common solid tumor in the neonate. Prenatal discovery by ultrasound is becoming common. Polyhydramnios, placentomegaly, and gestational age less than 30 weeks are associated with a poor prognosis. The lesions vary in size, shape, location, and extension. Interestingly, 75% occur in females. On examination, the visible portion of the lesion is skin covered and posterior to the anus. In some patients all or part of the lesion may be in the retrorectal space and/or the retroperitoneum. In these cases, patients will present with rectal pain, constipation, and/or a mass. The differential diagnosis is quite long and includes lipoma, myelocystocele, pilonidal cysts, sacral dimple, diastematomyelia, meningocele, epidermal sinus, sacral agenesis, fetus in fetu, parasitic twin, hamartoma, hemangioma, neuroblastoma, chordoma, rectal duplication, and sarcoma. Associated anomalies occur in 10-15% of cases and include imperforate anus, anorectal stenosis, anorectal agenesis, sacral hemivertebra, absence of the sacrum

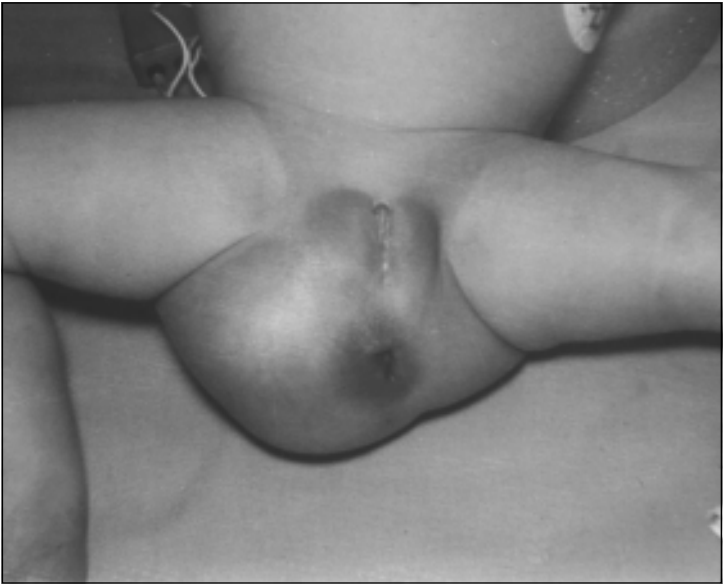

Fig. 41.1. View of the most common teratoma of childhood, the sacrococcygeal teratoma. This tumor occurs predominantly in females and generally arises between the tip of the coccyx and the anus.

and coccyx, and anterior meningocele. Currarinos triad is the association of a presacral mass with anorectal stenosis and a sacral deformity.

### *Diagnosis*

The diagnosis of sacrococcygeal teratoma is usually made by physical examination. A chest xray is obtained to rule out metastatic disease. An abdominal film may demonstrate calcifications within the mass or displacement of the bowel by the mass. Ultrasonography is useful to determine the nature of the lesion (solid vs. cystic), the presence of an intraabdominal component, and the presence of liver involvement. Alpha-fetoprotein (AFP) and beta human chorionic gonadotropin (beta-hCG) are serum tumor markers associated with teratomas and should be obtained preoperatively and followed postoperatively.

### *Classification*

Sacrococcygeal teratomas are classified based on the location of the lesion. Type I lesions are external with a small presacral component (45%). Type II lesions have an external and a significant presacral component (34%). Type III lesions have a small external component with the majority of the tumor being retroperitoneal (9%). Type IV lesions have no external component, being entirely presacral (10%).

### *Treatment*

Sacrococcygeal teratomas should be completely excised. Type I and II lesions can be approached posteriorly through either an inverted chevron or sagittal incision. Type III and IV lesions require an additional transverse lower abdominal incision. Essential components of the procedure include complete removal of the intact tumor, ligation of the middle sacral artery, and excision of the coccyx with the tumor. If the lesion is benign (97%), no further therapy is indicated. These patients should be evaluated every 3 months for the first two years with emphasis on rectal examination and AFP levels. If the lesion is malignant, adjuvant chemotherapy with cisplatin, bleomycin, and vinblastine is indicated.

## **Ovarian Teratoma**

### *Clinical Presentation*

Ovarian and sacrococcygeal teratomas occur with near equal frequency in infants. In older children, however, ovarian teratomas are more common and account for 50% of all pediatric ovarian tumors. Abdominal pain, mass, and vomiting are the most common presenting complaints. With the child supine, the mass is often visible and movable. If torsion has occurred, the abdomen may be tender. The differential diagnosis includes pregnancy, ovarian torsion, omental or mesenteric cyst, lymphangioma, and lymphoma.

### *Diagnosis*

Abdominal xrays may show displacement of the normal gas pattern and/or calcifications within the tumor. Ultrasonography can determine the organ of origin, assess the contralateral ovary, and determine whether the lesion is solid or cystic. Serum AFP and beta-hCG levels should be measured.

### *Treatment*

The indications for operation include an ovarian lesion > 5 cms, a complex ovarian mass, and torsion. At operation, the surface of the affected ovary should be inspected to insure that the capsule is intact and smooth. In addition, the peritoneum and contralateral ovary should be evaluated to rule out metastasis and bilateral lesions, respectively. If the affected ovary has a smooth, intact surface, the contralateral ovary is normal, and there is no ascites or evidence of metastasis, the tumor should be removed. Since 50% of ovarian tumors are teratomas and > 90% of these are benign, an attempt should be made to preserve any remaining ovarian tissue. If there are bilateral teratomas, both should be enucleated, with preservation of ovarian tissue. If there is evidence of metastatic disease, diaphragmatic scraping, peritoneal washes, and biopsies should be obtained. If there are immature elements in the tumor, peritoneal implants, or peritoneal glial implants, the tissue should be graded according to the Norris classification system. Grade II and III lesions require postoperative cisplatin-based chemotherapy.

## **Retroperitoneal Teratomas**

### *Clinical Presentation*

Retroperitoneal teratomas occur with equal frequency between the genders. Children usually present with gastrointestinal symptoms or abdominal mass. In addition to chest xray, abdominal plain films, and ultrasound, a CT scan may be useful to determine the relationship of the tumor to other retroperitoneal structures and distinguish it from a primary renal or adrenal tumor. The differential diagnosis includes those listed for ovarian teratomas as well as Wilms' tumor, neuroblastoma, and sarcoma.

### *Treatment*

Retroperitoneal teratomas should be removed. The vast majority are benign and require no further treatment. Patients with malignant lesions and those with high-grade immature elements should be treated with cisplatin-based chemotherapy.

## **Mediastinal Teratomas**

### *Clinical Presentation*

Mediastinal teratomas may arise in the mediastinum, the pericardium, or the heart. The latter two are mentioned only for completeness. Mediastinal teratomas occur with equal frequency between the genders. They usually present with respiratory symptoms or chest pain. A small portion of boys with mediastinal teratomas may present with precocious puberty as a result of a beta-hCG secreting tumor. The differential diagnosis includes thymoma, parathyroid adenoma, bronchogenic cysts, cystic hygroma, duplications, aneurysms, lymphoma, lipoma, myxoma, and thyroid goiter.

### *Diagnosis*

Chest radiograph and CT scan are necessary to confirm the presence of a mass and define its relationship with other intrathoracic structures. AFT and beta-hCG levels should be drawn preoperatively and followed in the postoperative period. Boys with beta-hCG secreting mediastinal teratomas should have chromosomal analysis as there is an association between these lesions and Klinefelter's syndrome.

### *Treatment*

The treatment is surgical resection. Children with malignant lesions and those with tumors containing high-grade immature elements also receive cisplatin-based chemotherapy.

## **Head and Neck Teratomas**

### *Intracranial Teratomas*

#### **Clinical Presentation**

Intracranial teratomas have a bimodal distribution occurring in infants < 2 months and children 12-16 years. They usually originate from the pineal gland and increase

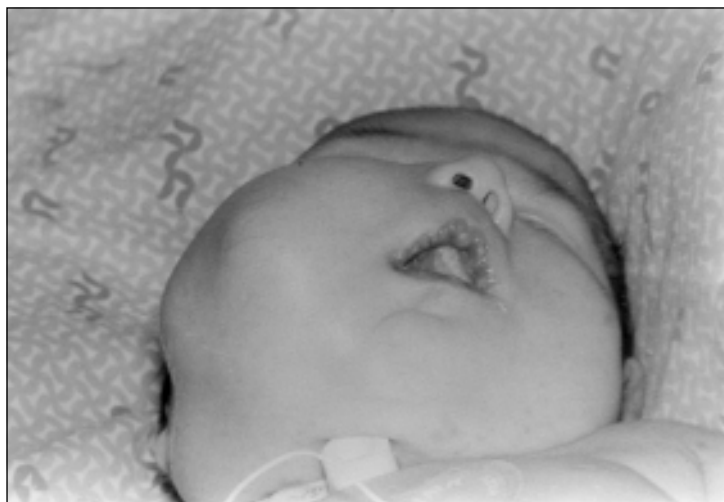

Fig. 41.2. Tonsillar teratoma invading the sinuses and cheek of a newborn female.

the intracranial pressure. In the newborn this is manifest as obstructive hydrocephalus and in the child as headaches, visual changes, seizures, and vomiting. On CT or MRI, teratomas are typically calcified, supratentorial, midline lesions. In newborns, most of these lesions are benign. In older children, the majority are malignant.

### **Treatment**

Complete resection, although rarely possible, is the only chance for long-term survival. Partial resection will provide palliation of symptoms in some cases.

### ***Other Head and Neck Teratomas***

#### **Clinical Presentation**

Teratomas involving the neck or aerodigestive tract are rare, gender nonspecific lesions. They can obstruct the oropharynx leading to polyhydramnios and pulmonary hypoplasia in the fetus and respiratory distress in the newborn. They may involve the neck (thyroid teratoma), the oropharynx (Fig. 41.2), or the nasopharynx. The differential diagnosis includes cystic hygroma, lymphangioma, branchial cleft cyst, goiter, and neuroblastoma. Plain films show calcifications, while CT and/or MRI demonstrate the extent of the lesion. The majority are benign and complete resection is the treatment of choice.

#### **Testicular Teratomas**

Testicular teratomas occur in infants and young adults and account for 7% of all teratomas. They usually present as a painless testicular mass. Ultrasound may show calcifications. Alpha-fetoprotein and beta-hCG should be drawn preoperatively. The



treatment of choice is high ligation of the cord. A retroperitoneal lymph node dissection is not indicated. Patients with malignant teratomas should receive chemotherapy.

### *Selected Readings*

1. Azizkhan RG, Caty MG. Teratomas in childhood. *Curr Opin Pediatr* 1996; 8:287-292.
2. Pringle KC. Sacrococcygeal teratoma. In: Puri P ed. *Newborn Surgery*. Oxford: Butterworth Heinemann 1996; 505-511.
3. Altman RP, Randolph JG, Lilly JR. Sacrococcygeal teratoma: American Academy of Pediatrics Surgical Section Survey-1973. *J Pediatr Surg* 1974; 9:389.
4. Currarino G, Coln D, Votteler T. Triad of anorectal, sacral, and presacral anomalies. *Am J Roentgenol* 1981; 137:395.

# Ovarian Masses

*Robert M. Arensman*

## Incidence

Ovarian masses—solid or cystic—are rare occurrences in childhood. With the advent of ultrasonography, the detection of these rare events has occurred much more frequently, especially for cystic lesions. Nonetheless, the total occurrence of these lesions remains low.

## Etiology

Exact etiologic causes of either cystic or solid ovarian masses remain unknown. In neonates the appearance of cystic lesions is clearly related to the influence of maternal steroid production. These simple follicular cysts generally regress quickly and completely once the neonate is no longer within the milieu of high maternal hormone influence. The appearance of cystic lesions later in life is likely due to problems of hormonal regulation and balance, but the exact mechanisms are unknown at this time. Solid ovarian masses are predominantly benign or malignant tumors and are often associated with chromosomal anomalies. The most common of these anomalies occur on chromosomes 1 and 12, but problems with 5, 7, 9, 17, 21, and 22 have all been reported. The exact biochemical significance of these abnormalities has not yet been elucidated.

## Clinical Presentation

Ovarian masses may go undetected in many cases when they remain small and produce no symptoms. With increase in size, pain is the most common complaint. The pain is usually chronic but generally is not severe. If torsion occurs, the pain is severe, constant, and often associated with signs of peritoneal irritation on physical examination.

In children, parental discovery of an abdominal mass is often the first complaint. Acts of bathing or dressing often lead to abdominal examination and notice of the mass. In cases of endocrinologically active masses, the first noticeable abnormality may be premature menarche or isosexual precocity.

## Diagnosis

Ultrasonography has become the principle method to diagnose ovarian pathology. This modality quickly, accurately, noninvasively localizes the ovarian structures without the use of radiation. Ultrasonography accurately characterizes ovarian masses

as cystic, solid, or mixed, and demonstrates the anatomic relationships to other pelvic structures.

Computed tomography (CT) coupled with intravenous contrast infusion may provide additional information. CT is particularly useful especially to demonstrate variations in solid tissue density, such as intra-ovarian fat planes so characteristic of teratomas.

Serum markers such as alpha fetoprotein and beta human chorionic gonadotropin may be particularly helpful for both diagnosis and eventual monitoring in cases of ovarian germ cell tumors (i.e., endodermal sinus tumor, choriocarcinoma).

## Classification and Staging

The ovarian masses are first distinguished as cystic or solid. The cystic lesions can be further classified as simple or complex. If there is any solid component within the ovarian mass it should be classified within the types of ovarian tumors (Table 42.1). Malignant ovarian tumors are staged by the gross pathologic findings at laparotomy and according to the cellular origin of the tumor (Table 42.2).

## Treatment

Simple cystic lesions are often serendipitous findings of antenatal ultrasound or neonatal examinations done as part of an evaluation of congenital anomalies. The majority of these lesions are simple follicular cysts associated with high maternal steroid production. When reasonably small (< 7 cm) torsion is unlikely, regression occurs rapidly, and serial ultrasound examination to monitor disappearance is sufficient. If larger than 7 cm, surgical exploration with cystectomy is generally safer (Fig. 42.1). Clearly, large cysts should be removed to relieve pressure and its consequent pain, to prevent torsion, and to insure that it is not part of a large cystic teratoma. In all these situations, attempt should be made to preserve normal and functioning ovarian tissue.

Solid ovarian tumors need full surgical removal with an attempt to assure margins of resection that harbor no residual tumor if they are malignant. This may mandate removal of Fallopian structures, removal of peri-ovarian structures, or radical resection of other pelvic structures involved with the tumor. Careful inspection of contralateral structures is mandatory because solid ovarian tumors, especially teratomas (Fig. 42.2), have been reported bilaterally in up to 10% of cases. Few surgeons would suggest a need to bivalve the contralateral ovary if inspection is normal although this approach has previously been recommended.

In conjunction with surgical extirpation, a thorough search for metastatic disease is indicated—both radiologically and by careful physical examination at the time of surgery. This allows for appropriate staging and directs further therapy. Disease extending beyond the ovary will absolutely require adjunctive chemotherapy. Today this will generally involve the use of a platinum agent coupled with either bleomycin, etoposide, or vinblastine. Currently, multi modal therapy can achieve 60-80% survival rates up to five years after diagnosis.

**Table 42.1. Classification of ovarian tumors in children**

<b>Germ cell tumors</b>		
	Germinoma Embryonal Carcinoma	Most primitive germ cell tumor
	Endodermal sinus Tumor	Most common malignancy of ovarian origin in childhood. Elevated levels of alpha fetoprotein
	Choriocarcinoma	Tumor resembling placental tissue; elevated levels of beta human chorionic gonadotropin
	Gonadoblastoma	Tumor with features of dysgenetic gonadal tissues
	Teratomas and Teratocarcinomas	Germ cell origin, generally represent the three distinct cell lines of mature tissue origin
<b>Stromal tumors</b>		
	Granulosa-Thecal Tumor	Usually produces estrogen, isosexual precocity
	Androblastoma	Usually produces testosterone and virilization

**Table 42.2. Ovarian tumor staging**

<b>Germ cell tumors</b>	<b>Epithelial Tumors</b>
I Limited to ovaries Negative peritoneal washings Markers decrease after surgery	IA One ovary; capsule intact IB Both ovaries, capsules intact IC One or both ovaries; capsular rupture; positive washings
II Microscopic residual disease Lymph nodes positive (< 2 cm)	II One or both ovaries with pelvic extension
III Gross residual tumor Lymph nodes positive (> 2cm) Contiguous visceral involvement Positive peritoneal washings	III One or both ovaries, metastases outside pelvis or positive nodes
IV Distant Metastases	IV Distant Metastases




Fig. 42.1. Large left ovarian cyst in an infant. Large arrow points to midline uterus while the small arrows indicate the fimbriated ends of the Fallopian tube. Left ovary is massively distended with a simple cyst.

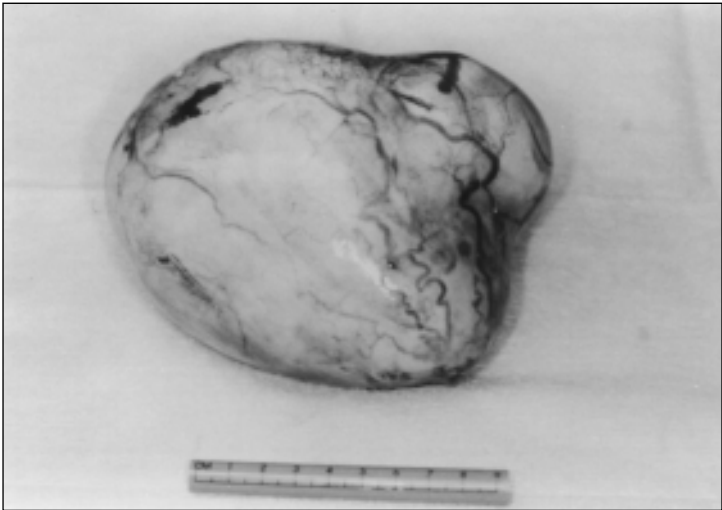


Fig. 42.2. Large ovarian teratoma after surgical resection. Tortuous vessels and irregularity of surface suggest malignancy but pathological slides revealed benign ovarian teratoma with predominantly glial elements.

***Selected Readings***

1. Lovvorn HN 3<sup>rd</sup>, Tucci LA, Stafford PW. Ovarian masses in the pediatric patient. *AORN Journal* 1998; 67:568-84.
2. Lazar EL, Stolar CJ. Evaluation and management of pediatric solid ovarian tumors. *Semin Pediatr Surg* 1998; 7:29-34.
3. Helmraath MA, Shin CE, Warner BW. Ovarian cysts in the pediatric population. *Semin Pediatr Surg* 1998; 7:19-28.
4. Hawkins EP. Germ cell tumors. *Am J Clin Path* 1998; 109:S82-8.
5. Rescorla FJ. Germ cell tumors. *Semin Pediatr Surg* 1997; 6:29-37.

# Testicular Tumors

*Daniel A. Bambini*

## **Incidence**

Testicular tumors account for less than 2% of pediatric solid tumors. In the United States, the incidence in males less than 15 years of age is 0.5 per 100,000. Only 2-5% of all testicular tumors occur in children. Racial differences are present; the greatest incidence occurs in Asian populations.

## **Etiology**

The etiology of testicular tumors is unknown, yet there is an association with the dysplastic undescended testicle. Orchidopexy may or may not protect against malignant degeneration if performed early. Children with undescended testicle remain at high risk after surgery. Almost one quarter of cryptorchid-associated testicular tumors occur in the contralateral descended testicle.

## **Clinical Presentation**

Peak incidence in children is 2 years with a second increase in frequency during puberty. Testicular tumors in children present as painless, nontender masses often discovered incidentally during evaluation of an inguinal hernia. One third of patients will have an associated hydrocele. Hormonal effects from Sertoli or Leydig cell tumors may produce the initial symptoms. Leydig cell tumors are the most common gonadal, stromal tumor in children and may cause macrogenitosomia, gynecomastia, or precocious puberty. Sertoli cell tumors also may present as precocious puberty and are associated with cardiac myxoma, endocrinopathies, and gynecomastia.

Physical examination reveals a painless, firm mass that fails to transluminate. Asymmetry increases the suspicion of a testicular tumor. Physical examination should also include a close evaluation of the abdomen and contralateral testicle. The differential diagnosis includes inguinal hernia, hydrocele, orchitis, testicular torsion, traumatic contusion, and tumor. Meconium peritonitis rarely causes a scrotal mass in neonates, and splenogonadal fusion may also resemble a testicular tumor.

## **Diagnosis**

The definitive diagnosis of testicular tumor is made from surgical exploration and biopsy. Radiographic evaluation should also include scrotal and abdominal ultrasound which further define the lesion and may identify other genitourinary anomalies or retroperitoneal lymphadenopathy. CT scan is the preferred method for

evaluation of the chest and abdomen for metastatic disease. If disease appears localized, CT scans are not performed until after the diagnosis of malignancy is confirmed. Serum levels of human chorionic gonadotropin (HCG) and alpha fetoprotein (AFP) are obtained preoperatively.

### Pathology

The majority (70%) of childhood testicular tumors are of germ cell origin. Embryonal carcinomas and yolk sac (endodermal sinus) tumors account for approximately 40%. Yolk sac tumors are the most common testicular tumors of childhood and the mean age at presentation is three years. Almost all children with yolk sac tumors will have elevated serum AFP levels (normal < 20 ng/ml).

Seminomas are very rare in children, but it is the most common malignancy to develop in the undescended testicle. The overall risk of malignancy in undescended testicle(s) is 5-30 times greater than that of a normally descended testicle.

Nongerminal cell tumors account for approximately 30% of all testicular tumors in children. Sarcomas account for 33% of nongerminal cell testicular tumors and rhabdomyosarcoma is the most common of these.

### Classification and Staging

Testicular tumors are classified as tumors of germ cell origin or as tumors arising from the supporting stromal tissue within the testis (Table 43.1). Clinical staging (Table 43.2) is based upon physical examination, surgical exploration, and radiographic findings (i.e., U/S, CT, CXR, etc.)

### Treatment

Exploration is via an inguinal incision. A transscrotal approach to biopsy or excision increases the risk of local recurrence and should not be used. The inguinal canal is entered and the cord structures are encircled. The venous and lymphatic drainage are occluded to prevent tumor spread during manipulation of the tumor. The testicle along with the cremasteric muscle, gubernaculum and the fascia enveloping the testicle is delivered into the surgical field (Fig. 43.1). If a mass is identified, wedge biopsy with frozen section is performed. Malignant tumors are treated by radical orchiectomy. Benign lesions can be treated by enucleation or simple orchiectomy. In addition, children with Stage II or III disease require systemic chemotherapy and modified retroperitoneal lymphadenectomy. Teratocarcinomas have lymph node involvement in 30% of children at the time of presentation; modified radical lymph node dissection is recommended.

For yolk sac tumors, lymph node disease is absent in 80-90% of children at the time of diagnosis. However, 10-20% with Stage I tumors will develop relapse which can be identified by an increasing AFP. A serum AFP level is drawn 3-4 weeks following resection. If the level is normal and there is no evidence of metastatic disease, radical orchiectomy alone is adequate treatment. Monthly AFP level and CXR are obtained for two years. A persistent or rising AFP level is an indication for chemotherapy. The addition of modified radical lymph node dissection is controversial.



**Table 43.1. Classification of testicular tumors and relative incidence**

<b>Germ Cell Tumors</b>	<b>71%</b>
Yolk Sac (Endodermal sinus)	15%
Embryonal Carcinoma	21-40%
Teratoma	19-26%
Teratocarcinoma	10-21%
Mixed Germ Cell	5-10%
Seminoma	2-3%
Choriocarcinoma	< 1%
<b>Sex Cord-Stromal Tumors</b>	<b>9%</b>
Sertoli Cell	3%
Leydig Cell	5%
Granulosa Cell	1%
Mixed or Other	1%
<b>Other Tumors</b>	<b>20%</b>
Paratesticular (Rhabdomyosarcoma, Sarcoma, etc.)	13%
Lymphoma/Lymphoid	5%
Adrenal Rests	< 1 %
Other Tumor or Tumor-like Lesions	2%

**Table 43.2. Staging system for pediatric testicular tumors**

Stage	Description
I	Tumor confined to the testis and completely excised by radical inguinal orchiectomy
II	Transscrotal orchiectomy with gross tumor spill, microscopic residual in scrotum or less than 5 cm from proximal spermatic cord, lymph nodes less < 2cm
III	Retroperitoneal lymph nodes > 2 cm
IV	Distant metastasis (above diaphragm, liver)

Rhabdomyosarcoma is the most common paratesticular neoplasm. Initial treatment includes radical orchiectomy, unilateral pelvic and retroperitoneal lymphadenectomy, and systemic chemotherapy. Radiation therapy is administered for residual tumor or if nodal disease is present.

**Outcomes**

In general, children with Stage I testicular tumors have a 3-year disease-free survival rate near 85%. Overall survival form yolk sac tumors is around 70-90%. Most

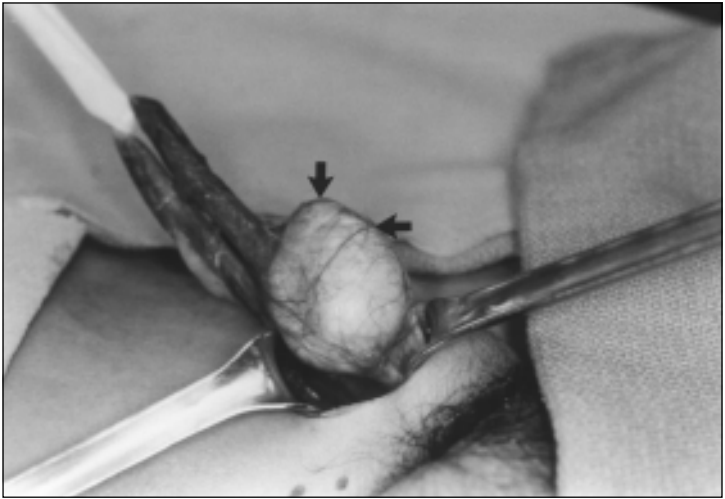


Fig. 43.1. An example of the rather rare testicular tumors of childhood. This small, ovoid tumor in a child with marked virilization proved to be a Leydig cell tumor.

metastasis and recurrences develop within 2 years of initial treatment. The overall 2-year survival of children with paratesticular rhabdomyosarcoma is approximately 75%.

### *Selected Readings*

1. La Quaglia MP. Genitourinary tract cancer in childhood. *Semin Ped Surg* 1996; 5(1):49-65.
2. Raffensperger JG. Tumors of the testicle. In: Raffensperger JG ed. *Swenson's Pediatric Surgery*, 5th Edition. Norwalk: Appleton & Lange 1990; 397-399.

# Gastrointestinal Tumors

*Ambrosio Hernandez and Dai H. Chung*

Gastrointestinal (GI) tract tumors are rare in children; the majority of pediatric GI tumors are usually lymphatic or stromal in origin. Pediatric GI tumors are found throughout the GI tract and consist of various histologic subtypes, but the predominant type is non-Hodgkin's lymphoma of the distal small bowel, cecum, and appendix. Colorectal cancer is extremely rare in children; but it is the distant second most common malignancy of the GI tract.

## Esophagus

Extrinsic compression of the esophagus by other lesions can occasionally mimic tumor-like findings, but malignant tumors of the esophagus in children are extremely rare. Patients with long-standing pathologic gastroesophageal reflux (GER) may be at risk for the development of glandular metaplasia of the distal esophagus, known as Barrett's esophagus. Identification and treatment of Barrett's esophagus have been reported in fewer than 200 pediatric patients. However, Barrett's esophagus in children is suspected to be more common than previously reported, and its prevalence may increase secondary to an increasing number of children with GER. Barrett's esophagus is at risk for developing dysplasia and subsequent adenocarcinoma of the esophagus. Antireflux procedures control reflux symptoms, but long-term surveillance is needed to detect cases of dysplasia or esophageal carcinoma before transmural infiltration occurs.

Smooth muscles make up the predominant tissue of the esophagus. Benign and malignant smooth muscle tumors (leiomyoma and leiomyosarcoma) are found in less than 5% of all esophageal tumors in children. These tumors usually present as multiple or diffuse lesions and are frequent in syndromic patients. The presenting symptoms are those of esophageal obstruction: dysphasia, emesis of undigested food, and chest pain.

Contrast esophagram identifies these tumors, and esophagoscopy reveals a mucosa-covered constrictive mass, suggestive of stricture. Surgical resection for treatment may require extensive dissection due to the diffuse nature of these tumors, and large esophageal resections sometimes require esophageal substitution.

## Stomach

Gastric teratomas represent less than 1% of all childhood teratomas. They are large benign tumors that usually present early in life (first 3 months), frequently

along the greater curvature of the stomach in male infants. Malignant gastric teratoma has not been reported. Plain abdominal radiographs often demonstrate calcification within the tumor, and ultrasound or computed tomography can further clarify the characteristic features of teratomas which are comprised of tissues derived from multiple germ cell layers. Common presenting symptoms include abdominal mass, distention, emesis, hematemesis or lethargy. Needle biopsy for diagnosis is not accurate or necessary. Treatment is excision of the tumor and reconstruction of the stomach. Patients undergoing partial or total gastrectomy must be carefully followed for potential complications (i.e., pernicious anemia).

### Small Intestine

The distal small bowel is a common site for gastrointestinal non-Hodgkin's lymphoma in children. This type of tumor is more common in males who frequently present with symptoms of abdominal mass and intermittent crampy abdominal pain. These symptoms occasionally mislead clinicians to proceed with an appendectomy only to encounter a large terminal ileal mass at the time of operation. Non-Hodgkin's lymphomas can also present with intestinal obstruction, perforation, or hemorrhage.

Treatment options for GI lymphomas include chemotherapy, radiation therapy and surgical resection. The role of tumor debulking or complete surgical resection for GI lymphoma is controversial, since data are inconsistent when comparing the various modalities of treatment. However, those patients who present with intestinal obstruction, perforation, or hemorrhage are probably best treated by resection. The mean survival rate for stage II patients is 80% at 4.5 years of follow-up.

### Appendix

Carcinoid tumors in the GI tract are most commonly found in the appendix. Most tumors are asymptomatic and are discovered incidentally as part of the appendectomy specimen. About half of the patients may present with acute symptoms suggestive of acute appendicitis. These tumors are extremely rare in very young children (< 4 years of age) due to the lack of enterochromaffin cells within the intestinal tract in this age group. The incidence in children between 10 and 15 years of age is 0.4 per 100,000 per year in boys and is twice as common in girls.

Approximately 60% of carcinoid tumors are confined to the bowel at the time of diagnosis. All carcinoid tumors are potentially malignant; however, their tendency toward metastasis depends upon the site of origin. Appendiceal carcinoids are almost never cancerous, whereas 70% of ileal and cecal carcinoids are metastatic.

The carcinoid syndrome, which consists of symptoms of flushing, diarrhea, or bronchial constriction, occurs in 15-25% of patients who have hepatic or more distant metastasis. These clinical manifestations are the result of various substances (VIP, histamine, serotonin, bradykinin, prostaglandins) secreted by the tumor. The diagnosis is confirmed by identifying elevated urine levels of 5-hydroxyindoleacetic acid (5-HIAA), the by-product of serotonin.

Appendectomy is the treatment of choice for appendiceal carcinoid. In the small bowel and stomach, carcinoid tumors tend to be multicentric and require wide resections to include regional lymph nodes. Octreotide, a long-acting somatostatin analog, has been effective in controlling clinical symptoms.

## Large Intestine

The majority of colonic polypoid lesions are benign and occur either spontaneously or in association with inherited polypoid diseases. Several polyposis syndromes are described in children: juvenile polyposis, Cronkhite-Canada syndrome, Peutz-Jeghers syndrome, and familial adenomatous polyposis coli (Gardner's syndrome, and Turcot's syndrome).

Juvenile polyps are common benign polyps that are usually located within 10 cm of the anus. They frequently present as painless rectal bleeding or as prolapsed masses. These smooth round masses are hamartomas and have no malignant potential. In asymptomatic patients, they may be observed, but larger (> 1cm) or symptomatic polyps are removed endoscopically.

Juvenile polyposis syndrome refers to patients with multiple juvenile polyps that are distributed throughout the GI tract. Symptoms include chronic bleeding and hypoproteinemia. These polyps are considered premalignant by some because there may be a family history of adenomatous polyposis and adenocarcinoma of the colon. The incidence of cancer is 6%. Treatment options include endoscopic polyp removal or surgical resection. Cronkhite-Canada syndrome represents juvenile polyposis combined with skin hyperpigmentation and alopecia. These juvenile polyps are at risk for malignant degeneration and should be monitored closely. Surgical resection is considered for the segment of intestine with a high density of polyps.

Peutz-Jeghers syndrome is associated with hamartomatous or adenomatous GI polyps and altered pigmentation of the mouth and skin. These polyps are often large and pedunculate, and the incidence of colon cancer is 2-3%. Asymptomatic small polyps are simply observed. Endoscopic polypectomy is the treatment of choice for symptomatic polyps, and occasionally, laparotomy with open polypectomy or bowel resection for extensive polyps may be required.

Familial adenomatous polyposis coli is an autosomal dominant polyposis syndrome in which hundreds of adenomatous polyps are found throughout the colon. The median age for patient presentation is 16 years, and colorectal cancers appear at around 36 years of age. Gardner's syndrome combines colonic polyps with extracolonic soft tissue tumors, and Turcot's syndrome is associated with brain tumors. A positive family history mandates diagnostic colonoscopy no later than early in the second decade. Common symptoms are bloody diarrhea, malnutrition, and anemia. Patients require total colectomy because of the potential for malignancy. Traditionally, surgical therapy is total colectomy with ileoproctostomy or abdominoperineal resection with permanent ileostomy. Alternatively, total colectomy with rectal mucosectomy and ileoanal pull-through (J- or S-ileal pouch) eliminates the risk for malignancy and provides a chance for continence without permanent ileostomy.

Patients with inflammatory bowel disease are at greater risk for developing colon carcinoma. The overall rate of carcinoma in ulcerative colitis patients is 2-5%. These patients are 20 times more likely to develop cancer than the general population. After the first 10 years with ulcerative colitis, the chance of cancer development increases by 1% per year. Cancers in this patient population are also very aggressive and infiltrative. The patients who have had the disease for a minimum of 7 years should undergo surveillance endoscopy with multiple random biopsies at least every other year. Any evidence of mucosal dysplasia or severe clinical symptoms should

prompt patients to undergo proctocolectomy. The surgical options are similar to those discussed for familial adenomatous polyposis coli.

In addition to polyposis syndrome and inflammatory bowel disease, there are several other predisposing factors for the development of the colon cancer: a diet high in fat and cholesterol and low in fiber, exposure to environmental chemicals, radiation therapy, and chronic irritation from infection or ureterosigmoidostomy. Colorectal carcinoma in children is sporadic in 75% of cases, and usually occurs in the second decade of life. Common presenting symptoms include abdominal pain, nausea, vomiting and change in bowel habits. Physical findings most commonly seen are abdominal mass, distention, tenderness, rectal bleeding and weight loss. Patients frequently present with an intestinal obstruction or an acute abdomen. If plain radiographs demonstrate a mass lesion in the colon, a contrast enema can identify the point of obstruction. Endoscopy allows tissue biopsy and confirmation of diagnosis. Children with colorectal carcinoma have relatively evenly distributed lesions throughout the colon, in contrast to adults. More than 80% of the tumors are Duke's stage C or D at the time of diagnosis in children, and a frequent delay in diagnosis in children may contribute to this finding. Additionally, an aggressive mucinous type of adenocarcinoma is found in more than one half of the children with colorectal tumors. The combination of the advanced stage of disease at the time of diagnosis and the increased frequency of a mucinous subtype contribute to the poor prognosis in children.

The primary treatment for colon cancer in children is wide surgical resection to include the involved mesentery along with the lymphatic drainage area. Only about 50% of pediatric patients can have resection for cure. The ovaries and the omentum are common sites of metastasis. There are no specific adjuvant therapy protocols available for these children, but most patients will receive chemotherapy. Radiation therapy is used selectively. The overall cure and survival rates of children with colon carcinoma are poor; less than 5% of patients survive 5 years.

### *Selected Readings*

1. Ford EG. Gastrointestinal tumors. In: Andrassy RJ ed. *Pediatric Surgical Oncology*. Philadelphia: W.B. Saunders 1998.
2. Skinner MA, Plumley DA, Grosfeld JL et al. Gastrointestinal tumors in children. *Ann Surg Oncol* 1994; 1(4):283-289.
3. Bethel CA, Bhattacharyya N, Hutchinson C et al. Alimentary tract malignancies in children. *J Pediatr Surg* 1997; 32(7):1004-1009.
4. LaQuaglia MP, Heller G, Filippa DA et al. Prognostic factors and outcome in patients 21 years and under with colorectal carcinoma. *J Pediatr Surg* 1992; 27(8):1085-1090.

# Mediastinal Masses

*Vicky L. Chappell and Dai H. Chung*

The classic anatomic description divides the mediastinum, represented by the substernal central thoracic space bounded laterally by the parietal pleura, into four compartments: superior, anterior, middle and posterior. The superior mediastinum lies between the thoracic inlet superiorly and the level of the fourth thoracic vertebrae inferiorly, and contains the thymus, lymphatics and vascular structures. The anterior mediastinum is the space below the superior compartment, bounded by the pericardium and diaphragm. The middle mediastinum contains the pericardium, heart, origins of the great vessels, trachea, main-stem bronchi and lymphatics. The posterior mediastinum is bounded by the great vessels anteriorly and the vertebral bodies posteriorly. The normal structures in this space include the esophagus, sympathetic ganglia, thoracic duct, vessels and lymphatics. Understanding of the anatomical subdivisions of the mediastinum and the relative frequency of specific pathology in these subdivisions aids in the differential diagnosis (Table 45.1).

## **Etiology and Embryology**

In addition to classification by location, mediastinal masses can also be categorized as developmental, neoplastic, or inflammatory. It is presumed that incomplete separation and tubulization of the esophagus and trachea after the proliferative phase, which normally occurs by the fifth week of gestation, results in foregut duplication. Additionally, these duplication cysts can communicate with the spinal canal, and are referred to as neuroenteric cysts. The thymus develops as paired primordium from the ventral third pharyngeal pouch and descends to an area anterior to the aortic arch during the seventh week of gestation. Incomplete descent or obliteration of its tract may result in a cystic or ectopic thymus in the neck. In the middle mediastinum, bronchogenic cysts develop from abnormal budding of the tracheal diverticulum or ventral portion of the foregut. Pericardial cysts occur from the failure of disconnected lacunae in the mesenchyme to coalesce to form the pericardial sac.

The most common neoplasm of the anterior mediastinum in children is lymphoma, accounting for up to 45% of pediatric mediastinal masses. Germ cell tumors (25%), mesenchymal tumors (15%), and thymic tumors (17%) comprise the remainder. Most of these tumors are malignant. Neurogenic lesions, which comprise approximately 20% of mediastinal tumors, are usually located in the posterior mediastinum.

**Table 45.1. Mediastinal masses in the pediatric population**

Compartments	Pathology	Incidence (%)
Superior & Anterior	Lymphomas Non-Hodgkin's Hodgkin's Germ cell tumors Teratoma Seminoma Thymic lesions Hyperplasia Thymic cyst Thymoma Cystic Hygroma	54
Middle	Lymphomas Bronchogenic cyst Granuloma Pericardial cyst Hamartoma	26
Posterior	Neurogenic Neuroblastoma Ganglioneuroblastoma Ganglioneuroma Neurofibroma Enteric (Duplication) Cyst	20

Acute infection of the mediastinum is most often seen following esophageal perforation, cardiac operations, or penetrating chest trauma. Many developmental conditions of the mediastinum (i.e., thymic cysts, enteric cysts, bronchogenic cysts, and cystic hygroma) are at increased risk for acquired infection.

### Clinical Presentation

Most mediastinal masses are asymptomatic, often discovered incidentally on chest radiographs taken for other indications. However, clinical symptoms are frequently the result of mass effects on normal structures within a particular compartment. Large masses in the anterior and middle mediastinum are particularly significant for their potential influence on respiratory tract symptoms, including airway obstruction. Symptoms may range from noisy, stridorous breathing in infants to cough, chest pain, dyspnea, and orthopnea in older children. Cardiac compression may result in cyanosis, syncope, and dysrhythmias. Great vessel compression can lead to superior vena cava syndrome, characterized by venous engorgement along with head and neck swelling. By contrast, posterior mediastinal masses can be quite large and yet asymptomatic. However, posterior mediastinal masses, especially those that enter neural foramina, can cause symptoms of spinal cord compression.

Certain pathology presents with specific symptoms. Hodgkin's lymphomas may have concomitant cervical or supraclavicular nodes as well as fever, night sweats and



weight loss ('B' symptoms) in one-third of patients. Neuroblastoma in the upper mediastinum involving the stellate ganglion produces Horner's syndrome, characterized by ptosis, miosis, and anhidrosis. Although rare, a pediatric patient with thymic neoplasia may present with myasthenia gravis or hypoplastic anemia.

## Diagnosis

Two-view chest radiographs often confirm the presence of mediastinal masses. Ultrasound study can differentiate the cystic nature of the mass, but contrast-enhanced computed tomography (CT) provides far more information about the mass and its relationship to the surrounding mediastinal structures. Magnetic resonance imaging (MRI) is helpful to define spinal involvement or vascular lesions. However, the sedation required for adequate MRI study in pediatric patients may compromise the airway in patients with large anterior mediastinal masses. An esophagogram or echocardiogram also provides additional information to further define mediastinal masses.

Ultrasound or CT-guided percutaneous needle biopsy of solid mediastinal mass can be performed to establish tissue diagnosis. Complications such as pneumothorax, bleeding, perforation, or tumor seeding occur infrequently. Tissue diagnosis may also be obtained from sites alternative to the tumor itself, such as lymph node or bone marrow. Incisional or excisional biopsies of the tumor are performed using thoracoscopy, mediastinoscopy or mini-thoracotomy. However, the goal of the preoperative work-up is to help define the optimal surgical approach for resection, and open direct tissue biopsy of masses is rarely indicated in pediatric patients.

Tumor markers such as serum  $\beta$ -human chorionic gonadotropin ( $\beta$ -HCG) or  $\alpha$ -fetoprotein may help in the diagnosis and follow-up of malignant mediastinal tumors. Since more than 90% of patients with neuroblastoma produce high levels of catecholamines, quantification of the corresponding by-products (vanillylmandelic acid, homovanillic acid) in urine over a 24-hour period can confirm the diagnosis.

## Anterior and Superior Mediastinum

The common tumors in order of decreasing frequency are lymphomas, teratomas, germ cell tumors, lymphangioma (cystic hygromas), and thymic tumors. Malignant lymphomas present most frequently in older children, and sometimes, diagnosis can be sought from nonmediastinal areas such as bone marrow and nodal tissues. Among Non-Hodgkin lymphomas, the lymphoblastic subtype is most likely to present in the mediastinum. This is a diffuse, fast-growing tumor of T cell and pre-B cell origin.

Teratomas are the second most common tumors of the anterior mediastinum. They are derived from multiple germ cell layers and can have both cystic and solid components. Teratomas frequently have calcifications, and only 25% of teratomas are malignant in pediatric patients.  $\beta$ -HCG and  $\alpha$ -fetoprotein can also help to differentiate various germ cell tumors and are especially important postoperatively as an early marker of recurrence. Seminomatous germ cell tumors are responsive to radiation therapy and should be distinguished from other types.

Lymphangiomas in the mediastinum frequently present as a mediastinal extension of a cervical lesion. They demonstrate extensive endothelial-lined buds within tissue planes and complete resection is required to avoid recurrence. Large

lymphangiomas may be treated with sclerosing injections (i.e., OK-432, a monoclonal antibody produced by *Streptococcus pyogenes*) but the value and efficacy of this therapy is not established.

Thymic cysts are usually asymptomatic but can become infected. Large lesions produce symptoms due to mass effect. Thymolipoma is benign, but along with thymic cysts, resection is indicated for proper diagnosis and prevention of complications. Thymomas originating in the thymic epithelium are usually aggressive, but account for less than 1% of mediastinal tumors. Thymomas associated with myasthenia gravis may produce autoantibodies to acetylcholine receptors which leads to progressive muscle weakness. Resection produces some improvement in symptoms for 30-50% of these children.

### **Middle Mediastinum**

Pericardial cysts are benign, fluid-containing cysts lined with mesothelium. They are usually asymptomatic and CT imaging can provide accurate diagnosis. When the diagnosis is uncertain or the cysts become too large, thoracotomy or thoracoscopic resection or evacuation of the cysts should be performed. Pericardial effusion may, on rare occasions, represent underlying pathology such as cardiac hemangioma or rhabdomyoma. Bronchogenic cysts develop from abnormal budding of the tracheal diverticulum or ventral portion of the foregut. These mucus filled cysts are lined with bronchial epithelium and are frequently located at paraesophageal, paratracheal, or perihilar regions. Excision is performed electively to avoid the complications of infection, hemorrhage, or problems due to mass effects. Complete resection via thoracotomy or video-assisted thoracoscopy is the preferred treatment of bronchogenic cysts; recurrence and malignancy are extremely rare.

### **Posterior Mediastinum**

The posterior mediastinum is the common site of benign and malignant neurogenic tumors. Sixty percent are malignant, most often neuroblastoma or ganglioneuroblastoma, and thirty percent are benign tumors such as ganglioneuroma, neurofibroma or schwannoma. The remaining 10% represent miscellaneous mesenchymal tumors or granulomas. Enteric duplication cysts may occur in this location, are lined by esophageal or gastric epithelium, and occasionally communicate with a viscus lumen. Most are asymptomatic and benign. Treatment is usually complete resection, but stripping of the mucosal lining of a foregut duplication may be adequate for long tubular duplications. Neuroenteric cysts are foregut duplications that also have connections to the spinal canal. They often present as an intraspinal mass. MRI or CT with myelogram should be considered when a posterior mediastinal mass is associated with vertebral anomalies. Total excision is recommended with simultaneous laminectomy as necessary.

### **Treatment**

For cysts, regardless of symptoms, removal should be seriously considered to prevent future complications of infection, bleeding or compression on adjacent normal structures. For similar reasons, benign mediastinal tumors should also be resected. Ganglioneuromas and neurofibromas often remain encapsulated and can be easily removed. The role of surgery regarding malignant tumors spans the spectrum from

diagnostic procedures to complete resection or debulking of the tumor mass to relieve complications. Patients with Non-Hodgkin's lymphoma and bulky anterior mediastinal involvement may require surgical intervention for respiratory symptoms, pleural effusion or superior vena cava syndrome. Neuroblastomas, when found in early stages (I or II), are considered for complete primary resection. Seminomatous tumors are treated with chemotherapy and radiation, while germ cell tumors of other origin are treated with resection or debulking followed by chemotherapy.

In general, the surgical approach to mediastinal masses depends on location, size and pathology. Thoracoscopy can be useful for resection or biopsy in approachable lesions, such as foregut duplications (enteric cysts and duplications, bronchogenic cysts, neurenteric cysts) and simple solid masses. Large anterior mediastinal masses are best approached through a median sternotomy.

## Outcome

Prognosis depends on the underlying pathology. Patients with benign cysts and tumors have excellent outcomes with complete recovery. Recent protocols for Hodgkin's disease have improved the overall 5-year survival, which is now approaching 90%. Although, the youngest patients have the best prognosis, overall prognosis for neuroblastoma remains poor.

## Selected Readings

1. Philippart Al, Farmer DL. Benign mediastinal cysts and tumors. In: Oneill JA, Jr., Rowe MI, Grosfeld JL et al, eds. *Pediatric Surgery*, ed 5, St. Louis: Mosby 1998.
2. Grosfeld JL, Skinner MA, Rescorla FJ et al. Mediastinal tumors in children: Experience with 196 cases. *Ann Surg Oncol* 1994; 1(2):121-127.
3. Saenz NC, Schnitzer JJ, Erakis AE et al. Posterior mediastinal masses. *J Pediatr Surg* 1993; 28(2):172-176.
4. Kern JA, Daniel TM, Tribble CG et al. Thorascopic diagnosis and treatment of mediastinal masses. *Ann Thorac Surg* 1993; 56(1):92-96.
5. Robie DK, Gursoy MH, Pokorny WJ. Mediastinal tumors-airway obstruction and management. *Semin Pediatr Surg* 1994; 3(4):259-266.

## Breast Lesions

*Vinh T. Lam and Daniel A. Bambini*

Breast lesions in children and adolescents are not uncommon. This Chapter reviews normal breast development and describes several of the abnormal breast conditions that may be encountered in pediatric patients.

### Breast Development

The mammary glands are a modified and specialized type of sweat gland. Breast development begins during the sixth week of gestation as a solid down growth of epidermis into the underlying chest wall mesenchyme. In the embryo, male and female breast development is identical. At birth the rudimentary mammary glands of newborn males and females are similar, and no significant changes occur until the pubertal period.

The breast of the newborn has characteristically poorly-formed, inverted nipples. Shortly after birth, the nipples appear more raised above the underlying mammary pits due to proliferation of the surrounding connective tissue of the areola. Neonates frequently have secretion of colostrum-like fluid (called 'witches' milk') from the nipples in response to late gestational maternal hormones.

The average age of female thelarche is approximately 11 years of age (range 8-15 years). Breast growth and development is stimulated by the production of estrogen and progesterone at the onset of puberty. Estrogen is the primary hormone that produces ductal and stromal growth within the breast tissue. Progesterone initiates alveolar budding, stimulates lobular growth, and contributes to secretory development of the breast. Premature thelarche (Fig. 46.1) begins before 8 years of age and occurs without other evidence of precocious puberty. Premature thelarche presents as enlargement of one or both breasts and is a benign process. Biopsy is absolutely contraindicated and may result in a small, underdeveloped breast. Precocious puberty implies premature breast development in association with the presence of other secondary sex characteristics (pubertal hair, etc.) and generally indicates the need to search for tumor producing estrogens.

### Diagnostic Approaches to Breast Lesions

Evaluation of breast-related symptoms in children begins with a thorough history and physical examination. In adolescents, details regarding menstrual history (onset, etc.) and the relation of symptoms to the menstrual cycle are obtained. A family history of similar problems or other breast disease is investigated.

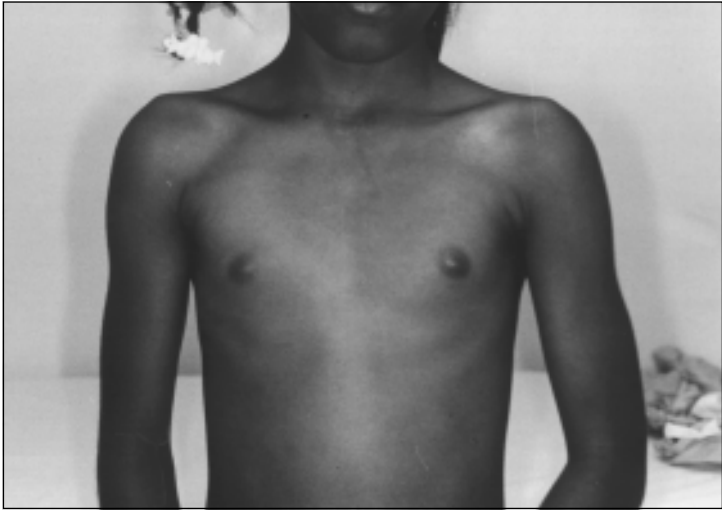

Fig. 46.1. A 7-year-old female with premature thelarche presenting as benign enlargement of the left breast tissue with no other signs of puberty.

Diagnostic tests are chosen relative to the presenting clinical features and include breast ultrasound, fine-needle aspiration, and very rarely open biopsy. Most of these diagnostic tests are reserved for older children and adolescents presenting with a breast mass. Ultrasound is particularly useful to distinguish cystic from solid lesions. Mammography has practically no use in pediatric or young adult patients because the dense fibrous tissue in these patients often precludes visualization of mammographic abnormalities (i.e., calcifications).

### **Congenital Breast Anomalies**

Approximately 1-2% of females have abnormalities of breast development presenting as extra breast tissue including polymastia (extra breast) and polythelia (extra nipple). Supernumerary nipples are also relatively common in males. An extra breast or nipple usually develops along the nipple line just inferior to an otherwise normal breast. They can rarely appear in the axillary or abdominal wall regions. Amastia or athelia are rarer occurrences and often accompany other chest wall anomalies. For example, Poland's syndrome includes amastia, aplasia of the pectoral muscles, rib deformities and upper extremity defects.

### **Gynecomastia**

Gynecomastia refers to benign enlargement of the male breast and is due to proliferation of the glandular portion of the breast. However, this condition can be confused with general obesity or pectoral muscle hypertrophy. Gynecomastia in boys is most often due to pubertal changes (25%) but is idiopathic in just as many (25%). Gynecomastia is also caused by drugs (10-20%), cirrhosis or malnutrition

(8%), primary hypogonadism (8%), testicular tumors (3%), secondary hypogonadism (2%), hyperthyroidism (1.5%), and renal disease (1%). Management of pubertal gynecomastia in adolescent boys includes careful history (i.e., drugs, kidney disease, liver disease) and a thorough exam to include a careful testicular examination. If the exam and history are negative, reassurance and periodic follow-up are all that is needed. For those who absolutely refuse to outwait the enlargement (regression in 6-24 months), simple mastectomy and liposuction produce satisfactory immediate cosmetic relief.

### **Breast Asymmetry**

Breast asymmetry is common in pediatric patients, affecting as much as 25% of the population. Unilateral hypomastia is most often due to inadequate end-organ response to hormonal stimulation. Bilateral hypomastia may indicate an endocrine or genetic abnormality that requires additional investigation (i.e., karyotyping, etc). Generally, asymmetry is mild and transient. Seldom is cosmetic reconstruction required.

### **Nipple Discharge**

Serous or bloody nipple discharge in prepubertal patients is sometimes associated with infantile mammary duct ectasia, intraductal papilloma or cyst, or chronic cystic mastitis. Galactorrhea, when not associated with pregnancy or nursing, is abnormal and may be neurogenic, caused by hypothalamic or pituitary dysfunction or other endocrine abnormalities. Prolactinomas are exceptionally rare in children. Some drugs can cause galactorrhea, but many cases will remain idiopathic. These forms of drainage require investigation, usually resolve spontaneously, and rarely require surgery.

An intraductal papilloma most often presents as a subareolar lesion producing sanguinous or serosanguinous nipple discharge. The differential diagnosis includes fibroadenoma, cystosarcoma phylloides, papillary carcinoma, and mammary duct ectasia. Ductography can occasionally help localize these lesions. Treatment is surgical excision of the entire involved duct. Most young women with this lesion are postpubertal and have sufficient breast development to allow surgery without fear of damaging an underdeveloped breast bud. Isolated papillomas confer no increased risk for later breast malignancy, but diffuse juvenile papillomatosis is associated with a greater risk of breast cancer.

### **Fibroadenoma**

Fibroadenoma is the most common breast lesion in adolescent females. These lesions are benign and occur as encapsulated, nontender mobile masses. The morphology of fibroadenomas is quite variable. Most can be observed safely, but many are removed in patients because of progressive enlargement, family history of malignant breast disease, or because a malignant lesion can not be absolutely excluded. In general, fibroadenomas are not considered a risk for future breast malignancy, but patients with complex fibroadenomas, family history of complex fibroadenomas, or associated proliferative disease are at increased risk (20% will develop breast cancer within 25 years of diagnosis).

Giant (juvenile) fibroadenoma are greater than 5 cm in size and frequently double in size within 3-6 months. Most frequently teens with this lesion present with a rapidly enlarging, encapsulated breast mass. Treatment is surgical excision. Occasionally reduction mammoplasty may be required to achieve acceptable cosmetic results.

### **Breast Infection**

Neonatal breast hyperplasia occasionally is complicated by infection, perhaps initiated by over-manipulation. In neonates and prepubertal children, mastitis usually involves the entire breast complex and is caused most often by gram positive bacteria (i.e., staphylococcus, streptococcus, etc). Systemic antibiotics are required for the treatment of most breast infections in children. Incision and drainage may be necessary in cases developing breast abscess. This is best performed through a circumareolar incision whenever possible.

### **Cystosarcoma Phylloides**

Originally believed to arise from a pre-existing adenoma, this lesion is now known to occur de novo from breast parenchyma as a slow-growing painless mass. Approximately 20% of adolescents with this lesion will present with axillary adenopathy. Histologically, there are three types:

1. benign,
2. intermediate,
3. malignant.

Size has no relation to whether malignancy is present or not. In malignant lesions, the lung is the most common site of metastasis. Treatment is total excision of the tumor mass. Initial radical resection (i.e., mastectomy) is not warranted unless evidence of metastasis is present. Mastectomy is indicated for malignant lesions, very large lesions (cosmetic consideration), and in cases of local recurrence of borderline or malignant lesions.

### **Breast Cancer**

Primary breast cancer is very rare in childhood. It accounts for less than 1% of all childhood cancers and less than 0.1% of all reported breast cancers. Most cases described are carcinomas, but rhabdomyosarcomas, sarcomas, and non-Hodgkin's lymphoma have occurred as primary malignancies in the breast of children. In premenarchal children, treatment is by wide local excision. In postmenarchal children, breast cancer should be managed as it is in adult patients. A full discussion of breast cancer treatment is beyond the limits of this text.

The breasts of pediatric oncology patients should be examined regularly for signs of metastatic disease. Metastatic leukemia and rhabdomyosarcoma present in the breast. Complete metastatic work-up is indicated in addition to incisional/excisional biopsy of the mass. Fine needle aspiration can frequently successfully make the diagnosis avoiding open biopsy. Secondary malignancy developing in patients treated for other malignancies, especially children with previous Hodgkin's disease who received upper mantle radiation, is increasingly common. Radiation-induced breast sarcoma has also been reported after treatment of Wilms' tumor, and adrenal carcinoma.

### *Selected Readings*

1. Ciftci AO, Tanyel FC, Buyukpamukcu N et al. Female breast masses during childhood: a 25-year experience. *Euro J Pediatr Surg* 1998; 8:67-70.
2. Kaste SC, Hudson MM, Jones DJ et al. Breast masses in women treated for childhood cancer: incidence and screening guidelines. *Cancer* 1998; 82:784-92.
3. Pacinda SJ, Ramzy J. Fine-needle aspiration of breast masses. A review of its role in diagnosis and management in adolescent patients. *J Adol Health* 1998; 23:3-6.
4. Sher ES, Migeon CJ, Berkovitz GD. Evaluation of boys with marked breast development at puberty. *Clin Pediatr* 1998; 37:367-71.
5. West KW, Rescorla FJ, Scherer LR 3<sup>rd</sup> et al. Diagnosis and treatment of symptomatic breast masses in the pediatric population. *J Pediatr Surg* 1995; 30:182-7.



# Hodgkin's Lymphoma

*Lars Göran Friberg and Daniel A. Bambini*

Hodgkin's lymphoma is a malignant disease of the lymphatic system characterized by the presence of Reed-Sternberg cells in the lymphomatous tissue. The origin of the Reed-Sternberg cells is unknown, but these cells are speculated to arise from dendritic cells within the lymph node that function as antigen presenting cells.

## Incidence

Hodgkin's disease accounts for about 5% of childhood malignancies. It is rare before the age of five years and has its peak incidence in the third decade of life. It is more common in boys, but after the age of 12-13 years the sex ratio is shifted. It may be slightly more common in black American children; geographic and socio-economic forces may affect the incidence as well. The incidence in children is increasing and currently is about 1.6 per 100,000 children per year.

## Etiology

The etiology of Hodgkin's disease is unknown. It is likely associated with the Epstein-Barr virus, but a causal relationship has not been established.

## Clinical Presentation

The most common childhood presentation of Hodgkin's lymphoma is painless cervical or supraclavicular adenopathy. The nodes are firm, generally painless, and often matted. Mediastinal lymphadenopathy is present in 50% of the patients at the time the cervical findings are noticed. Greater than 85% of children with Hodgkin's disease will have disease within the chest at the time of presentation. The presence of facial swelling or distended cervical veins alerts the physician to mediastinal disease and the possibility of airway obstruction. Axillary and inguinal lymph nodes can be involved but primary axillary or inguinal tumors are uncommon.

Systemic symptoms occur in approximately one third of children at the time of diagnosis and indicate advanced disease. Systemic symptoms include:

1. recent (< 6 months) loss of greater than 10% body weight,
2. drenching night sweats, and
3. fever exceeding 38°C. Pruritis is no longer considered an important indicator of extensive disease. Splenomegaly and/or hepatomegaly also indicate more advanced disease.

Respiratory distress due to mediastinal lymph node enlargement is much less common in children with Hodgkin's disease than in children with Non-Hodgkin's lymphoma (NHL) but should always be considered prior to general anesthesia and biopsy. The differential diagnosis includes systemic infections, infectious lymphadenopathy, NHL, Langerhan's histiocytosis, mononucleosis, and other causes of generalized or localized lymphadenopathy.

## Diagnosis

Children suspected of having Hodgkin's disease receive a careful history and physical examination. Posteroanterior and lateral chest x-rays and computed tomography (CT) of the neck, chest and abdomen are routinely obtained. Gallium scan and magnetic resonance imaging also provide accurate information regarding the extent of disease and may be necessary to fully stage a patient. Bone marrow aspiration and biopsy is also indicated.

Diagnosis depends on histologic evaluation and identification of Reed-Sternberg cells, so biopsy is mandatory. If possible, several lymph nodes are evaluated histologically. In the absence of palpable peripheral lymph nodes in a child with mediastinal disease, mediastinoscopy or thoracotomy are necessary to obtain tissue for diagnosis.

## Classification

The Rye classification includes four histopathologic subtypes of Hodgkin's disease:

1. lymphocyte predominant,
2. mixed cellularity,
3. nodular sclerosing, and
4. lymphocyte depleted.

The relative ratio of normal lymphocytes to malignant (Reed-Sternberg) cells decreases progressively between lymphocyte predominant and lymphocyte depleted subtypes. Overall, the most frequent subtype in children (< 16 years old) is nodular sclerosing (> 65%). However, younger patients (< 10 years old) have an increased relative proportion of the lymphocyte predominant and mixed cellularity subtypes.

## Staging

Clinical staging is dependent on:

1. involvement of single or multiple lymph node regions,
2. involvement of single or multiple extra lymphatic organs, and
3. disease present on one or both sides of the diaphragm.

The stage is determined by a combination of clinical parameters including:

1. history,
2. physical exam,
3. x-rays,
4. CT scans of chest, abdomen and pelvis,
5. gallium scan, and
6. laboratory studies.

The Ann Arbor staging classification is the clinical staging system most commonly used (Table 47.1). The clinical stage (CS) is amended to pathologic stage (PS) once the histologic results of the biopsy and staging laparotomy (if necessary)

**Table 47.1. Ann Arbor staging classification of Hodgkin's lymphoma**

Stage	Description
I	Involvement of a single lymph node region (I) OR Involvement of a single extralymphatic site or organ (I <sub>E</sub> )
II	Involvement of 2 or more lymph node regions on same side of diaphragm (II) OR Localized involvement of an extralymphatic organ or site and lymph node involvement on the same side of the diaphragm (II <sub>E</sub> )
III	Involvement of lymph node regions on both sides of the diaphragm (III) OR Involvement of lymph node regions on both sides of the diaphragm with: 1. Extension to an extralymphatic site (III <sub>E</sub> ) OR 2. Involvement of the spleen (III <sub>S</sub> ) OR 3. Both 1) and 2) above (III <sub>ES</sub> )
IV	Diffuse or disseminated (multifocal) involvement of 1 or more extralymphatic organs or tissues with or without lymph node enlargement OR Isolated extralymphatic organ involvement with distant (nonregional) nodal involvement.
Subclassifications:	A No symptoms B Symptoms of fever, night sweats, and weight loss. E Extranodal involvement * S Splenic involvement + Pathologic confirmed involvement of extranodal site or organ

\* The subclassification E denotes minimal, localized, extralymphatic disease resulting from direct extension from an adjacent lymph node area and can be encompassed by a potentially curative radiation portal.

are known. Absolute pathologic staging requires laparotomy, splenectomy, and biopsies of abdominal lymph nodes, liver, and bone marrow. Historically, staging laparotomy changes the stage in 14-56% of children with Hodgkin's disease. However, staging laparotomy is not now commonly performed and is only considered in unique cases where it may significantly alter therapy (i.e., radiation being considered as only therapy). Subdiaphragmatic involvement is seen in up to 40% of patients with cervical disease.

## Treatment

The treatment of Hodgkin's disease is determined by the stage of disease and where it is located. For older patients with stage I or IIA disease, radiation therapy alone to the involved area and contiguous lymphoid structures is successful. Low stage patients with bulky mediastinal disease are at higher risk for recurrence and therefore receive systemic chemotherapy in addition to mantle radiation. For patients with Stage IIB or higher disease, multi-drug chemotherapy or a combination of chemotherapy and radiation are used. Chemotherapeutic drug regimens include MOPP (mechlorethamine, vincristine, procarbazine, prednisone) and ABVD

(adriamycin, bleomycin, vinblastine, dacarbazine). Combinations of the MOPP and ABVD with lower radiation doses may decrease overall toxicity. Combined chemotherapy and lower dose radiation therapy is effective and achieves local control in over 95% of cases. Although mantle radiation has proven very effective for localized disease, combination therapy is used to control higher stages of disease and has been successful in children with relapse.

## Outcomes

Newer protocols give overall five-year survival in children close to 90%. The youngest patients have the best prognosis. Histologically, the lymphocyte depleted subtype has the worst prognosis, but this is very unusual in children. The lymphocyte predominant subtype has the best prognosis. Stage I patients have relapse free and overall survival rates of 91% and 95%, respectively. Children with IIA disease have a relapse free survival rate of about 80% and an overall survival rate of 92% at 5 years.

There are significant complications of treatment related to both chemotherapy and radiation. The complications of chemotherapy, depending on the specific agents used include myelosuppression, cardiovascular changes, pulmonary problems, gonadal problems, and neurologic impairment. Most cases of testicular azospermia occur in patients that have received six cycles of MOPP and often this problem is irreversible. The use of ABVD diminishes the risk of sterility.

Mantle radiation causes adverse effects such as hypothyroidism, myelosuppression, pericarditis, pneumonitis, nephritis, skeletal hypoplasia, bone osteonecrosis, gonadal dysfunction and growth retardation. Impairment of growth is more common in children less than 13 years of age who have received doses greater than 35Gy to large areas of the body. The risk of thyroid dysfunction in children receiving more than 25Gy to the neck is almost 80%.

Secondary neoplasms (acute nonlymphocytic leukemia, thyroid carcinoma, parathyroid adenoma, soft tissue sarcoma, osteogenic sarcoma, non-Hodgkin's lymphoma, etc.) are probably radiation induced. The incidence of a secondary leukemia in children treated with MOPP is about 5-7% and increases to about 10% if radiation therapy is administered. The peak incidence for leukemia following treatment for Hodgkin's disease occurs at 5 years following therapy. Solid tumors develop in about 4-5% of patients.

## Selected Readings

1. Azizkhan RG, Dudgeon DL, Buck JR et al. Life-threatening airway obstruction as a complication to the management of mediastinal masses in children. *J Pediatr Surg* 1985; 20:816-22.
2. Levanthal BG. Management of stage I-II Hodgkin's disease in children. *J Clin Onc* 1990; 8:1123-24.
3. Oberlin O. Present and future strategies of treatment in childhood Hodgkin's lymphomas. *Ann Onc* 1996; 7(Suppl 4):73-78.
4. Beaty O, Hudson MM, Greenwald C et al. Subsequent malignancies in children and adolescents after treatment for Hodgkin's disease. *J Clin Onc* 13:603-609.
5. Cooper DL, DeVita VT. Hodgkin's disease: Current therapy and controversies. *Adv Onc* 1994; 10:17-24.
6. Whalen T. Hodgkin's and Non-Hodgkin's lymphoma. In: Andrassy RJ ed. *Pediatric Surgical Oncology*. Philadelphia: WB Saunders Company 1998; 267-277.

# Non-Hodgkin's Lymphoma

*Lars Göran Friberg and Daniel A. Bambini*

## Incidence

Lymphomas are the third most common pediatric malignancy. They are divided into non-Hodgkin's lymphoma (NHL) and Hodgkin's lymphoma. NHL is less common than Hodgkin's lymphoma and therefore accounts for less than 5% of pediatric malignancies. Males are affected more than females by a ratio of 3:1.

## Etiology

The etiology of NHL is unknown. However, the link between Epstein-Barr virus (EBV) and endemic forms of Burkitt's lymphoma observed in Africa and New Guinea is well known. EBV deoxyribonucleic acid (DNA) and nuclear antigens have been identified in 95% of African Burkitt's lymphoma tumor cells. A sporadic form of Burkitt's lymphoma occurs in Europe and America. Although histologically similar to the Burkitt's lymphoma of Africa, only 15% have tumors with identifiable EBV DNA. In addition, many cases of Burkitt's lymphoma have a translocation of a segment of the long arm of chromosome 8 containing the *c-myc* protooncogene. The segment is frequently translocated to the long arm of chromosome 14. The *MIC2* gene, a commonly expressed gene in many small-, round-cell tumors of childhood, is expressed in many childhood lymphoblastic lymphomas.

The Epstein-Barr virus is also associated with other large-cell lymphomas found in immunosuppressed patients (HIV, Wiscott-Aldrich syndrome, Bloom syndrome, ataxia telangiectasia, X-linked lymphoproliferative syndrome, and organ transplant recipients on immunosuppression).

## Classification

In children with NHL, more than 90% of tumors belong to three histological subtypes:

1. lymphoblastic lymphoma,
2. small noncleaved cell lymphoma (including Burkitt's and non-Burkitt's lymphomas), and
3. large cell lymphoma (histiocytic). Each of these categories is subdivided on the basis of histology and/or immunophenotype.

Lymphoblastic lymphomas account for 30% of childhood NHL and are mostly tumors of thymocyte (i.e., T-cell) origin. These tumors consist of lymphoblasts that are morphologically identical to acute leukemia T lymphoblasts. Cells from lymphoblastic lymphomas are most often positive for the enzyme terminal

deoxynucleotidyl transferase (TdT) and have a T-cell immunophenotype. Rare tumors are positive for the tumor marker CD10. Chromosomal abnormalities are infrequently identified.

Small noncleaved cell lymphomas (Burkitt's and non-Burkitt's) account for 40-50% of childhood NHL. Small noncleaved cell lymphomas originate from B-cells. Most cells express surface immunoglobulin M (either kappa or lambda light chain) but they do not express terminal deoxynucleotidyl transferase (TdT). Almost all tumors are CD10 positive. Chromosomal translocation (usually t(8;14), sometimes t(8;22) or t(2;8)) are characteristic of these tumors. The translocation places the *c-myc* gene, a cellular proliferation gene, near the immunoglobulin regulatory locus, which often results in inappropriate expression of *c-myc*.

Large cell lymphomas (LCL), formerly histiocytic lymphoma, account for 20-25% of childhood NHL. There are three subtypes based on reactivity to T- or B-cell antibodies: B lineage, T lineage, or indeterminate lineage. B-lineage large cell lymphoma is further divided into large cleaved, large noncleaved, and immunoblastic lymphoma; the distinction is probably not of major clinical significance. B-Cell LCL are often immunotypically similar to small noncleaved lymphomas and chromosomal abnormalities (i.e., t(8;14)) are sometimes present.

T-lineage large cell lymphomas are divided into two groups:

1. CD 30 positive anaplastic LCL, and
2. other T-cell lymphomas.

Over 90% of anaplastic large cell lymphomas are CD 30 positive and the majority are of T-cell immunophenotype. Many CD 30 positive anaplastic LCL have a characteristic translocation (2;5) (p23;q35). LCLs of indeterminate lineage are most often CD 30 positive, usually classified as anaplastic LCLs, and have clinical outcome similar to LCL of T-cell lineage.

### Clinical Presentation

In children, NHL occurs predominantly in the chest and abdomen. Sometimes the disease presents with generalized lymphoid and extranodal involvement. All NHL tumors grow rapidly and have a tendency for widespread systemic dissemination. All lymphatic tissue may be involved including that of lymph nodes, Peyer's patches, the thymus, Waldeyer's ring, pelvic organs, liver, and spleen. Extralymphoid involvement can be seen in the skin, testis, bone and central nervous system (CNS).

Nearly 75% of children with lymphoblastic lymphoma present with a large, bulky, anterior mediastinal mass which may compress the trachea or create superior vena caval obstruction. Presenting symptoms include dyspnea, wheezing, stridor, swelling of the head and neck, and sometimes dysphagia. Pleural effusions (often bilateral) are frequently present. In patients with generalized lymphadenopathy and/or hepatosplenomegaly, bone marrow and CNS involvement should be suspected. Bone marrow involvement may cause diagnostic confusion in determining whether the child has NHL with bone marrow involvement or leukemia. Although somewhat arbitrary, patients with greater than 25% bone marrow blasts are considered to have leukemia. Children with less than 25% bone marrow blasts are considered to have lymphoma.

Small, noncleaved cell lymphoma most often (up to 90%) present in the abdomen as a fast growing tumor. Other sites of involvement include Waldeyer's ring,

testis, nasal sinuses, bone, bone marrow, the central nervous system, peripheral lymph nodes, and skin. However, the African endemic form often appears at the orbit or in the jaw (>70%); the sporadic form almost always presents as abdominal disease. The endemic form has a peak incidence at around seven years of age; the sporadic form affects children from a broader age distribution. More than half of abdominal cases involve the small bowel and probably originate in the Peyer's patches. The presenting symptoms are usually abdominal pain, anorexia, or tenderness. Rarely the presentation is intestinal obstruction caused by intussusception with a lymphoma as a lead point.

Large-cell lymphoma usually occurs at extranodal sites and is frequently widely disseminated at the time of presentation. It seldom involves the gastrointestinal tract. Primary sites include the skin, testis, eye, tonsils, soft tissues and sometimes the mediastinum. The peak incidence of the large-cell lymphoma occurs in puberty.

### Diagnosis

The heterogeneity of this disease makes it essential to perform diagnostic biopsy to identify the histopathology. Immuno-phenotyping and cytogenic studies are essential to establish the diagnosis. Approximately 20% of these children have bone marrow involvement at the time of presentation; therefore, bone marrow biopsy and aspiration are required. Lumbar puncture is used to identify cerebrospinal involvement.

Radiographic imaging (i.e., computed tomography, chest x-ray, etc.) is the principal means to evaluate the extent of the primary tumor. At most institutions, clinical staging relies almost exclusively on the results of computed tomography. Computed tomography of the chest, abdomen, and pelvis are routinely obtained to identify and document the presence of disease above and below the diaphragm. Depending on the site of the primary tumor (i.e., neck, spine, etc) other radiographic tests may be necessary. Although staging laparotomy provides the highest diagnostic accuracy, it is no longer routinely performed in children in most institutions.

### Staging

Although several staging schemes exist, the most widely used staging system is the one used at the St. Jude's Children's Hospital (Table 48.1). This staging system distinguishes children with limited disease (i.e., single mass or locoregional disease) from those with more extensive intra-abdominal or thoracic disease. Children with a localized, nonabdominal, nonmediastinal disease (i.e., Stage I) have an overall better prognosis than children with primary tumors in central nervous system, mediastinum, thymus, epidural and paraspinal locations. The prognosis is unfavorable when disease exists on both sides of the diaphragm or when the disease is disseminated (Stage III/IV).

### Treatment

Treatment of NHL is based upon both histology, immunophenotype, and clinical stage. All children with NHL are considered for entry into a clinical trial. NHL in children is considered to be widely disseminated from the beginning, even when the disease appears localized. Combination chemotherapy is recommended for all patients. Radiation therapy is sometimes added for children with:

**Table 48.1. St. Jude's staging system for childhood non-Hodgkin's lymphoma**

Stage	Description
Stage I	Single tumor or nodal area outside the abdomen or mediastinum
Stage II	Single tumor with regional node involvement Two or more tumors or nodal areas on one side of the diaphragm
Stage III	Primary gastrointestinal tumor (resected) with or without regional node involvement Tumors or lymph node areas on both sides of the diaphragm Any primary intrathoracic disease or extensive intra-abdominal disease
Stage IV	Any paraspinal or epidural tumors Any bone marrow* or CNS involvement regardless of other sites of involvement

1. primary NHL of the bone,
2. central nervous system involvement ( sometimes emergency therapy),
3. testicular involvement,
4. severe mass effect ( i.e., superior vena caval compression or airway obstruction).

Children with localized disease do not benefit from radiation therapy, which, in this setting, only increases toxicity. Typical multiagent chemotherapy includes treatment with doxorubicin, vincristine, cyclophosphamide and prednisone followed by oral 6-mercaptopurine and weekly methotrexate. Children with head and neck tumors receive intrathecal therapy as prophylaxis for CNS disease.

The role of surgery in the initial management of NHL is mostly for incisional biopsy to establish the diagnosis. Complete surgical resection of well-localized tumors, particularly if confined to the bowel, may be beneficial to overall survival and reduces complications such as tumor lysis syndrome or bowel perforation following chemotherapy.

Children with large mediastinal tumors are at significant risk of cardiac or respiratory arrest during general anesthesia. For this reason, the least invasive procedure possible is used to establish the diagnosis of lymphoma. Bone marrow biopsy and aspiration often provides the diagnosis and should be done early. Peripherally involved lymph nodes are biopsied using local anesthetic and light sedation in most instances. Pleural effusions aspirated via thoracentesis also can provide the correct histologic diagnosis. If less invasive measures are not able to make the diagnosis, computed tomography guided core needle biopsy of the mediastinal mass is considered. If necessary, mediastinoscopy, thoracoscopy, or anterior mediastinotomy are the surgical procedures used to establish the diagnosis. If the risk of anesthesia or heavy sedation is too great, preoperative treatment with radiation therapy or steroids is considered. The diagnostic biopsy is obtained as soon as possible, once the risk of general anesthesia is acceptably lowered. Preoperative treatment with steroids and/or radiation therapy may affect the ability to obtain an accurate diagnosis.



## Outcomes

Tumor burden at the time of diagnosis is the most important prognostic factor. Children with Stage I disease have 90-95% long-term survival with multiple drug chemotherapy with or without radiation therapy. Stage II patients have a 75% survival rate. In advanced cases, a multiple drug program offers about 70% relapse-free survival. Patients with refractory disease or relapses are treated by autologous or allogeneic bone marrow transplantation.

A major complication of therapy is tumor lysis syndrome that results from rapid breakdown of malignant cells. Hyperuricemia compromises renal function. Initial overhydration and pretreatment with allopurinol may prevent the adverse effects of rapid tumor cell lysis. Gastrointestinal problems of bleeding, obstruction, and rare perforation are also part of this syndrome.

## Selected Readings

1. Hutchison RE, Berard CW, Shuster JJ et al. B-cell lineage confers a favorable outcome among children and adolescents with large-cell lymphoma: A Pediatric Oncology Group study. *J Clin Onc* 1995; 13:2023-2032.
2. Murphy SB, Fairclough DL, Hutchison RE et al. Non-Hodgkin's lymphomas of childhood: an analysis of histology, staging, and response to treatment of 338 cases at a single institution. *J Clin Onc* 1989; 7:186-93.
3. Azizkhan RG, Dudgeon DL, Buck JR et al. Life-threatening airway obstruction as a complication to the management of mediastinal masses in children. *J Pediatr Surg* 1985; 20:816-22.
4. Magrath I. Malignant non-Hodgkin's lymphomas in children. In: Pizzo PA, Poplack DG. *Principles and Practice of Pediatric Oncology*, 2<sup>nd</sup> Edition. Philadelphia: JB Lippincott 1993; 537-75.
5. Whalen T. Hodgkin's and Non-Hodgkin's Lymphoma. In: Andrassy RJ ed. *Pediatric Surgical Oncology*. Philadelphia: W.B. Saunders Company 1998; 267-277.

# Rhabdomyosarcoma and Other Soft Tissue Tumors

*Marleta Reynolds*

## **Incidence**

Rhabdomyosarcoma is the third most common malignancy of childhood comprising 5% of childhood malignancies. Four to 7 cases per million population are reported per year. The peak age of incidence is between 3 and 5 years but these tumors have been found in neonates. The male-female ratio is 1:1.4. The head and neck (40%), genitourinary tract (20%), extremities (18%) and trunk (7%) are the most common sites. The retroperitoneum (7%), perineum and other sites (8%) have also been involved. Bladder and vaginal rhabdomyosarcoma usually occur in infants. Extremity rhabdomyosarcomas are most common in adolescents.

## **Clinical Presentation**

Clinical presentation varies with organ of origin. Eighty percent of patients present with local or regional disease at time of diagnosis. Tumors that develop in the nasopharynx or auditory canal present with bloody or purulent drainage. If arising from the muscles of head and neck, an asymptomatic firm swelling is apparent. Orbital tumors often cause pain and swelling about the eye with proptosis and diplopia. Bloody vaginal discharge or the presence of a red polypoid friable lesion at the introitus are highly suggestive of rhabdomyosarcoma of the vagina. Bladder tumors may mimic an infection with urinary frequency or other difficulties with urination. Prostatic lesions can block the urinary flow necessitating catheterization. Rectal exam is usually diagnostic as the prostatic lesion bulges into the rectum. Lesions of the trunk or extremity present as a firm fixed mass beneath the subcutaneous tissue.

Differentiating these lesions from benign nodules or tumors is often impossible without a biopsy. A family history should be taken because of the higher incidence of soft tissue sarcomas found in some families manifesting the Li-Fraumeni syndrome. The Li-Fraumeni syndrome is a familial clustering of rhabdomyosarcoma, soft tissue tumors in children, adrenocortical adenocarcinoma and early breast cancer in adults within families found to have a germline mutation of the p53 tumor suppressor gene.

## **Diagnosis**

Ultrasound, CT and MRI can be used to better define the anatomic relationships of the primary tumor. Metastatic evaluation includes chest radiographs,

abdominal and chest CT scan, bone scan, skeletal survey, bone marrow aspirate and biopsy.

Diagnosis is made by incisional biopsy with frozen section analysis to be certain that enough representative tissue has been sampled. Fresh tissue should be analyzed for cell surface markers and chromosomes. Special stains can be used to differentiate the small round blue cells of rhabdomyosarcoma from neuroblastoma, lymphoma and Ewing's sarcoma. Regional lymph nodes should be sampled in children with limb primaries.

## Pathology

There are three subtypes of rhabdomyosarcoma: pleomorphic, alveolar and embryonal. The pleomorphic subtype is rarely diagnosed today and consists of sheets of anaplastic cells. It carries a poor prognosis. There are conflicting opinions about the differentiation between alveolar and embryonal rhabdomyosarcoma and the clinical significance of establishing the histologic subtype. Newer classification systems propose that any alveolar pattern identified in a tumor would group that tumor in the alveolar subtype. Twenty to 30% of newly diagnosed rhabdomyosarcoma are of the alveolar subtype. The embryonal subtype constitutes two thirds of newly diagnosed rhabdomyosarcoma. Molecular techniques to differentiate these subtypes are being used more frequently and may clear up some of the confusion in the future.

## Classification and Staging

The staging system used for the Intergroup Rhabdomyosarcoma Study (IRS) with the results is outlined in Table 49.1.

## Treatment

Complete resection of the primary tumor with wide margins can be accomplished in some cases. In lesions of the head and neck or pelvis this may not be possible and a second look operation following chemotherapy can be performed. Chemotherapy with vincristine, dactinomycin, and cyclophosphamide (VAC) has proven efficacy in low-stage tumors. Other drug combinations continue to be evaluated to treat patients in the poor prognostic Stages II-IV and include etoposide and ifosfamide. Radiation therapy is recommended for residual disease

## Outcomes

The overall prognosis for survival in children with rhabdomyosarcoma is dependent upon site of origin. Orbit lesions have the best overall prognosis with a 5-year survival of 94%. The 5-year survival of other head and neck lesions is considerably less at 50%. Survival at five years for paratesticular, vaginal and limb/trunk lesions is 81%, 67%, and 44%, respectively.

## Lipomatous Tumors

Benign lipomas so often seen in adults are uncommon in children. Infiltrating lipomas and lipoblastomas are the more common benign fatty tumors found in children. Complete resection is indicated to prevent recurrence but may not be feasible depending on location. Liposarcomas are very rare in children and wide resection is indicated for cure.

**Table 49.1. Rhabdomyosarcoma staging: Intergroup rhabdomyosarcoma study**

Stage	Description	5-Year Survival
I	Complete Excision Except Regional Disease	85%
II	Excision with Microscopic Residual (Margins or Regional Nodes)	40%
III	Gross Residual Disease (Primary Site or Regional Nodes)	40%
IV	Distant Metastases	35%

Dissatisfaction with this staging system has prompted the suggestion that the TNM staging system be applied. This staging system is outlined in Table 49.2.

**Table 49.2. TNM classification and staging: Rhabdomyosarcoma**

Stage	Sites	T	N	M
I	Orbit			
	Head and Neck (Excludes Parameningeal)	T <sub>1</sub> or T <sub>2</sub>	N <sub>0</sub> , N <sub>1</sub> , N <sub>x</sub>	M <sub>0</sub>
	Genitourinary (Not Bladder or Prostate)	a or b		
II	Bladder/Prostate	T <sub>1</sub> or T <sub>2</sub>	N <sub>0</sub> , N <sub>x</sub>	M <sub>0</sub>
	Extremity	a		
	Cranial, Parameningeal			
	Other			
III	Bladder/Prostate	T <sub>1</sub> or T <sub>2</sub> a	N <sub>1</sub>	M <sub>0</sub>
	Extremity	b	N <sub>0</sub> , N <sub>1</sub> , N <sub>x</sub>	M <sub>0</sub>
	Cranial, Parameningeal			
	Other			
IV	All	T <sub>1</sub> or T <sub>2</sub> a or b	N <sub>0</sub> , N <sub>1</sub>	M <sub>1</sub>

T1-Confined to anatomic site of origin  
T2 – Extension a < 5 cm diameter  
b > 5 cm diameter  
N-Regional Nodes  
M-Distant Metastases

## Fibrous Tumors

There is a wide spectrum of lesions represented in the category of fibrous tumors. Differentiating the benign from malignant can be very difficult. Benign fibroma is a rare small lesion in the subcutaneous tissue that is treated with wide local excision. The fibromatoses can have benign histology but behave aggressively because of location or invasiveness. Cure can only be obtained by wide local excision. Mutilating surgery is not recommended until the tumor becomes “aggressive.”

Fibrosarcoma can present at any age. The most common locations are the trunk, extremities, face and neck. The tumor presents as a rapidly growing, firm, painless mass. Imaging of the primary site with CT or MRI is combined with metastatic evaluation using chest radiograph and chest CT. Complete surgical excision is required for cure. Chemotherapy and radiation therapy have no proven efficacy.

***Selected Readings***

1. Lobe TE, Weiner ES, Hays DM et al. Neonatal Rhabdomyosarcoma: The IRS Experience. *J Pediatr Surg* 1994; 29(8):1167-1170.
2. Womer RB, Sinniah D. Soft Tissue Sarcomas. In: D'Angie GJ, Sinniah D, Meadows AT et al, eds. *Practical Pediatric Oncology*. New York: Wiley-Liss 1992; 318-324.
3. Cofer BR, Weiner ES. Rhabdomyosarcoma. In: Andrassy RJ ed. *Pediatric Surgical Oncology*. Philadelphia: W.B Saunders Company 1998; 221-237.
4. Malkin D, Li FP, Strong LC et al. Germline p53 mutations in a familial syndrome of breast cancer, sarcomas and other neoplasms. *Science* 1990; 250:1233.

# Thyroid Masses

*Robert M. Arensman*

## Incidence

Thyroid masses are reasonably rare in childhood. If all children are examined for thyroid lesions, at most 1-3% will demonstrate a goiter or mass. Tumors, benign or malignant, are not common until mid life. The use of iodized salt in the United States has eliminated the prevalence of goiter that accounted for the large number of thyroid masses in inland regions during the last century and the early part of this century. Ionizing radiation is no longer used for trivial disease processes of young children so postradiation tumors have decreased greatly.

## Etiology

In cases of iodine deficiency or Grave's disease the development of goiter is easily explained due to hyperfunction to compensate for lack of substrate or overproduction of hormone. In the other thyroid lesions there is generally a lack of etiologic causation with the exception of chronic lymphocytic thyroiditis that is associated with antibodies to thyroidal tissue and appears to be an autoimmune disorder. Within the United States previous radiation exposure, except in those who had a previous malignant tumor, is now quite rare as a cause of thyroid abnormalities. Finally, there is a small group of families that have the multiple endocrine neoplasia (MEN) syndromes who develop medullary carcinoma as part of the pattern of their disease.

## Clinical Presentation

For most children, a neck mass is the presenting symptom (Fig. 50.1). The mass occurs within the location generally held by the thyroid, rises and falls with swallowing, and may be accompanied by nodes in the cervical chains. Toxic goiter will obviously be associated with those problems occurring with increased thyroid hormone: weight loss, change in skin or hair texture, heat intolerance, nervousness, etc. Occasionally pain is associated with a thyroid mass, especially in cases of thyroiditis. If a thyroid mass is sufficiently large, a child may have trouble with breathing or swallowing, but such extreme cases are rare indeed.

## Diagnosis

Generally, history and physical examination, thyroid hormonal testing, ultrasonography and thyroid scintigraphy will establish a diagnosis. History and physical establish the location, possibility of hypo/hyper function, and associated abnormalities such as cervical adenopathy. Hormonal testing of blood demonstrates euthyroid, or

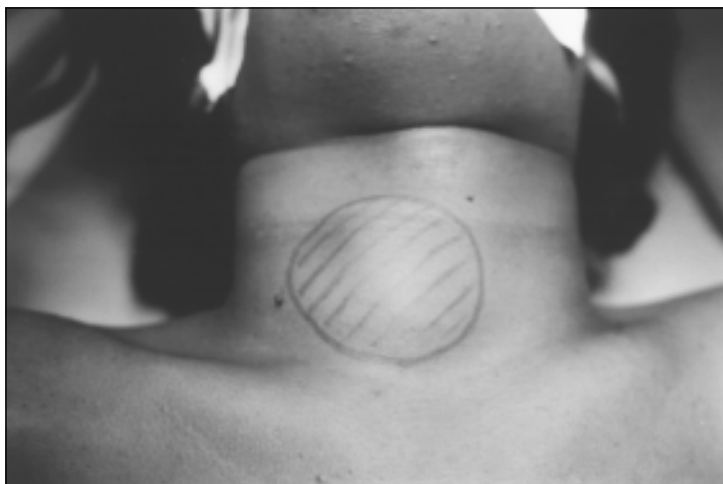

Fig. 50.1. Large and slightly eccentric thyroid mass that proved to be an adenoma (see Fig. 50.2) of the right thyroid lobe.

hypo/hyper functioning states consistent with the various goiters or toxic conditions. Scintigraphy locates masses within the thyroid substance and also demonstrates degree of function (cold vs toxic nodules); and ultrasonography is excellent for localizing masses and demonstrating cysts.

Fine needle aspiration has proven very reliable in establishing diagnoses in adults. There is much less experience with this technique in children, but the demonstration of clearly cystic lesions associated with normal cytology may help avoid needless biopsy in the younger patients also.

### Pathophysiology

In toxic states, excessive thyroid hormone increase the metabolic rate to high and ultimately dangerous levels. These can be initially controlled with hormonal blocking drugs but ultimately a permanent form of therapy is required. When the condition is simply a mass there may be no pathophysiologic consequence if the mass is benign. Thus simple, small cysts may be apparent visually but of no consequence to good health. However, nodules that are malignant pose threat to life and will eventually metastasize to cervical nodes or the lungs if left untreated.

### Classification

Thyroid masses are classified as benign or malignant. The more common causes of thyroid masses in children are listed in Table 50.1.

Although thyroid masses are rare within childhood years, almost 20% are malignant, especially if the nodule is “cold” on scintigraphy and occurs in a female. Malignancies are most often papillary histology unless associated with the multiple endocrine neoplasia (MEN) syndromes. Mutations in the RAS and RET proto-oncogenes have been reported frequently in association with thyroid cancers, particularly the follicular and medullary types.

**Table 50.1. Causes of thyroid masses in children**

<b>Benign</b>	<b>Malignant</b>
Goiter	Papillary Carcinoma
Thyroiditis	Follicular Carcinoma
Grave's Disease	Medullary Carcinoma
Adenoma	
Toxic	
Nonfunctioning	
Cyst	

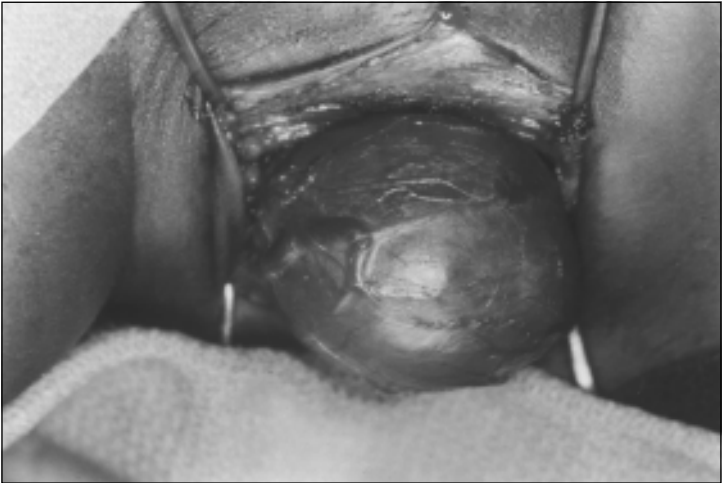

Fig. 50.2. Intraoperative view of a thyroid adenoma. Note large vessels on the surface supplying blood to this greatly enlarged thyroidal tissue.

### **Treatment**

Treatment rests on correct determination of the pathologic diagnosis. Small cystic lesions of the thyroid may be aspirated for cytology and observed. Goiters due to deficiency of substrate are treated with hormone replacement. Grave's disease is treated with blocking therapy until a euthyroid state is achieved or the best control possible is achieved. Surgical resection (Fig. 50.2) can then be offered, especially in young children for whom systemic radiation should be avoided. In chronic thyroiditis, surgery offers little other than a cosmetic reduction of a neck mass unless airway or swallowing problems are present.

In cases of malignancy, thyroidectomy with lymph node sampling is critical to establish diagnosis and disease extent. Removal of the thyroid facilitates treatment with radioactive iodine and future surveillance for recurrent or residual disease.



## Outcomes

Children with partial or total thyroidectomy for benign disease do very well. They recover quickly from surgery, generally need close observation for compliance in taking replacement or suppressive thyroid hormone, but do well in long term studies. Children with thyroid malignancies have long term survival with very low mortalities at 5, 10, and 15 year follow-up. However, eventual appearance of metastatic disease is reported in up to 50-80% of these children with ultimate early termination of life in these patients.

## Selected Readings

1. Rallison ML, Dobyns BM, Meikle AW et al. Natural history of thyroid abnormalities: Prevalence, incidence, and regression of thyroid diseases in adolescents and young adults. *Am J Med* 1991; 124:225.
2. Epstein FH. The molecular basis of thyroid hormone action. *N Engl J Med* 1994; 33:847.
3. Gorlin JB, Sallan SE. Thyroid cancer in childhood. *Endocrinol Metab Clin North Am* 1990; 19:649.
4. Raab SS, Silverman JF, Elsheikh TM et al. Pediatric thyroid nodules: Disease demographics and clinical management by fine needle aspiration biopsy. *Pediatrics* 1995; 95:46.
5. Newman KD. The current management of thyroid tumors in childhood. *Semin Pediatr Surg* 1993; 2:69.
6. Smith MB, Xue H, Strong L et al. Forty-year experience with second malignancies after treatment of childhood cancer: analysis of outcome following the development of the second malignancy. *J Pediatr Surg* 1993; 28:1342.

## **Section VI: Gastrointestinal Hemorrhage**

# Rectal Bleeding in Infancy

*Daniel A. Bambini*

## Incidence

Rectal bleeding, although not a frequently encountered presenting symptom in neonates or infants, causes significant parental anxiety and should be regarded seriously. Because rectal bleeding may result from several different diagnoses, its exact occurrence is difficult to quantitate. Blood loss is usually minor; massive rectal hemorrhage is uncommon.

## Etiology

Rectal bleeding in infancy can occur as a result of hemorrhage at upper or lower gastrointestinal sites. Upper gastrointestinal bleeding is defined as hemorrhage that occurs from a source proximal to the ligament of Treitz. Lower gastrointestinal bleeding occurs distal to the ligament of Treitz. Although many common etiologies of rectal bleeding in infancy have been described (Table 51.1), clinical diagnosis may not be possible in nearly one half of these children.

## Clinical Presentation

Clinical presentation depends almost exclusively upon the underlying etiology. The history and exam are important to narrow the field of possible etiologies. The presence or absence of related symptoms and/or signs are often helpful to establish the cause. Rectal bleeding may be in the form of hematochezia, melena, or occult blood. Hematochezia or bright red blood from the rectum, although usually from a distal gastrointestinal lesion, can occur from either upper or lower gastrointestinal sources. Melena or tarry stools only occurs when the bleeding occurs from a lesion proximal to the ligament of Treitz.

Perhaps the most common presentation of rectal bleeding in infancy, an otherwise healthy-appearing infant will be noted by the parent to have a small amount of bright red blood on the diaper or on the outside of stool. An anal fissure (Chapter 27) is the most likely etiology in this scenario, and is often identifiable as a small tear or ulceration at the anal verge usually located posteriorly. Anal fissures are very unusual in breast-fed infants.

Necrotizing enterocolitis (Chapter 67) may also produce rectal bleeding in infancy (usually in premature infants), although rectal bleeding is seldom the primary symptom. The diagnosis is suggested by history which may include prolonged gastric emptying, feeding intolerance, apnea, jaundice, abdominal distention, vomiting, thrombocytopenia, leukocytosis, other signs of sepsis. Recurrent rectal bleeding

**Table 51.1. Causes of rectal bleeding in infancy**

Location of Bleeding Source	Age		
	Neo- nate ( <i>&lt; 1mo</i> )	1mo to 1 yr	1 yr to 2 yr
<b>Upper Gastrointestinal:</b>			
Hemorrhagic disease	+		
Swallowed maternal blood	+		
Esophagitis or Gastritis (see Chapter 55)	+	++	
Peptic Ulcer Disease (see Chapter 55)			++
Gastric teratoma			
Esophageal or Gastric varices (see Chapter 56)			+
<b>Lower Gastrointestinal:</b>			
Anal fissure (see Chapter 27)	+++	++	
Necrotizing enterocolitis (see Chapter 67)	++		
Gangrenous bowel		++	
Malrotation with midgut volvulus (see Chapter 60)	++		
Hirschsprung's Disease with enterocolitis (see Chapter 64)			
Allergic proctocolitis			
Intussusception (see Chapter 25)		++	+
Prolapse (see Chapter 27)			
Polyps (see Chapter 54)		++	+
Meckel's Diverticulum (see Chapter 57)		++	
Lymphonodular hyperplasia			
Enteritis (i.e., campylobacter, Yersinia, salmonella)			
Inflammatory Bowel Disease (see Chapter 94)			++
Intestinal duplication (see Chapter 66)			
GI vascular malformation			

(+++ most common cause, ++ more common cause, + relatively more common)

after recovery from necrotizing enterocolitis (NEC) suggests recurrent NEC or a post-NEC gastrointestinal stricture.

Intussusception (Chapter 25) occurs most commonly in infants between 6 and 18 months of age. Rectal bleeding associated with intussusception is classically described as having a "current-jelly" appearance, which is probably only apparent in about a third of cases. Intermittent abdominal pain is the usual distinguishing symptom. A palpable sausage-shaped abdominal mass helps establish the diagnosis. A barium or pneumatic enema is performed to both confirm and reduce the intussusception.

An acute onset of melena and bilious emesis in an otherwise healthy baby suggests malrotation with midgut volvulus (Chapter 60). At onset, the physical examination may be unremarkable. With time, the abdomen will become progressively distended and tender to palpation. An upper gastrointestinal contrast study should be obtained immediately to confirm the diagnosis. Emergent laparotomy is indicated. Gangrenous bowel from midgut volvulus or other causes (segmental small bowel volvulus, internal hernia, sigmoid volvulus, etc.) is the second most common of rectal bleeding in infants between one and 12 months of age.

## Diagnosis

The exact origin of gastrointestinal hemorrhage remains undiagnosed in about 30-50% of neonates and infants with rectal bleeding. For most of these infants, the blood loss is minor, self-limited, and seldom recurs. Diagnosis begins with a thorough history and physical examination. Diagnostic evaluation of significant or recurrent hemorrhage may include upper and/or lower gastrointestinal endoscopy and radiographic procedures including contrast enema, enterolysis, tagged red cell studies, arteriography, etc.. The choice of diagnostic tests and the urgency of the diagnostic work-up should be based upon the most likely etiologic lesion as well as the severity of bleeding. Minor bleeding may resolve spontaneously and require no further evaluation. Major bleeding (i.e., shock, transfusion) requires aggressive evaluation.

Melena per rectum suggests upper gastrointestinal hemorrhage. The initial diagnostic maneuver for suspected upper GI hemorrhage is to place a nasogastric tube. Aspiration of gross blood or "coffee ground" appearing fluid confirms the presence of upper gastrointestinal bleeding. Absence of bile in an otherwise nonbloody gastric aspirate does not exclude the possibility of upper gastrointestinal hemorrhage arising distal to the pylorus of the stomach.

## Treatment

The treatment of rectal bleeding in infants depends upon accurate identification of the source of bleeding. In many infants, if not most, diagnosis is not possible and reassurance to the parents is all that can be offered. Given the large array of entities which can cause rectal bleeding in infants, a detailed discussion of treatment for each lesion is beyond the scope of this Chapter. Information regarding the treatment of many of these entities is provided elsewhere in this book (Table 51.1).

## Selected Readings

1. Sherman N, Clatworthy H Jr. Gastrointestinal bleeding in neonates: a study of 94 cases. *Surgery* 1967; 62:614-619.
2. Spencer R. Gastrointestinal hemorrhage in infancy and childhood: 476 cases. *Surgery* 1964; 55:718-734.
3. Arensman R. Gastrointestinal bleeding. In: O'Neill Jr. JA et al. eds. *Pediatric Surgery*, 5th Edition. St. Louis: Mosby 1253-1256.

# Polyps of the Gastrointestinal Tract

*Riccardo Superina*

## **Incidence**

Intestinal polyps are much less common in children than in adults, and their association with syndromic clusters is very common. Malignant transformation except in the syndromic cases is less than in adults, and the approach to management is more expectant. Approximately 1% of children have asymptomatic intestinal juvenile polyps which are benign. Other types of polyps are much rarer.

## **Etiology and Pathology**

The etiology of polyps in children is multifactorial and depends on the type of polyp. Etiologies and pathologic features will be discussed individually in the classification section.

## **Clinical Presentation**

### *Bleeding*

Lower intestinal bleeding is the hallmark presentation of most polypoid conditions. The bleeding is frequently associated with crampy abdominal pain. The blood is usually red, indicating its origin in the lower gastrointestinal tract, and small in quantity, unlike bleeding from duplications or Meckel's diverticula with peptic ulceration. If the bleeding is from polyps in the small bowel, the blood will appear darker. In the rare cases of duodenal or gastric polyps, rectal bleeding may appear black (i.e., melena).

### *Pain*

Crampy abdominal pain is a frequent symptom along with bleeding. The pain does not necessarily occur with the bleeding.

### *Intussusception*

Traction on a polyp may cause intussusception anywhere it occurs. Usually, colocolonic intussusception occurs only when a colonic polyp serves as a lead point. The symptoms include crampy, intermittent pain, bleeding from venous engorgement of the mucosa, and signs of intestinal obstruction (i.e., vomiting, distention, obstipation). Unlike idiopathic intussusception, intussusception from a polyp occurs in older children and may not be reduced with contrast enema.

## Diagnosis

The diagnosis of polypoid lesions depends primarily on two modalities: intestinal contrast studies and endoscopy. Endoscopy is advantageous as it can be both diagnostic and therapeutic. Contrast studies for colonic polyps can be very accurate and can be used to follow polyps for changes in number and size. Upper intestinal polyps in the stomach and duodenum are also accurately visualized with contrast studies.

Small bowel polyps may be difficult to image even with small bowel enemas. Small bowel polyps are notoriously difficult to diagnose, and thankfully, occur only very rarely. Diagnoses is most often made at the time of laparotomy when bleeding or obstructive symptoms have prompted an operation.

## Classification

### *Benign*

#### Isolated Juvenile polyps

These are the most common polypoid lesion of infancy and childhood. The peak age of incidence is between the ages of 3 and 10 years. As with most polyps, crampy abdominal pain and bleeding with bowel movements are the presenting symptoms. Juvenile polyps are hamartomatous excrescences of the intestinal mucosa. They appear to lengthen from traction caused by peristalsis and the flow of intestinal contents. There is no malignant potential, and juvenile polyps naturally auto-amputate if given enough time. Seventy-five percent of juvenile polyps occur in the rectum and sigmoid colon, but juvenile polyps may occur in the right colon as well.

#### Peutz-Jeghers Syndrome

This well-known syndrome causes polyps predominantly in the small bowel. Its hallmark distinguishing feature is the pigmented lesions observed on the buccal mucosa and lips of these patients. Malignant degeneration can occur, and lifelong surveillance is necessary.

#### Adenomatous Polyp

This lesion is rare but known to occur in childhood (Fig. 52.1). Malignant degeneration can occur as in the adult-type lesion. Familial adenomatous polyposis (FAP) is a syndrome that results in multiple colorectal polyps (see below). Traditionally, the presence of at least one hundred individual polyps is required to make this diagnosis.

#### Hemangiomatous Polyps

Hemangiomatous polyps cause profuse bleeding and occur predominantly in the distal small bowel. Profuse bleeding may require excision if it occurs repeatedly. They tend to regress with time as do most hemangiomas after the age of two years.

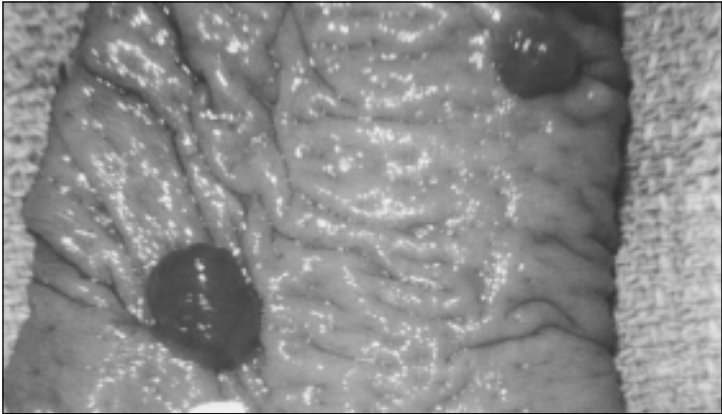


Fig. 52.1. Two sessile, adenomatous polyps in a young girl whose mother and four sisters all had familial polyposis.

### *Malignant*

#### **Juvenile Polyposis and Familial Adenomatous Polyposis (FAP)**

Juvenile polyposis is an autosomal dominant disorder which causes polyps predominantly in the large and small bowel. The lesions resemble adenomatous polyps individually but are actually mucous-retention polyps. These polyps can occur anywhere along the gastrointestinal tract. It is considered a premalignant condition and 6% of these children will eventually develop malignancy.

Familial adenomatous polyposis is characterized by hundreds of adenomatous polyps in the rectum and colon causing diarrhea and bleeding. It also shares an autosomal dominant pattern of inheritance. Malignant degeneration in one or more polyp is virtually certain before the age of twenty years.

#### **Adenocarcinoma**

Although rare, isolated colonic or small bowel adenocarcinoma can occur in childhood. It can be mistaken for a juvenile polyp until it has advanced beyond the stage where it can be excised completely. Adenocarcinomas usually arise from villous adenomas.

#### **Lymphoma**

Small bowel lymphoma is usually a non-Hodgkin's B cell lymphoma. The two most common gastrointestinal sites of non-Hodgkin's lymphoma are the distal small bowel and the stomach. Proximal gastric lesions may be visualized and biopsied endoscopically although the lesion originates in the submucosa. In the small bowel, CT scanning can usually image the lesion if it has attained sufficient size to cause symptoms. Lymphoma of the bowel is rare in infancy, but the incidence increases with advancing age peaking in adolescence. Bleeding is the main symptom from gastric lesions. Small bowel lymphomas cause crampy abdominal pain, and may



result in intussusception. Some may erode and perforate into the free abdominal cavity presenting as gastrointestinal perforation.

### Treatment

The treatment of polyps of the GI tract in children can vary from simple observation of benign lesions to wide excision and chemotherapy for malignant ones.

Juvenile polyps should be removed endoscopically once diagnosed. This is done to stop the symptoms as well as establish the diagnosis. Most are within easy reach of a flexible sigmoidoscope and can be snared around the stalk. There is rarely more than one lesion and removal is curative. Cecal or ascending colonic polyps can be observed as long as the lesions do not grow and exceed 2 centimeters in diameter. However, with the widespread use of colonoscopy in pediatrics, endoscopic removal of these lesions is now the treatment of choice in this previously hard to reach area.

The overall guiding principle in the treatment of Peutz-Jeghers polyps should be one of bowel conservation. Since the entire gastrointestinal tract can be affected, excision of all affected areas could easily result in intestinal insufficiency. Regular surveillance through endoscopy or small bowel contrast studies should be done to detect polyps which are growing and could be malignant. Large polyps or those causing significant symptoms should be removed. Endoscopic removal should be attempted first. For lesions normally beyond the range of normal endoscopy, a combined endoscopic-surgical approach can be attempted where the surgeon at laparotomy guides the endoscopist through the small bowel for visualization and removal of large lesions. Resection of segments of bowel should be reserved only for cases where cancer has developed and invaded the submucosa, or in areas where polyps are particularly dense and causing severe symptoms. Duodenal polyposis may be a very difficult problem. Although most polyps can be excised endoscopically or surgically, diffuse duodenal involvement with bleeding has been treated with pancreaticoduodenectomy.

Lymphomatous lesions are surgically removed. Perforations or areas of intussusception are resected. Radical surgery with lymph node dissection is unnecessary as all these patients require systemic chemotherapy. Staging with CT scanning and bone marrow sampling are necessary, and most patients require insertion of subcutaneous reservoirs for long-term chemotherapy. The outlook for small bowel lymphoma depends on the staging and cellular subtype. Prognosis for this disease has been steadily improving with the advent of more effective chemotherapeutic regimens.

Treatment of children with familial adenomatous polyposis (FAP) involves not only the individual involved but should also extend to others in the family. Family members should be screened and referred for genetic counseling and genetic analysis. Definite genetic markers have been identified in this family of disorders, which may include other syndromes such as Gardner's syndrome (multiple osteomas, fibromas, epidermoid cysts). The surgical treatment of FAP requires planning the process with the family and the patient. It is customary to do a complete colonic and rectal removal with a sphincter saving operation in early adolescence. This generally occurs at a time when the patient understands and can participate in treatment planning and execution.

A Soave type operation (endorectal pullthrough) is the one most commonly used. The mucosa of the distal rectum is stripped and the terminal ileum is pulled

through. Both straight pull throughs and reservoir operations in the form of a J or S pull through have been advocated. Patients have attained the size where a stapling device can be used to construct both the reservoir and perform the lower anastomosis. It is customary to protect the pouch and the anastomosis with a loop ileostomy which is then closed 4-6 weeks later after all the suture lines have healed and a contrast study of the pouch has demonstrated no leaks.

The prognosis when the disease is treated in a timely fashion is excellent. Periodic studies to inspect the remaining native anal mucosa is essential for the early detection of new lesions which can be easily ablated. Genetic counseling is essential so that all family members can be screened and so that all patients affected by the disease can consider the risks to their own children.

All other lesions are exceptionally rare in children including the adenomatous polyp or frank carcinoma. Treatment always includes endoscopic removal whenever possible, saving surgical resection for cases where this is impractical or contra-indicated (i.e., invasive cancer).

### *Selected Readings*

1. Lelli Jr. JL, Coran AG. Polypoid disease of the gastrointestinal tract. In: O'Neill Jr. JA et al, eds. *Pediatric Surgery*, 5th Edition. St. Louis: Mosby 1998; 1283-1296.
2. Gardner EJ, Richards RC. Multiple cutaneous and subcutaneous lesions occurring simultaneously with hereditary polyposis and osteomatosis. *Am J Hum Genet* 1953; 5:139.
3. Raffensperger JG. Polyps of the gastrointestinal tract. In: Raffensperger JG ed. *Swenson's Pediatric Surgery*, 5th Edition. Norwalk: Appleton & Lange 1990; 463-472.

# Peptic Ulcer Disease and Gastritis

*Heron E. Rodriguez*

Acid-peptic injury to the mucosa of the stomach and duodenum in the form of inflammation, erosions and ulcerations represents the most common disease affecting the upper gastrointestinal tract. Although reasonably rare in childhood, peptic ulcers and stress gastritis are still the most common forms of acid peptic disease (APD).

In children, gastroduodenal ulcers can be classified as either primary or secondary. Primary ulcerations are the result of an intrinsic ulcer diathesis. Secondary ulcers, also called stress ulcers, are related to critical illness, sepsis, shock or major physical or thermal injury. Among these, two types of ulcers have been given eponyms. The "Cushing ulcer" occurs in association with head injury, encephalopathy, or major surgery. The "Curling ulcer" occurs after extensive burns.

## Incidence

The true incidence of APD in children is unknown. Estimates from the pre-endoscopic era suggest that there are 3.5-14.7 new cases per 100,000 children each year. Contrary to the trend in adults, the incidence of APD in children appears to be increasing. Although this may be in part related to the increased use of ulcerogenic drugs and the increase in the number of children surviving major illnesses and trauma, it appears that the true prevalence of APD is increasing. Overall the incidence in boys is 2-3 times higher than in girls, but an equal sex incidence is noted in infants and very young children. Of children presenting with ulcer disease, 33-56% will have first and/or second-degree relatives with APD.

## Pathophysiology

The process of peptic ulceration results from the offensive interaction of hydrochloric acid, pepsin, and the defensive cellular mechanisms attempting to preserve the integrity of the gastroduodenal mucosa. A causal relationship between APD and *Helicobacter pylori* has been established.

Basal acid output in children with APD is not significantly different than that of control subjects. Although acid and pepsin are necessary for the development of ulcers, acid hypersecretion is only rarely the cause of APD. The Zollinger-ellison syndrome (hypergastrinemia secondary to gastrinoma) is exceptionally rare in children. The increased frequency of APD in children with chronic renal failure is attributed to elevated gastrin levels. G-cell hyperplasia, systemic mastocytosis and

hyperparathyroidism (also seen with chronic renal failure) are rare conditions associated with increased hyperacidity.

The most common mechanism for ulcer formation involves a decrease in the ability of the mucosa to protect itself against acid injury. Normally, a thick mucus layer in the surface of the stomach provides an effective barrier to the action of acid. In addition, continuous cell turnover in the gastric mucosa assures epithelial integrity and cell regeneration after injury. Cholinergic agonists, prostaglandins, and cytokines stimulate the release of mucus and are protective. However, mucosal ischemia reduces mucus production increasing the ability of hydrogen ions to diffuse back into the mucosa. A low arterial pH of the blood supplying the stomach may also impair the ability of the mucosa to protect itself. The effects of low perfusion states, steroids, and anti-inflammatory medications impair all of these defense mechanisms, leaving the mucosa prone to acid injury. Inadequate gastric emptying may also promote mucosal injury by increasing the time that the mucosa is exposed to acid.

*Helicobacter pylori* is a fastidious, spiral-shaped, gram-negative rod whose rediscovery has changed traditional concepts about the pathogenesis and treatment of APD. *H. pylori* gastritis is the most common cause of chronic gastritis in children. Nearly all patients with duodenal ulcers have *H. pylori* gastritis. About 85% of patients with gastric ulcers are infected with *H. pylori*. If acid suppression is used as the only form of treatment, a relapse rate of 90% per year can be expected. When *H. pylori* is eradicated with antibiotics, the relapse rate falls to 10% annually. Interestingly, the majority of individuals infected by *H. pylori* develop neither gastritis nor ulcer disease. Other cofactors are clearly important for development of peptic ulcer disease.

### Clinical Presentation

The symptoms of gastritis, peptic ulcer and duodenitis are similar and nonspecific. In the first month of life, perforation and bleeding are the usual presentations. Up to two years of age, the major symptoms are:

1. recurrent vomiting,
2. refusal of feedings,
3. persistent crying,
4. slow growth, and
5. gastrointestinal hemorrhage.

In preschool children, postprandial pain, vomiting and hemorrhage are the common presenting features. In older children, the presentation is similar to that of adults. The pain of peptic disease is often vague and difficult for young patients to describe. It may be temporally related to meals or relieved by eating. Nocturnal awakening caused by episodes of pain is a common feature and may differentiate organic from psychogenic pain. Anorexia, nausea, early satiety, eructation and vomiting all are common symptoms.

APD is confirmed in only 15-20% of all children presenting with symptoms of dyspepsia. Psychogenic abdominal pain accounts for the vast majority of cases. The differential diagnosis of dyspepsia in children with APD includes esophagitis, cholecystitis, liver disease, pancreatitis, and infectious gastroenteritis. In children presenting with upper gastrointestinal hemorrhage (i.e., hematemesis), the differential

diagnosis should include APD, esophagitis, Mallory-Weis tear, esophageal or gastric varices, and other causes of gastrointestinal hemorrhage.

## Diagnosis

Barium upper gastrointestinal radiography (UGI) has been extensively used in the evaluation of APD. It only detects 75% of duodenal ulcers and fewer than 40% of gastric ulcers in children. In addition to its low sensitivity and specificity in identifying ulcers, another important disadvantage in the evaluation of suspected APD is the inability of UGI to detect the presence of *H. pylori*. UGI is useful in the evaluation of early satiety and vomiting when obstructive conditions such as malrotation or gastric outlet obstruction need to be ruled out.

Upper GI flexible endoscopy offers several advantages in the evaluation of APD. The presence of ulcers can be determined or excluded with great accuracy. Direct visualization or biopsies of the affected areas of the mucosa can determine the cause of ulcer disease and gastritis. With endoscopic biopsy, *H. pylori* can be identified by histologic study, rapid urease testing, or tissue culture. Alternatively, *H. pylori* infection can be identified by the serum urease test, the carbon-labeled urea breath test, and *H. pylori*-specific serum immunoglobulin G (IgG) measurement. Finally, endoscopic methods (i.e., electrocautery, sclerotherapy) provide therapeutic means to obtain hemostasis in cases of significant, acute upper gastrointestinal hemorrhage.

## Medical Treatment

Antacids effectively heal peptic ulcers when compared with placebo (75% compared with 40%). Nevertheless, compliance is disappointing and the side effects of diarrhea and constipation are not uncommon. The dominant pathway of parietal cell activation is paracrine stimulation of the histamine-2 ( $H_2$ ) receptor by histamine.  $H_2$  receptor antagonists (i.e., cimetidine, ranitidine, famotidine) inhibit parietal cell responses to all secretagogues and are the main form of therapy for APD.  $H_2$  antagonists are effective agents against APD, with relapse rates of less than 20%.

Other medical treatment options include omeprazole, sucralfate, and prostaglandin therapies. Omeprazole inhibits gastric secretion at the final common pathway, the  $H^+-K^+$  adenosine triphosphatase pump. It is effective in healing ulcers in 95% of patients within 4 weeks. Sucralfate forms a protective coat on the gastric mucosa. The negative charge of the sulfated disaccharide aluminum salt of sucralfate adheres to the positive protein charge of the injured gastric mucosa. Sucralfate also seems to enhance mucosal microvascular flow, mucus production, and prostaglandin secretion. Prostaglandin replacement (misoprostol) has been shown to be effective in the prevention and treatment of ulcers associated with the use of nonsteroidal anti-inflammatory drugs (NSAIDs).

Eradication of *H. pylori* substantially reduces ulcer recurrence. Amoxicillin and metronidazole, usually in combination with bismuth, are added to conventional therapy for 2 weeks. Because ulcers tend to recur, follow-up endoscopy to prove healing and eradication of *H. pylori* is considered.

## Surgical Treatment

Children with primary APD have a high rate of recurrence throughout childhood and into adult life. In the past, early surgical intervention for these children

has been recommended. At present, surgery is limited almost exclusively to the treatment of APD complications.

In the majority of cases, bleeding responds well to nasogastric decompression, volume replacement and transfusion therapy. For major or recurrent bleeding, endoscopic treatment modalities are available. These include therapeutic injections (i.e., hypertonic NaCl, epinephrine, absolute ethanol) and cauterization with heater probe, bipolar coagulator or laser. If medical and endoscopic treatments fail, surgery is indicated. Acute perforation or gastric outlet obstruction are both complications of APD that require surgical intervention.

The surgical procedures used to treat peptic ulcer disease include:

1. simple closure of a localized perforation,
2. gastrotomy with oversewing of the base of a bleeding ulcer,
3. partial and subtotal gastrectomies,
4. vagotomy with pyloroplasty, and
5. highly-selective vagotomy.

Vagotomy and pyloroplasty is the traditional approach that provides good long-term results causing minimal disturbance of growth and development. The choice of the operation used to treat APD should be individualized, taking into account the likelihood of recurrence, the comorbid factors, and the nutritional and developmental needs of the growing child.

### *Selected Readings*

1. Scherer III LR. Peptic ulcer and other conditions of the stomach. In: O'Neill Jr. JA et al, eds. *Pediatric Surgery*, 5<sup>th</sup> edition. St. Louis: Mosby 1998; 1119-1125.
2. Raffensperger JG. Stress bleeding and peptic ulcer. In: Raffensperger JG, ed. *Swenson's Pediatric Surgery*, 5<sup>th</sup> edition. Norwalk: Appleton & Lange 1991; 473-477.
3. Mezzoff AG, Balistreri WF. Peptic ulcer disease in children. *Pediatrics in Review* 1995; 16:257.

# Portal Hypertension

*Kimberly Brown*

## **Anatomy and Physiology**

The portal venous system drains blood from the stomach, pancreas, gallbladder, spleen, and intestines into the liver. The portal vein arises in the embryo as the left and right vitelline veins, which form numerous anastomoses among the developing hepatocytes. Following gut rotation, the left vitelline vein is obliterated, and the right vitelline vein persists as the main portal vein. Portosystemic anastomoses exist in four main areas,

1. the gastro-esophageal veins via the cardiac vein and perforating esophageal veins,
2. the retroperitoneum via the pancreaticoduodenal veins and the retroperitoneal-paravertebral veins,
3. gastrosplenic-splenoportal vein, and
4. the hemorrhoidal plexus.

The portal venous system lacks valves, which means the flow of blood is entirely dependent upon the pressure gradient within the system. Normal flow toward the liver is termed hepatopedal, while significantly increased portal venous resistance can result in hepatofugal flow away from the liver. Normal portal venous pressure is 5-10 mm Hg greater than central venous pressure. Portal hypertension is defined as elevation of the portal venous-IVC pressure gradient above 10-12 mm Hg.

## **Etiology**

Portal hypertension in children can be divided into two major categories based upon the anatomic location of the increased portal resistance. Extrahepatic portal hypertension (EHPH) is most commonly the result of portal vein obstruction due to thrombosis. Risk factors for portal vein thrombosis include umbilical vein catheterization, neonatal sepsis, blunt abdominal trauma, and omphalitis; idiopathic cases are also reported. The thrombosis frequently recanalizes which results in a cavernous transformation of the portal vein into numerous smaller channels.

Intrahepatic portal hypertension (IHPH) is typically associated with congenital liver or biliary diseases in children. Biliary atresia is by far the most common cause of IHPH in children. Other etiologies include sclerosing cholangitis, familial cholestatic syndromes, cystic fibrosis,  $\alpha$ -1 antitrypsin deficiency, hemochromatosis, Wilson's disease, viral hepatitis, autoimmune hepatitis, or idiopathic neonatal hepatitis. The manifestations of liver disease appear long before the sequelae of portal

hypertension in most of these children. Congenital hepatic fibrosis (CHF) is a rare cause of intrahepatic portal hypertension in children. Hepatocyte function is normal in livers affected by CHF.

### **Incidence**

Liver disease in children is relatively rare, with an incidence of 1 in 5000-7000. EHPH is approximately twice as common as IHPH in children. The most common cause of IHPH, biliary atresia, occurs at a rate of 1 in 15,000 live births. This distribution is distinctly opposite that seen in adults, who most commonly develop intrahepatic portal hypertension as a result of alcoholic cirrhosis.

### **Clinical Presentation**

Children with IHPH usually present between several months to one year of life with severe hepatic dysfunction, manifested by jaundice, hepatic encephalopathy, and malnutrition complicated by poor growth and increased susceptibility to infections. While the child's liver disease may dominate the clinical picture, it is important to remember that portal hypertension is present in these patients and to be aware of its potential complications.

Extrahepatic portal hypertension most commonly presents in the first decade of life with gastrointestinal hemorrhage from esophageal varices. Bleeding is often precipitated by a respiratory or gastrointestinal febrile illness, and aspirin is frequently implicated. Increased portal pressure causes splenic congestion, resulting in splenomegaly and hypersplenism. Portal hypertension, therefore, is suspected in any child with splenomegaly, unexplained thrombocytopenia, leukopenia, ascites or gastrointestinal hemorrhage.

### **Diagnosis**

In a child presenting with an initial episode of gastrointestinal bleeding, abdominal ultrasonography is used to confirm the etiology. The presence of portal vein thrombosis, the extent of collateral formation, and the direction of portal vein flow is established by this noninvasive and relatively inexpensive diagnostic exam. Likewise, in a child with evidence of chronic liver disease, ultrasonography confirms the presence of portal hypertension and evaluates the liver for abnormalities such as nodular cirrhosis, fibrosis, or ductal dilatation. The presence of spontaneous portosystemic shunts and esophageal varices as indicated by thickened vessels in the lesser omentum is also documented.

Upper endoscopy is used to identify and quantitate esophageal varices. This procedure is ideally performed in the operating room under general anesthesia to provide a controlled environment for a thorough study and possible therapeutic intervention (i.e., sclerotherapy, banding). Documentation of varices includes size, location and presence of cherry red spots or red walls. Identification of other potential sites of bleeding is also important, as many children with portal hypertension also have gastric varices, peptic ulcer disease, esophagitis, or a portal hypertensive gastropathy or enteropathy.

Angiography is a much more rarely used diagnostic and potentially therapeutic modality used in certain cases of portal hypertension. The venous phase of a celiac axis injection demonstrates the anatomy of the portal venous system, while a



percutaneous transhepatic approach allows for direct entry into the portal vein and therapeutic dilation of portal vein strictures especially liver transplant patients.

## Treatment

The most common, clinically significant complication of portal hypertension is gastrointestinal bleeding from esophageal varices. In the acute setting, massive hemorrhage is managed with intensive care monitoring, transfusion of red blood cells and fresh frozen plasma, and potentially intubation and sedation to minimize agitation that increases variceal pressure. Octreotide infusions effectively control acute hemorrhage in the vast majority of children with portal hypertension and variceal bleeding. Endoscopic variceal banding or sclerotherapy is occasionally used in cases where hemorrhage does not resolve with supportive care. Once the patient has stabilized, endoscopy with sclerotherapy or banding is employed to prevent repeat episodes of hemorrhage.

Gastrointestinal hemorrhage in children with extrahepatic portal hypertension tends to be less severe than bleeding that occurs in children with IHPH due to the presence of a normally functioning liver. In addition to coagulation abnormalities, many patients with IHPH also have significant malnutrition which contributes to the greater morbidity and mortality of gastrointestinal bleeds in this group.

Medical treatment of portal hypertension is aimed at relieving the pressure in the portal system. Pharmacotherapy, consisting primarily of  $\beta$ -blockade, reduces cardiac output and therefore portal venous pressure. Octreotide, a long-acting synthetic somatostatin analogue, may also be used to decrease blood flow in the portal and azygous veins, as well as to reduce collateral blood flow.

Surgical treatment of portal hypertension can be either direct, which involves ligation of the varices themselves, or indirect, in which the portal venous system is decompressed with a surgical shunt. A nonselective portosystemic shunt diverts the majority of portal blood to the caval system, causing a higher incidence of hepatic encephalopathy. Examples include portocaval, mesocaval and central splenorenal shunts. Selective portosystemic shunts shunt a portion of portal blood into the systemic circulation, with distal splenorenal shunt being the most common. Recently, selected children with EHPH due to portal vein thrombosis have been successfully treated by surgical creation of a mesenterico-portal venous bypass (Rex shunt). Recurrent bleeding, shunt thrombosis and hepatic encephalopathy are the most common complications of surgical shunting.

Treatment of intrahepatic portal hypertension focuses on the primary liver disease. In biliary atresia (Chapter 67), surgery to decompress the biliary tract is ideally performed within the first three months of life. In the Kasai procedure, the atretic segments of the extrahepatic bile ducts are excised and a Roux loop is anastomosed to the porta hepatis. If performed early, before significant liver injury and cirrhosis, the Kasai procedure can delay liver failure and the need for transplantation in as many as two thirds of patients. For advanced cirrhosis and other intrahepatic sources of portal hypertension, liver transplantation is the definitive treatment. Consequently, surgical interventions prior to transplant should not incur significant risk to the patient, nor should they interfere with the ability to perform a subsequent liver transplant in the patient.

## Outcome

Patients with biliary atresia experience jaundice, poor nutrition and rapidly declining liver function due to biliary cirrhosis. Currently, if the biliary tract is diverted before 3 months of age, one third of these patients will survive without requiring transplant, while one third will survive to require transplant in childhood and the remainder will die from liver failure.

For patients with EHPH, sclerotherapy is effective in the treatment of acute variceal bleeding in up to 75% of patients. However, several follow-up sessions are necessary to obliterate the varices, and a rebleeding rate of 5-25% is expected. Persistent variceal bleeding as well as hypersplenism may require a surgical shunt. Selective shunts have proven successful for the control of bleeding, thrombocytopenia, and leukopenia, without creating great risk of encephalopathy.

## *Selected Readings*

1. Bambini DA, Superina RA, Almond PS et al. Experience with the Rex shunt in children with extrahepatic portal hypertension. *J Pediatr Surg* 2000; 35:13-19.
2. Shilyansky J, Roberts EA, Superina RA. Distal splenorenal shunts for the treatment of severe thrombocytopenia from portal hypertension in children. *J Gastrointest Surg* 1993; 3:167-172.
3. Alonso EM, Hackworth C, Whittington PF. Portal hypertension in children. *Clinics in Liver Disease* 1997 May; 1(1):201-221.
4. Watanabe FD, Rosenthal P. Portal hypertension in children. *Curr Opin Pediat* 1995; 7:533-538.
5. Hassall E. Nonsurgical treatments for portal hypertension in children. *Gastrointestinal Endoscopy Clinics of North America* 1994; 4(1):223-258.
6. Rowe MI, O'Neill JA Jr., Grosfeld JL et al. *Essentials of pediatric surgery*. St. Louis: Mosby-Year Book Inc. 1995; 1075-1086.
7. Raffensperger JG. *Swenson's Pediatric Surgery*, 4<sup>th</sup> edition. New York: Appleton-Century-Crofts 1980; 443-452.

# Meckel's Diverticulum

*Richard Fox*

## Incidence

Meckel's diverticulum is the most common gastrointestinal tract anomaly. It occurs with a worldwide prevalence of approximately 2-4%. For the majority of patients, this remnant remains clinically silent throughout life. Its presence is not suspected unless complications arise or it is identified as an incidental finding at autopsy or laparotomy. In asymptomatic patients, there is no gender predilection. However, in symptomatic patients, males are affected approximately 2-4 times more frequently than females. Meckel's diverticulum is known as the disease of "two's." Two percent of the population is affected, it occurs twice as frequent in males, it is located two feet from the ileocecal valve, it is two inches long and two centimeters wide, and two types of mucosa often exist. Furthermore, the majority of symptomatic patients present by two years of age.

## Etiology

During the third week of fetal development, the midgut opens into the yolk sac, remaining temporarily connected by the vitelline duct (or yolk stalk). This duct divides the cranial and caudal portions of the midgut (distal duodenum, jejunum and proximal ileum, distal ileum and cecum, appendix, ascending colon, and proximal two-thirds of the transverse colon, respectively.) As intestinal maturation proceeds, the vitelline duct narrows. By the third month of embryogenesis, the duct disappears as the physiologic intestinal herniation spontaneously reduces. If complete regression fails to occur, an omphalomesenteric duct-related anomaly results (Chapter 22). The anomaly that results is solely dependent upon the stage of developmental arrest.

A complete diverticulum, the most clinically significant anomaly, extends directly from the antimesenteric border of the ileum. In approximately 75% of patients, the tip remains free and unattached within the abdominal cavity. In the remaining 25%, the Meckel's diverticulum remains attached to the anterior abdominal wall. The connection consists of either a solid fibrous cord (arterial or ductal remnant) or omphalo-ileal fistula extending from the umbilicus to the ileum. Vitelline duct cysts result if a cyst forms in the midportion of the cord (Chapter 22).

The yolk sac is initially supplied by the paired vitelline arteries. As fetal maturation proceeds, the left vitelline artery disappears, leaving the right vitelline artery to form the superior mesenteric artery. Meckel's diverticulum is commonly supplied from a branch arising from the ileal artery. Infrequently, the vascular supply arises

directly from an ileocolic arterial branch or from the mesentery directly. The artery is always an end-artery.

### **Clinical Presentation**

Symptoms are usually absent unless complications occur. The most commonly encountered complications of Meckel's diverticulum are bleeding, obstruction, or inflammation (with or without perforation). Meckel's diverticuli occasionally identified in association with symptoms of umbilical fistulas or hernia. Infrequently, tumors can develop in Meckel's diverticuli. Carcinoid is the most common tumor, though adenocarcinoma, leiomyoma, lymphoma occur as well. The incidence of complications diminishes with increasing age.

Bleeding typically occurs in children less than five years of age, with two being the average age. Meckel's diverticulum is the most common cause of a massive pediatric lower gastrointestinal hemorrhage. Bleeding is characteristically episodic and painless. It recurs frequently and is often severe enough to require multiple blood transfusions for resuscitation. However, some children may present only with melena and mild anemia, corresponding with a slower, more controlled blood loss. Bleeding almost always occurs at the junction between normal ileal mucosa and the heterotopic (usually gastric or pancreatic) diverticular mucosa. Less common sites include the tip of the diverticulum or the mesenteric border of the ileum. Bleeding is usually secondary to peptic ulceration caused by hydrochloric acid secreted by heterotopic parietal cells. The differential diagnosis includes juvenile polyps, inflammatory bowel disease, peptic ulcer disease of the stomach or duodenum, and blood dyscrasias.

Obstruction occurs from intussusception, herniation, kinking or volvulus. Intussusception is the etiology in nearly 50% of cases. It commonly presents before ten years of age. The diverticulum may act as the leadpoint causing an ileo-ileal intussusception with rapid progression to an ileo-colic presentation. The patient presents with early vomiting, abdominal pain, and oftentimes, a palpable abdominal mass. If untreated, intestinal vascular compromise and ischemic necrosis can occur. Volvulus is the second most common mechanism of obstruction and occurs in 25% of cases. Obstruction can also occur secondary to internal herniation around an aberrant right vitelline artery or fibrous band. Intestinal prolapse through a patent vitelline duct also causes intestinal obstruction. Infrequently, obstruction occurs when a Meckel's diverticulum protrudes through an indirect inguinal hernia (Littre's hernia). Most obstructions due to Meckel's diverticuli are not diagnosed until laparotomy.

Meckel's diverticulitis presents similar to acute appendicitis. The diagnosis is rarely made prior to laparotomy. Obstruction of the lumen of the diverticulum occurs secondary to any number of objects, ranging from a fecalith, parasite or even an ingested fish bone. Inflammation follows obstruction. Pressure builds within the closed-off diverticulum which eventually compromises venous outflow. Arterial inflow is diminished, bacterial invasion ensues, and gangrenous changes in the diverticular wall ultimately lead to perforation. Unlike perforated appendicitis, Meckel's diverticulum is more likely to present with free air and diffuse peritonitis because of its precarious location away from the lateral abdominal wall. Pain symptoms are very similar to those of acute appendicitis. Periumbilical pain occurs secondary to hollow

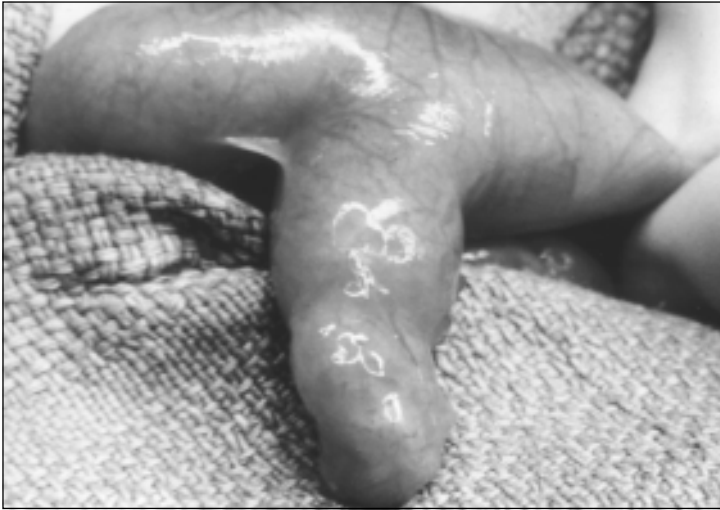

Fig. 55.1. Meckel's diverticulum in the usual antimesenteric position with aberrant tissue in the distal tip responsible for symptoms.

viscus distension. Somatic pain localization depends upon the location of the diverticulum and the surrounding peritonitis.

### Diagnosis

Prior to the advent of the radio-labeled technetium scan in 1970, children with massive lower gastrointestinal bleeding were presumed to have Meckel's diverticulum and taken for immediate laparotomy. Currently the Meckel's scan has a false negative rate of 1.7%, false positive rate of 0.05%, sensitivity of 85% and specificity of 95%. To maximize sensitivity, three agents are available. Pentagastrin is used to facilitate technetium uptake in gastric mucosal cells.  $H_2$ -receptor blockers, such as cimetidine, are used to reduce the gastric cellular excretion of technetium. Glucagon may be used to inhibit intestinal peristalsis which lengthens the cells exposure to the labeled technetium maximizing the time for uptake. A bladder catheter is inserted prior to scanning to evacuate technetium excreted in the urine and to simplify radiographic interpretation. False positive scans result from intussusception, hydro-nephrosis, arteriovenous malformation, gastrointestinal duplication, inflammatory bowel disease, neoplasms and other intestinal areas containing heterotopic gastric mucosa.

### Pathology/Pathophysiology

Meckel's diverticulum is a true diverticulum. It contains all three normal bowel layers: mucosa, submucosa, and muscularis propria. Vitelline duct cells are pluripotential. As a result, 50% of all diverticula contain heterotopic gastric mucosa. If symptomatic, the prevalence is closer to 75%. Heterotopic pancreatic tissue is

present in only 5%. Five percent contain both gastric and pancreatic tissue. Heterotopic colonic or enteric mucosa occur infrequently (i.e., 2% each). Many ulcers are nonapparent on inspection and are thus best detected on microscopy. Of note, unlike peptic ulceration of the stomach and duodenum (Chapter 55), ileal ulcers from a Meckel's diverticulum are not associated with *Helicobacter pylori*.

## Treatment

Treatment of a symptomatic diverticulum requires operative intervention. Irrespective of the etiology, appropriate preoperative resuscitation with intravenous fluids or blood products is paramount. For bleeding or diverticulitis, a right lower quadrant incision is usually performed. If necessary, medial extension of the wound allows greater exposure. The cecum is identified and followed proximally toward the ileum. The diverticulum is noted, the arterial supply is identified and ligated, and the diverticulum is removed. Surgical options include simple diverticulectomy without ileal resection, a wedge resection to include immediately surrounding ileum, or an ileal resection with primary anastomosis.

For cases presenting as intussusception, an initial barium enema is attempted for immediate hydrostatic reduction. Diverticulectomy usually follows at a later date unless intestinal ischemia is suspected which requires immediate laparotomy.

For patients who present with intestinal obstruction, rarely is the diagnosis of a Meckel's diverticulum made preoperatively. Accordingly, a midline laparotomy incision may be appropriate. This affords the most versatility in decompression and potential resection.

For the myriad of persistent vitelline duct anomalies (Chapter 22), transverse supraumbilical or infraumbilical incisions are appropriate. The anomaly is identified, careful dissection proceeds to identify and remove all involved structures.

The best management strategy for the asymptomatic or incidentally encountered Meckel's diverticulum remains controversial. Excision is prudent in patients with palpable heterotopic mucosa, obvious inflammation, abdominal wall attachments, or unexplained abdominal pain. Other conditions require individual judgment.

## Outcomes

Upon resection of a Meckel's diverticulum, cure from subsequent bleeding or inflammation is expected. The most common postoperative complication is adhesive small bowel obstruction which occurs in 5-10% of patients.

## Selected Readings

1. Amoury RA, Snyder CL. Meckel's diverticulum. In: O'Neill Jr. JA et al, eds. Pediatric Surgery, 5th Edition. St. Louis; Mosby 1998; 1173-1184.
2. Mackey WC, Dineen PA: Fifty years experience with Meckel's diverticulum. Surg Gynecol Obstet 1983; 156:56.
3. St. Vil D et al. Meckel's diverticulum in children: A 20-year review. J Pediatr Surg 1991; 26:1289.
4. Jewett TC, Duszynski DO, Allen JE. The visualization of Meckel's diverticulum with 99m-Tc-pertechnetate. Surgery 1970; 65:567.
5. Kusumoto H et al. Complications and diagnosis of Meckel's diverticulum in 776 patients. Am J Surg 1992; 164:382.

## **Section VII: Anomalies of the Gastrointestinal Tract**

# Intestinal Obstruction in the Neonate

*Daniel A. Bambini*

## Incidence

The overall incidence of neonatal intestinal obstruction is difficult to estimate because it may result from such a variety of embryonic anomalies and functional abnormalities. However, intestinal obstruction is the most common surgical emergency of the newborn. The incidence of neonatal intestinal obstruction is approximately 1 case per every 500-1000 live births. Approximately 50% of these neonates will have intestinal atresia or stenosis. Duodenal atresia and jejunal atresia occur in approximately equal numbers, although some authors report that jejunal ileal atresia is the more common.

## Etiology

Intestinal obstruction may be caused by several conditions in the neonate (Table 56.1). The specific etiology of each condition is described in the appropriate Chapter of the book devoted to that problem.

## Clinical Presentation

The majority of neonates with intestinal obstruction present shortly after birth, yet prenatal diagnosis of obstructive gastrointestinal lesions is possible in selected patients. Proximal obstructing lesions can produce proximal bowel dilation with hyperperistalsis that is readily identifiable by prenatal ultrasonography. The classic "double bubble" appearance of duodenal atresia can be identified in utero with ultrasonography. Distal intestinal obstructions are less likely to cause polyhydramnios but on occasion dilated loops of bowel may be identified as anechoic masses. In cases of meconium ileus, dilated loops of bowel filled with echogenic meconium may be identified.

Five clinical findings suggest intestinal obstruction in the neonate: maternal polyhydramnios, excessive gastric aspirant, abdominal distention, bilious vomiting, and obstipation. The presence or absence of each of these clinical findings depends largely upon the level of gastrointestinal obstruction. Early recognition of intestinal obstruction is imperative if the complications of respiratory compromise and sepsis are to be avoided.

**Maternal polyhydramnios:** Amniotic fluid is continuously ingested and absorbed within the intestine of the fetus. The ingested fluid is transferred to the maternal circulation via the placenta to be excreted in the mother's urine. Proximal gastrointestinal obstruction interrupts this process and leads to accumulation of



**Table 56.1. Causes of neonatal intestinal obstruction****Common:**

Malrotation (duodenal obstruction, volvulus, internal hernia)  
 Duodenal atresia, stenosis or annular pancreas  
 Jejunal atresia or stenosis  
 Ileal atresia or stenosis  
 Simple meconium ileus  
 Meconium ileus with perforation  
 Meconium plug syndrome  
 Hirschsprung's disease  
 Drug-induced ileus  
 Hypertrophic pyloric stenosis

**Uncommon:**

Pyloric atresia or web  
 Tumors  
 Intussusception  
 Segmental intestinal dilatation  
 Small left colon syndrome  
 Milk bolus obstruction  
 Colonic atresia  
 Functional Intestinal obstruction  
 Intestinal Pseudo-Obstruction  
 Neuronal Intestinal Dysplasia  
 Megalocystis-Microcolon-Intestinal Hypoperistalsis Syndrome  
 Inguinal hernia

excess amniotic fluid. Distal small bowel or colonic obstructions do not usually result in polyhydramnios.

**Excessive gastric output:** Passage of a nasogastric or orogastric tube is often performed in premature infants and infants with a maternal history of polyhydramnios. If the initial volume of gastric aspirant is large (> 50 cc) or is bilious then gastrointestinal obstruction should be considered.

**Abdominal distention:** Abdominal distension may not be apparent at birth but develops over time as ingested air accumulates proximal to an obstruction. The time of onset, degree and characteristic appearance of the distention may suggest the level of obstruction. Gastric distention within a few hours may cause the epigastrium to protrude indicating an obstruction of the stomach or duodenum. Gradual overall abdominal distension occurring over a 12-24 hour period suggests a distal gastrointestinal tract obstruction.

**Bilious emesis:** It is usual for healthy newborns to spit-up postprandially, but bilious emesis in a term newborn is distinctly abnormal. Premature infants (< 35 weeks) occasionally have bilious emesis secondary to an immature or poorly functioning pyloric sphincter but proximal gastrointestinal obstruction must still be considered. Sepsis with an associated paralytic ileus may also result in bilious emesis. Vomiting begins soon after delivery if the lesion is proximal or complete, but may be delayed in cases of distal or incomplete obstruction.

**Failure to pass meconium:** A normal newborn is expected to pass a large amount of thick, dark green, shiny meconium usually within the first twelve hours of life

and almost always by 24 hours. Failed or delayed passage of meconium suggests obstruction, but neonates with proximal obstructing lesions may pass a normal amount of meconium. Because neonates with ileal atresia or distal small bowel obstruction may pass several meconium stools on the first day of life, passage of meconium does not exclude the possibility of obstruction. Preterm infants commonly have delayed passage of meconium. Approximately 20% will not pass stool during the first 48 hours following birth.

Additional physical findings that suggest obstruction are the presence of intestinal patterning and peristalsis that is visible through the intestinal wall. Distended loops of bowel may be palpable as ill-defined tubular masses. Masses that feel hard and with a “doughy” consistency can be felt especially in cases of meconium ileus. The rectum may feel tight on exam if small and unused as in cases of distal bowel obstruction. Lethargy and hypotonia are late signs of intestinal obstruction and the resultant sepsis. Abdominal wall discoloration and ecchymosis suggest perforation and/or necrosis.

## Diagnosis

The diagnosis of neonatal intestinal obstruction is largely made on clinical grounds. Flat and upright abdominal radiographs are obtained to confirm the diagnosis. Swallowed air serves as the contrast media to help delineate the level of obstruction. A normal neonate swallows air from birth and has air within the proximal small bowel within 30 minutes. Air usually reaches the colon by 3-4 hours and can be identified in the rectum by 6-8 hours. There should be no air-fluid levels in an upright film of a normal newborn.

Specific radiograph abnormalities of the lesions causing obstruction are described in other Chapters, however, when a complete obstruction exists the air pattern may stop abruptly leaving the remainder of the bowel airless. Bowel loops proximal to complete obstruction are dilated. Multiple dilated loops of bowel with “stepladder” air fluid levels on the upright film is the pattern most often seen with distal intestinal obstruction. However, air-fluid levels are not characteristic of the distal intestinal obstruction due to meconium ileus. Partial obstructions as in stenosis may allow small amounts of air to pass beyond the level of obstruction, but the paucity of bowel gas in the bowel distal to dilated bowel segments can easily be identified as abnormal. The abdominal films should always be inspected for peritoneal and/or scrotal calcifications which may signify an intrauterine perforation with meconium peritonitis.

Barium or gastrograffin contrast enema examination may be useful to distinguish between causes of distal bowel obstruction (ileal atresia, meconium ileus, Hirschsprung's, meconium plug, etc.) and in cases of meconium ileus or plug may also be therapeutic. Upper gastrointestinal barium studies are generally not as useful unless one is seeking patterns of abnormal bowel rotation. UGI contrast studies are reserved for cases of partial obstruction that cannot be confirmed by plain radiographs.

## Pathology/Pathophysiology

Proximal intestinal obstruction as in cases of duodenal or pyloric atresia leads to fluid loss that has a high concentration of hydrogen, potassium and chloride ions. Hypochloremic alkalosis can develop if fluid losses are not replaced. Distal intestinal

obstructions lead to fluid and electrolyte loss from both emesis as well as from fluid sequestered into the lumen of dilated bowel loops. Fluid shifts and intravascular volume depletion may lead to severe dehydration, oliguria, metabolic acidosis, and inadequate peripheral perfusion. Prolonged intestinal obstruction leads to alterations in intestinal motility, accumulation of gas and fluid, and bacterial overgrowth. Severe abdominal distention in the neonate can easily impair diaphragmatic function causing respiratory acidosis. As plasma volume loss increases, alterations in blood flow may result in bowel ischemia and necrosis.

### **Classification and Staging**

Classification systems for specific obstructing lesions of the gastrointestinal tract are presented in other Chapters of this book. Please refer to specific lesions for details.

### **Treatment**

The specific management strategies and surgical considerations for the various conditions causing intestinal obstruction in the neonate are described in other Chapters of this book. However, the initial treatment of any suspected neonatal obstruction includes placement of a nasogastric tube to decompress the stomach and to prevent vomiting/aspiration. Fluid and electrolyte replacement should be quickly undertaken to resuscitate the infant and restore circulating blood volume in anticipation of the potential need for surgical intervention. Most obstructive lesions in neonates will require surgical therapy and surgery should not be delayed once volume resuscitation is adequate. If an intestinal anastomosis is anticipated perioperative antibiotics are indicated.

### **Outcomes**

The outcomes from neonatal intestinal obstruction vary with the etiology of the obstruction. Overall survival is generally good but often is influenced by the associated anomalies of each condition. Please refer to the appropriate Chapters for disease specific treatment results.

### ***Selected Readings***

1. Raffensperger JG, Seeler RA, Moncada R. Intestinal obstruction in the newborn. In: Raffensperger JG et al, eds. *The Acute Abdomen in Infancy and Childhood*. Philadelphia: JB Lippincott Company 1970; 1-19.
2. Haller, Jr. JA, Talbert JL: Gastrointestinal Emergencies. In: Haller, Jr JA, Talbert JL, eds. *Surgical Emergencies in the Newborn*. Philadelphia: Lea & Febiger 1972; 86-111.
3. Filston HC. Other causes of intestinal obstruction. In: O'Neill, Jr. JA et al, eds. *Pediatric Surgery*, 5th Edition. St. Louis: Mosby 1998; 1215-1221.

# Pyloric and Duodenal Obstruction

*Daniel A. Bambini*

Congenital obstructing lesions of the pylorus and duodenum include pyloric atresia, duodenal atresia and stenosis, and annular pancreas. Hypertrophic pyloric stenosis and malrotation, also present as proximal gastrointestinal obstruction and are discussed in Chapters 24 and 60, respectively.

## Incidence

Pyloric atresia is extremely rare, accounting for less than 1% of atresias or stenoses of the gastrointestinal tract. The incidence of neonatal duodenal obstruction is estimated at 1 in 5,000 to 10,000 live births. Seventy-five percent of intestinal stenoses and 40% of atresias are found in the duodenum. Multiple atresias occur in 15% of cases.

## Etiology

Pyloric atresia is usually caused by a solid mucosal diaphragm obstructing the pylorus and may result from in utero vascular or mechanical fetal injury. Familial and autosomal recessive forms have been described in association with epidermolysis bullosa.

Intrinsic duodenal obstructions vary from duodenal narrowing or webs to complete discontinuity of the duodenum. The origin of duodenal and pyloric atresia may be a defect in recanalization of the embryonic duodenum. Normally, the proliferating epithelial lining occludes the duodenal lumen during the fifth to sixth gestational week. Vacuolation and recanalization of the duodenum are completed by the eighth to tenth week.

Annular pancreas and preduodenal portal vein may cause extrinsic duodenal obstruction. Annular pancreas results when the anterior and posterior anlagen of the pancreas fuse to become a ring of pancreatic tissue surrounding the atretic or stenotic 3rd portion of the duodenum.

## Clinical Presentation

### *Pyloric Obstruction*

The newborn with complete pyloric atresia or prepyloric antral web presents shortly after birth with persistent, nonbilious vomiting and possibly epigastric distension. Respiratory findings secondary to aspiration are common and include dyspnea, tachypnea, and cyanosis. Excessive salivation and poor weight gain may also occur. Prepyloric antral diaphragms may also present as an acquired lesion in

older children. Symptoms in older children may include epigastric abdominal pain, vomiting, or postprandial fullness. Thirty percent of these infants have associated anomalies, epidermolysis bullosa being the most common.

### ***Duodenal Obstruction***

Fifty percent of neonates with duodenal atresia are born premature and are of low birth weight. Maternal polyhydramnios is present in up to 75% of cases. Bilious vomiting on the first day of life is the usual presenting feature. Vomiting may be nonbilious in cases of preampullary atresia (20%). Abdominal distention may or may not be present since obstruction is very high in the gastrointestinal tract. Meconium is usually passed in the first 24 hours followed by constipation. Incomplete obstruction may delay the onset of symptoms.

The anomalies associated with duodenal obstruction in order of greatest frequency are Down's syndrome (30%), malrotation, congenital heart disease, esophageal atresia, urinary tract malformation, and anorectal malformation. Vertebral anomalies are present in about one third of cases. Duodenal atresia is associated with the VACTERL syndrome/VATER association.

### **Differential Diagnosis**

The differential diagnosis of pyloric and duodenal obstruction includes malrotation, pyloric atresia, pyloric web, hypertrophic pyloric stenosis, duodenal atresia, annular pancreas, and preduodenal portal vein.

### **Diagnosis**

A plain x-ray of the abdomen is useful to confirm the diagnosis in cases of suspected duodenal or pyloric obstruction in the newborn. In the rare cases of pyloric atresia, abdominal films will typically demonstrate gas in a dilated stomach with no gas beyond the pylorus. Three radiologic signs confirm the diagnosis of pyloric atresia:

1. single gas bubble sign,
2. pyloric dimple sign,
3. absence of a 'beak' sign (found in hypertrophic pyloric stenosis). Ultrasonography will demonstrate an absence of the normal echo pattern of the pyloric channel and surrounding pyloric muscle.

An antral web gives the appearance of a membranous septum projecting into the antral lumen, perpendicular to the antral wall, located 1-2 cm proximal to the pylorus. A central aperture is present in 90% of cases.

Abdominal plain films in neonates with duodenal atresia (Figs. 57.1 and 57.2) will demonstrate dilated stomach and duodenum giving the characteristic 'double bubble' sign with no gas distal to the duodenum. If partial duodenal obstruction is present, some air is usually present in the distal intestine. Ultrasound examination can also identify the double bubble sign characteristic of duodenal atresia (Fig. 57.3).

### **Pathology and Classification**

Pyloric atresia occurs as one of three types: membranous pyloric obstruction (Type A), segmental atresia (Type B), pyloric aplasia (Type C). the approximate distribution of each type is 55%, 35%, and 10% respectively.

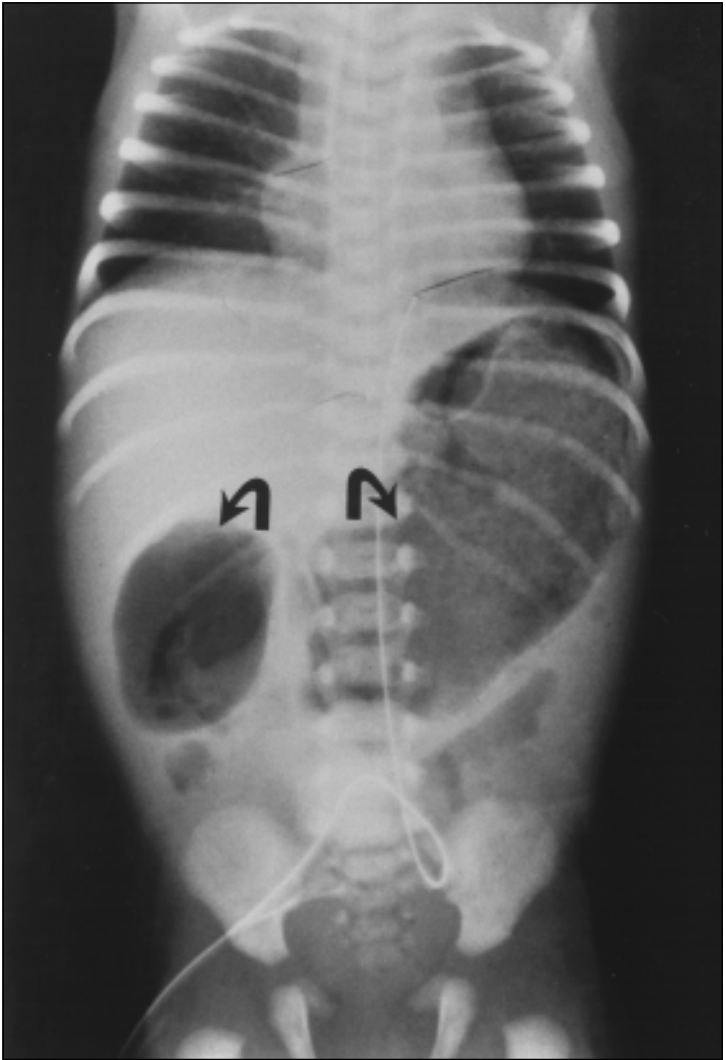


Fig. 57.1. Double bubble sign demonstrated only with swallowed air shortly after birth. Two arrows point to the stomach and the duodenum.

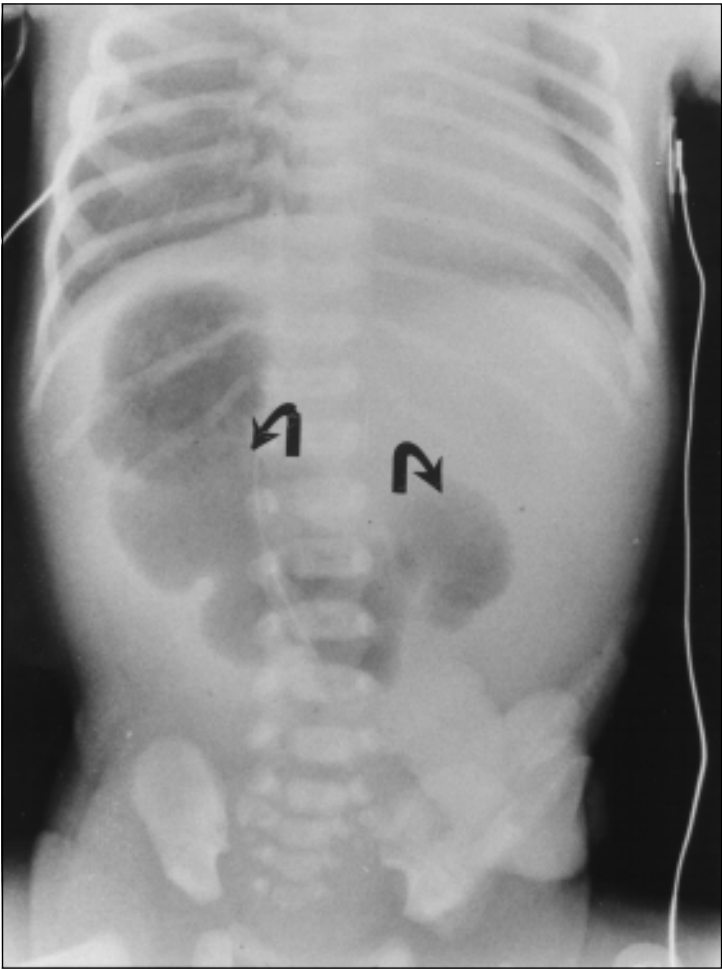


Fig. 57.2. A similar demonstration of the double bubble sign reversed in a patient with situs inversus and duodenal obstruction.

Duodenal obstruction can be secondary to intrinsic or extrinsic lesions. Intrinsic duodenal obstruction may be caused by duodenal atresia, diaphragm with or without perforation (wind-sock web), or stenosis. In addition, duodenal obstruction may be found as proximal and distal segments separated by a gap or joined by a fibrous cord. Extrinsic duodenal obstruction can be caused by annular pancreas, malrotation, or preduodenal portal vein. Annular pancreas constricts the 3rd portion of the duodenum, but the obstruction is usually due to a concomitant duodenal atresia or stenosis. Duodenal obstruction occurs distal to the ampulla of Vater in 80% of cases.

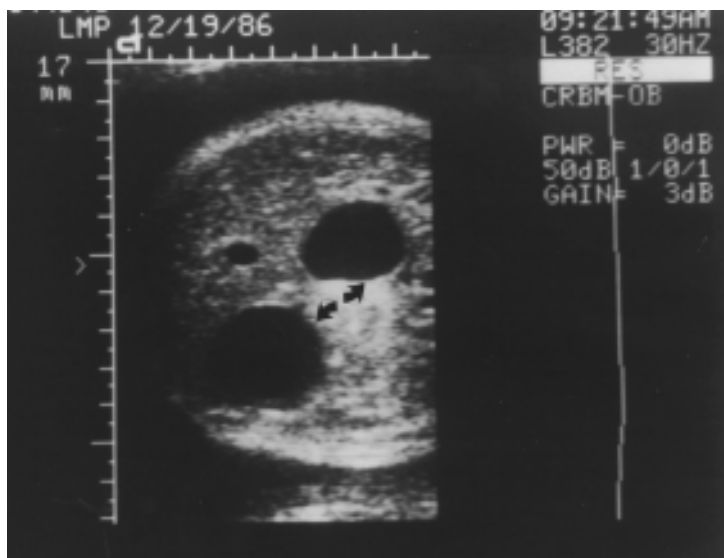


Fig. 57.3. Ultrasound demonstration of double bubble sign associated with the various types of duodenal obstruction (atresia, stenosis, membrane, or annular pancreas). Such demonstrations have even been done prenatally.

## Treatment

### *Perioperative Management*

Newborns admitted within 1-2 days with pyloric or duodenal atresia are usually in good physical condition unless it is a case of epidermolysis bullosa associated with a pyloric atresia. Gastric distension is relieved by nasogastric decompression. Intravenous hydration to correct dehydration, metabolic alkalosis, and electrolyte imbalance is appropriate preoperative therapy.

### *Indications for Surgery*

Surgical intervention is generally indicated in all forms of pyloric or duodenal obstruction. Medical treatment consisting of thickened feeds and antispasmodics can be used in the rare case of antral web without significant obstruction, but surgical therapy is preferred. Transgastric excision of the membrane without pyloroplasty has been described.

### *Pyloric Obstruction*

Pyloroplasty is the treatment of choice for membranous pyloric obstruction (Type A) and short pyloric atresia (Type B). The membrane is excised through a longitudinal incision across the pylorus and the mucosa is reapproximated. A catheter must be passed distally to ensure there is no distal atresia. The longitudinal incision in the pylorus is closed transversely. Long pyloric atresias and pyloric aplasia are surgically treated by resection and end-to-end gastroduodenostomy.



### ***Duodenal Obstruction***

In neonates with duodenal atresia, stenosis, or annular pancreas the surgical treatment of choice is a 'double diamond' duodenoduodenostomy. A transverse incision is made in the distal end of the proximal duodenal segment and a longitudinal incision is made in the distal segment. An end-to-end anastomosis is performed. Duodenal webs are excised through a longitudinal duodenotomy over the site of the obstruction with special attention to locate and preserve the ampulla. The duodenotomy is closed transversely after the distal patency of the duodenum is confirmed.

### ***Postoperative Care***

Nasogastric decompression is continued postoperatively along with fluid and electrolyte replacement. Patients with duodenal atresia often have prolonged bilious drainage from the nasogastric tube due to ineffective peristalsis of the dilated duodenum. Oral feedings may be delayed for several days to 2+ weeks until the volume of gastric drainage decreases. Central venous access for hyperalimentation is often desirable. Persistent dysfunction and deformity of the dilated proximal duodenum occasionally requires duodenoplasty.

### ***Outcomes***

Early diagnosis and surgical intervention have improved survival of neonates with pyloric or duodenal obstruction. Pyloric atresia is associated with an overall mortality of 45% with the majority of deaths occurring in cases with epidermolysis bullosa and multiple intestinal atresias. Mortality in infants with duodenal obstruction is approximately 15-20% and is attributable to a high incidence of associated anomalies, prematurity, and low birth weight in these infants.

### ***Selected Readings***

1. Dalla Vecchia LK, Grosfeld JL, West KW et al. Intestinal atresia and stenosis: A 25-year experience with 277 cases. *Arch Surg* 1998; 133:490-497.
2. Raffensperger JG. Pyloric and duodenal obstruction. In: Raffensperger JG ed. *Swenson's Pediatric Surgery*, 5th Edition. Norwalk: Appleton & Lange 1990; 509-516.
3. Muller M, Morger R, Engert J. Pyloric atresia: Report of four cases and review of the literature. *Pediatr Surg Int* 1990; 5:276.
4. Stauffer UG, Schwoebel M. Duodenal atresia and stenosis-annular pancreas. In: O'Neill Jr. JA et al, eds. *Pediatric Surgery*, 5th Edition. St. Louis: Mosby 1998; 1133-1143.

# Malrotation and Volvulus

*Vinh T. Lam*

## Incidence

From autopsy studies it appears that the incidence of malrotation in the general population is between 0.2-0.5%. However, the generally accepted incidence based on clinical presentation at the major children's hospitals is one per every 6000 live births. It is clear that this condition can be present throughout life without causing any clinical problems. However, those afflicted generally present within the first six months of life with smaller numbers occurring each year throughout childhood. Presentation after teenage years or in adult life is quite rare.

## Etiology

The growth rate of the gastrointestinal tract in early gestation is faster than that of the body. Therefore, intestinal development occurs through the umbilical ring within the physiological umbilical hernia (fourth week of gestation). During the tenth week of gestation the intestine begins an orderly migration back into the abdominal cavity. This includes a counterclockwise rotation of two intestinal segments: the duodenojejunal segment and the cecocolic segment.

The duodenojejunal limb returns first and rotates 270° to the right of the superior mesenteric artery (SMA), passing beneath the artery into the left upper quadrant. At the completion of this process, the duodenojejunal junction is fixed to the retroperitoneum at the ligament of Treitz.

The rotation of the cecocolic limb is also counterclockwise. It rotates from a position left of the SMA, around SMA axis to attain its final position in the right lower quadrant. By the twelfth week of gestation this process is complete, and the colon becomes fixed to the retroperitoneum.

A broad based mesentery provides a stable position for the small intestine within the peritoneal cavity. It begins in the right iliac fossa at the ileocecal junction and runs obliquely upward across the abdomen to the ligament of Treitz. The duodenum is fixed securely to the retroperitoneum as the C-loop. The ascending and descending colon are fixed to the right and left retroperitoneum, and the transverse colon is fixed at either end as it drapes across the superior mesentery vessels. If fixation does not take place, the intestine is suspended by a thin stalk containing the superior mesenteric vessels and is susceptible to midgut volvulus.

Children with congenital diaphragmatic hernia, omphalocele or gastroschisis will have malrotation as a matter of course since the bowel cannot undergo normal

rotation and fixation. However, other gastrointestinal problems, including intestinal atresias and Hirschsprung's disease, have occurred in association with malrotation.

### **Classification**

During the course of rotation and fixation, three conditions develop that make the gut susceptible to volvulus:

#### *Nonrotation*

This is the most common anomaly. It occurs when neither duodenojejunal or cecocolic limb have undergone correct rotation. The duodenojejunal and ileocecal junctions lie close together while the midgut hangs on a thin stalk containing the superior mesenteric vessels. The entire gut is poorly stabilized due to the narrow base of the mesentery.

#### *Abnormal Rotation of the Duodenojejunal Limb*

Nonrotation of the duodenojejunal limb followed by normal rotation and fixation of the cecocolic limb results in duodenal obstruction caused by abnormal mesenteric (Ladd's) bands extending from the colon across the anterior duodenum. The risk of midgut volvulus in this condition is lower because there is a relatively broad mesenteric base between the duodenojejunal junction and the cecum.

#### *Abnormal Rotation of the Cecocolic Limb*

Normal rotation of the duodenojejunal limb with nonrotation of the cecocolic limb results in the same potential for midgut volvulus as complete nonrotation. In this condition, the cecum and the first part of the colon lie close to the midline against the third portion of the duodenum over the superior mesenteric vessels. The mesenteric base is narrow and stability is poor. Volvulus easily develops.

Reverse rotation of either limb create rarer forms of malrotation presenting as colonic obstruction, entrapment in a paraduodenal hernia, or midgut volvulus.

### **Clinical Presentation**

Presentation varies depending on the specific mechanism of obstruction and the extent of vascular compromise. Symptoms may be either mild and intermittent or severe and catastrophic with complete obstruction and vascular occlusion.

The most common symptom of malrotation with volvulus is vomiting (95%). Initially, the vomitus is gastric or bilious in nature but may become grossly bloody if bowel compromise is present. Abdominal distention follows with bloody diarrhea (28%) indicating bowel ischemia or necrosis. Children with volvulus appear severely ill and complain of generalized abdominal pain if they can speak. Lethargy, grunting respirations, dehydration, peritonitis and shock follow as the bowel ischemia persists or worsens.

### **Diagnosis**

The diagnosis of malrotation with or without volvulus usually rests upon radiographic confirmation. Plain abdominal radiographs may demonstrate obstruction and abdominal distention. The radiographic appearance of a "gasless" abdomen occurs when the volvulus has created a closed-loop obstruction from which the intraluminal air has been absorbed and replaced with fluid.

Contrast radiographic studies can easily demonstrate the site of obstruction and the presence of the malrotation. In simple malrotation, the upper gastrointestinal series shows the incomplete rotation of the duodenojejunal loop (Fig. 58.1). If volvulus has occurred, there is frequently an abrupt cut-off to passage of barium described as a “bird’s beak” in the third portion of the duodenum. Alternatively, duodenal obstruction may be only partial and have a spiral or corkscrew appearance.

Barium enema can identify the position of an abnormally placed cecum suggesting malrotation. However, the position of the cecum is highly variably in small children, and about 15% of children with malrotation will have a normally placed colon.

Ultrasonography has proven to be very reliable in making the diagnosis of malrotation at some centers. The relative position of the superior mesenteric artery and vein is normally quite constant and characteristic with the vein to the right of the artery. Absence of this normal relationship strongly suggests malrotation.

### **Treatment**

Midgut volvulus is a surgical emergency. A child with this condition requires intravenous access, a nasogastric tube, expeditious fluid resuscitation followed by an emergent laparotomy. Malrotation without volvulus is a relatively nonemergent condition that allows more time for preoperative decision making.

The operative management (Ladd procedure) of malrotation involves six principles. These can be applied to those with uncomplicated malrotation as well as to those with midgut volvulus.

#### ***Evisceration***

Generally a supra-umbilical transverse incision is made. The bowel is eviscerated and the malrotation is confirmed (Fig. 58.2). Ascites (chylous from obstruction or bloody from necrosis) is frequently encountered and drained.

#### ***Untwisting of the Volvulus***

The volvulus is untwisted by rotating it counterclockwise. If there is no bowel compromise, the operation is continued. If the bowel is edematous and hemorrhagic, improvement may occur with untwisting. If the bowel appears necrotic or nonviable, a second look operation 24-36 hours later may help to determine viability and preserve bowel.

#### ***Division of Ladd’s Bands***

Ladd’s bands create a duodenal obstruction as they pass over the malpositioned second and third portion of the duodenum. These peritoneal folds are divided freely mobilizing the cecum.

#### ***Widening the Mesenteric Base***

After untwisting the volvulus and lysis of Ladd’s bands, it is generally possible to widen the base of the mesentery. This is achieved by placing the small bowel along the right gutter and positioning the colon to the left with the ileocecal valve facing in the opposite direction.

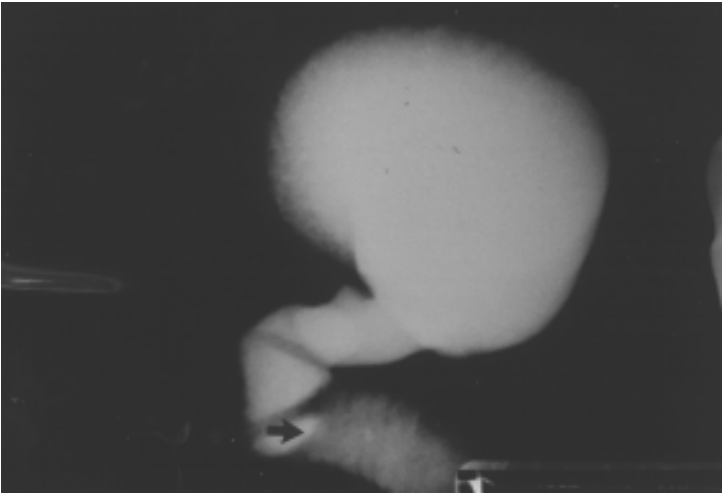


Fig. 58.1. Upper gastrointestinal series x-ray demonstrating failure of the duodenum to complete rotation and reach a proper position in the left upper quadrant at the ligament of Trietz.

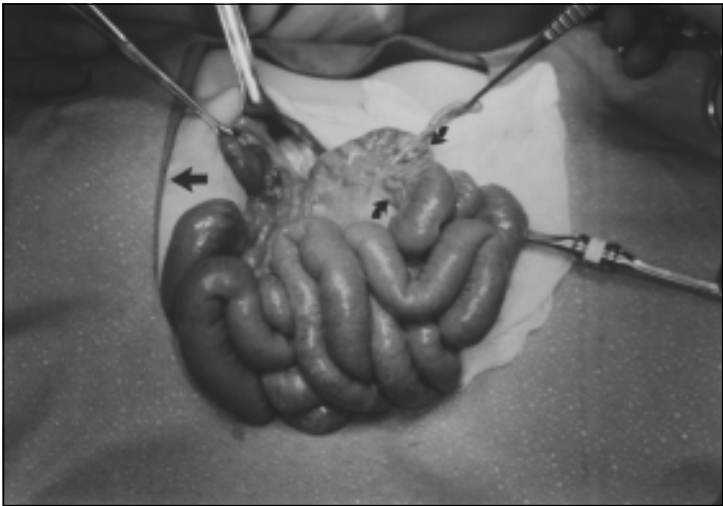


Fig. 58.2. Intraoperative photograph of malrotation. Large arrow indicates the cephalad direction. Smaller arrows demonstrate the backward orientation of the ileocecal valve with the cecum and appendix clearly unfixed and in the wrong position.

### ***Relief of Duodenal Obstruction***

Lysis of Ladd's bands will relieve most obstructions but occasionally further dissection is needed to fully mobilize and straighten the duodenum. In addition, intraluminal duodenal obstruction (i.e., atresia, stenosis) may coexist and must be identified and corrected. A soft tube can be passed through the bowel along its entire length to verify its patency.

### ***Incidental Appendectomy***

Since the colon and the attached appendix generally lie in an abnormal position both before and after an operation for malrotation, it is advisable to remove the appendix to prevent confusion if the child were to develop appendicitis in the future.

### **Outcomes**

Recurrent volvulus has been reported in up to 10% of children having the Ladd procedure. In addition, these children have the 5-6% chance of postoperative bowel obstruction secondary to adhesions. Complications of atelectasis, wound infection, postoperative bleeding, and prolonged ileus are all common. Many children have protracted hospital stays, particularly if a volvulus progressed to long segments of intestinal necrosis requiring resection. In fact, 18% of children with short bowel syndrome have this condition secondary to malrotation with midgut volvulus. In children who present with peritonitis, shock and sepsis, multiple organ failure with death may occur despite aggressive resuscitation and surgical intervention.

### ***Selected Readings***

1. Ladd WE. Congenital Obstruction of the Duodenum in Children. *N Engl J Med* 1932; 206:277-283.
2. Touloukian RJ, Smith EI: Disorders of Rotation and Fixation. In: O'Neill, Jr. JA et al, eds. *Pediatric Surgery*, 5th Edition. St. Louis: Mosby 1998; (2)1199-1214.
3. Snyder WH, Chaffin L. Embryology and pathology of the intestinal tract: Presentation of 48 cases of malrotation. *Ann Surg* 1954; 140:368.

# Atresia and Stenosis

*P. Stephen Almond*

## Incidence

Jejunal atresia is the most common gastrointestinal atresia and occurs in about one per 2,000 live births.

## Etiology

In, 1955 Louw and Barnard presented convincing evidence that small bowel atresias were secondary to an in-utero occlusion of all or a portion of the blood supply to the small bowel, i.e., the superior mesenteric artery. The affected bowel scars down to a fibrotic remnant or may be totally reabsorbed.

## Pathology/Pathophysiology

The bowel is shortened in all but type I lesions. Peristalsis in the proximal, bulbous tip may be abnormal. Bowel proximal and distal to the atresia may be deficient in acetylcholinesterase activity and cholinergic ganglia. The muscle layers are often replaced with scar tissue.

## Classification and Staging

Four types of atresias have been described. In type I, continuity of the bowel wall is preserved with obstruction being caused by an intraluminal diaphragm or 'windsock' of mucosa. This accounts for about 20% of atresia. In type II, continuity of the bowel wall is preserved only by a solid cord of tissue between the proximally dilated and distally collapsed bowel. This accounts for 35% of atresias. Type III (Fig. 59.1) has been divided into types IIIa and IIIb. In type IIIa, a portion of bowel and its associated mesentery are missing leaving two blind ends of bowel. Type IIIb is characterized by an extensive loss of small bowel and a large mesenteric defect. The blood supply for the remaining small bowel is supplied retrograde by the ileocolic artery. As there is no mesentery, the bowel spirals tightly around this artery giving the appearance of a spiral staircase or 'apple peel.' Multiple atresias are classified as type IV.

## Clinical Presentation

The infant is usually referred to a pediatric surgeon within the first 24-48 hours of life with bilious vomiting, abdominal distention, and failure to pass meconium (70%). The differential diagnosis includes meconium disease, Hirschsprung's disease, small left colon syndrome, malrotation, and intussusception. Conditions

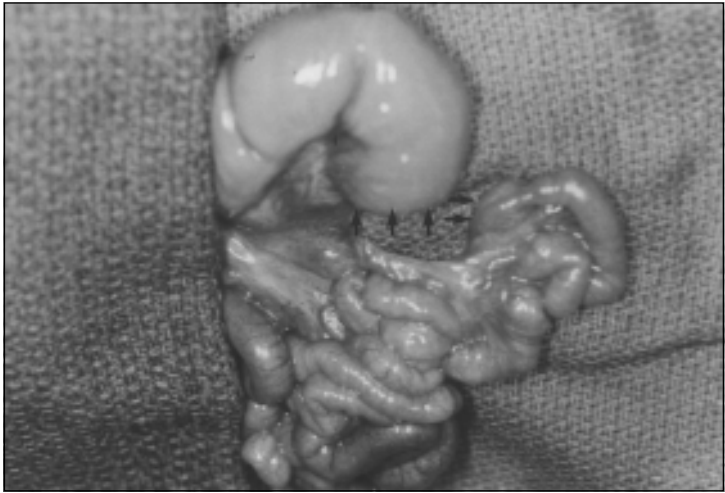

Fig. 59.1. Intraoperative photograph of a jejunal atresia, type III, with muscular discontinuity and mesenteric loss. Three arrows demonstrate the bulbous end of the proximal atresia, while two arrows show the resumption of the bowel beyond the segment of loss.

associated with jejuno-ileal atresia include other intestinal atresias (10-15%), Hirschsprung's disease (xx%), biliary atresia, polysplenia syndrome (situs inversus, cardiac anomalies, biliary atresia, intestinal atresia), and cystic fibrosis (10%).

### Diagnosis

In jejunal atresia, abdominal films show dilated loops of bowel with air fluid levels. If perforation has occurred, free air and/or peritoneal calcifications may be present (12% of cases). Barium enema demonstrates a small unused colon and often shows reflux of contrast into a collapsed terminal ileum.

### Treatment

The infant should be placed under a radiant warmer until normothermic. A nasogastric tube and IV are placed and the infant is resuscitated with boluses (20 cc/kg) of normal saline until an adequate urine output (2 cc/kg/hr) is achieved. A hemoglobin, capillary blood gas, and blood crossmatch are sent to the lab. After these things are done, the infant may be taken to the radiology suite for diagnostic studies as indicated.

At operation, a supraumbilical, transverse incision is made. The duodenum is identified and the dilated small intestine is followed to the point of obstruction. The distal bowel is then opened and irrigated to rule out distal atresias. The colon, spleen, and biliary tree are likewise inspected to rule out associated atresias, polysplenia or asplenia syndromes, and biliary atresia. If possible, the dilated bulbous tip should be resected or tapered and intestinal continuity re-established with primary anastomosis.



Postoperatively, the infant should be maintained on peripheral hyperalimentation, nasogastric suction, and antibiotics. All patients should be tested for cystic fibrosis at least twice. If bowel function does not return in a timely fashion, the possibility of Hirschsprung's disease or missed atresia should be considered.

### **Outcomes**

Survival in infants with jejunal atresia is greater than 95%.

### ***Selected Readings***

1. Dalla Vecchia LK, Grosfeld JL, West KW et al. Intestinal atresia and stenosis: A 25-year experience with 277 cases. *Arch Surg* 1998; 133:490-497.
2. Janik JB, Wayne ER, Janik JS et al. Ileal atresia with total colonic aganglionosis. *J Pediatr Surg* 1997; 32:1502-3.
3. Rescorla FJ, Grosfeld JL. Intestinal atresia and stenosis: analysis of survival in 120 cases. *Surgery* 1985; 98:668-675.

# Meconium Ileus

*Vinh T. Lam*

Meconium ileus is one of the common causes of intestinal obstruction in the newborn. It specifically refers to the distal small intestinal obstruction caused by inspissated meconium in newborns. Approximately 80-90% of these infants will have cystic fibrosis (mucoviscidosis). Meconium peritonitis occurs when meconium ileus is complicated by volvulus and/or perforation. The clinical features and presentation of meconium ileus in the newborn can be quite variable.

## Incidence

The incidence of cystic fibrosis ranges from 1 per every 1000-2000 live births. The genetic defect is transmitted as an autosomal recessive trait; the carrier rate among Caucasians is about 5-6%. Cystic fibrosis much more rarely occurs in children of African or Asian descent. Meconium ileus occurs in 10-20% of infants with cystic fibrosis.

## Etiology

Cystic fibrosis results from a mutation of the cystic fibrosis gene located on the long arm of chromosome 7. Although many types of mutations have been identified, nearly 70% of these patients have a 3-base deletion called the  $\Delta F508$  mutation. The cystic fibrosis gene encodes for a cAMP-activated chloride channel protein that helps regulate fluid balance across the apical surface of epithelial cells in many organs. Ninety percent of children with cystic fibrosis will have pancreatic enzyme deficiency and/or abnormal meconium composition. However, this meconium abnormality is sufficiently severe in 10-20% of affected neonates to produce tenacious, thick meconium that adheres to the distal ileal mucosa, producing distal intestinal obstruction.

## Pathology/Pathophysiology

The protein concentration in the meconium of normal infants is about 7%. In neonates with cystic fibrosis and meconium ileus, the protein content is nearly 80-90%. The abnormally viscous meconium results from both abnormal secretions (pancreatic and intestinal) as well as abnormal proximal small intestinal concentrating mechanisms. Infants with cystic fibrosis and meconium ileus have mild pancreatic disease but intestinal glands are severely affected. The intestinal glandular abnormality may be the primary pathologic entity leading to the development of meconium ileus.

In utero, the highly viscous, thick meconium adheres to the ileal mucosa and inspissated “putty-like” pellets form within the lumen obstructing the terminal ileum and proximal colon. The ileum proximal to the obstruction dilates to several centimeters, while the entire colon distal to the inspissated meconium is small in caliber (microcolon). The dilated, meconium-filled ileal segment is prone to volvulus.

## Classification

Meconium ileus is classified as simple (uncomplicated) or complicated. In simple meconium ileus, the abnormal meconium causes distal intestinal obstruction secondary to inspissated “pellets” at the terminal ileum. The “pellet”-containing ileum is small in caliber while the proximal ileum is dilated. Microcolon is also present.

Complicated meconium ileus is believed to be the result of volvulus in the proximal dilated intestinal segment. As with other forms of volvulus, intestinal ischemia, necrosis, or perforation can occur. Depending upon the timing and evolution of the volvulus, complicated meconium ileus may result in intestinal atresia, perforation(s) and meconium peritonitis with ascites. If perforation occurs after birth, bacterial peritonitis can occur.

## Clinical Presentation

Infants born with meconium ileus generally present with three cardinal signs:

1. generalized abdominal distention developing within the first 24-48 hours of life,
2. initially clear then bilious emesis/gastric aspirate, and
3. failure to pass meconium in the first 24-48 hours.

Maternal polyhydramnios occurs in about 20% of cases. A family history of cystic fibrosis is present in 10-30% of cases. In both simple or complicated cases, some of these infants tolerate feedings for several hours before signs and symptoms of bowel obstruction or perforation develop. Infants with complicated meconium ileus tend to develop symptoms earlier. Many present shortly after birth with severe abdominal distention, bilious emesis, and occasionally respiratory distress. Hypovolemia and hemodynamic instability are also common presenting features of complicated meconium ileus.

Physical examination reveals a distended abdomen. At times it is possible to palpate meconium-impacted bowel in the right lower quadrant that feels “doughy” or “rubbery.” In female babies with meconium peritonitis, meconium can occasionally be observed in the vagina having passed through the fallopian tubes and uterus. In boys with meconium peritonitis, the scrotum may appear black as a result of meconium passing through a patent process into the scrotum. Meconium in the scrotal sac as in the peritoneal cavity may be calcified.

The differential diagnosis includes the many causes of neonatal bowel obstruction (see Chapter 56). The most common causes of distal bowel obstruction that mimic meconium ileus are: ileal atresia, Hirschsprung’s disease, small left colon syndrome, meconium plug syndrome, and colon atresia. Sepsis also presents with abdominal distention and feeding intolerance and is included in the differential diagnosis.

Similar to meconium ileus, meconium plug syndrome is a transient neonatal colonic obstruction. Twenty-five percent of infants presenting with meconium plug

syndrome have cystic fibrosis. The other cases of this syndrome are caused by a transient motility disorder of the distal colon related to immaturity or a maternal history of diabetes (50%). All infants with this syndrome should be screened for cystic fibrosis and Hirschsprung's disease (Chapter 61).

## Diagnosis

Plain radiographs of the abdomen are necessary in cases of suspected neonatal bowel obstruction; meconium ileus is no exception. In simple meconium ileus, plain films demonstrate dilated loops with relative absence of air fluid levels (precluded by the thick, viscus meconium). A "ground glass" or "soap bubble" appearance is often appreciated in the right lower quadrant corresponding to bowel loops filled with thick meconium mixed with air. In cases of complicated meconium ileus radiographic findings may include:

1. calcifications (as a result of perforation with extravasation of meconium in the peritoneal cavity),
2. massive bowel dilation (i.e., ileal atresia),
3. mass effect (i.e., giant cyst, etc)
4. more impressive air-fluid levels, and
5. ascites.

If simple meconium ileus is suspected, barium or water-soluble contrast enema is performed to confirm the diagnosis. The contrast radiographic findings that help confirm the diagnosis include:

1. a small and unused microcolon,
2. inspissated meconium "pellets" in the terminal ileum.

Microcolon is also seen in cases of atresia with or without meconium ileus. Long segment Hirschsprung's disease and total colonic aganglionosis can frequently present with a clinical and radiologic picture identical to that of meconium ileus and should always be considered.

The chloride sweat test (pilocarpine iontophoresis) is a simple noninvasive test that is used to identify infants with cystic fibrosis. In this test, an electrical current is used to stimulate sweat production at a localized area of skin treated with pilocarpine. The sweat is collected and the chloride content is measured. A sweat chloride level above 60 mEq/L identifies neonates with cystic fibrosis with high accuracy. The test should be performed in neonates beyond 2-3 days of life. Genetic testing confirms the diagnosis of cystic fibrosis.

## Treatment

The initial management of neonates with bowel obstruction (i.e., meconium ileus) includes resuscitation with intravenous fluids, stomach decompression with a gastric tube, and administration of broad spectrum antibiotics. Simple meconium ileus can frequently be managed nonoperatively with gastrograffin enemas performed in the radiology suite under fluoroscopic guidance. Dilute gastrograffin (3:1 or 4:1 water to gastrograffin) is a contrast agent that is administered per rectum and introduced into the terminal ileum. This hyperosmolar agent draws fluid into the bowel lumen effectively clearing thick, viscus, and often inspissated meconium. The gastrograffin enema may need to be repeated 2 or 3 times over a 24-72 hour period to be effective. Oral N-acetylcysteine (mucomyst) in concentrations of 5-10% can

also be given to help clear the thick meconium which usually begins to pass within 12-18 hours following enema.

Surgical intervention is required in:

1. most neonates with complicated meconium ileus, and
2. neonates with simple meconium ileus having 2 or 3 unsuccessful gastrograffin enemas. In patients with uncomplicated meconium ileus requiring surgery, the procedure is enterotomy with irrigation and removal of the obstructing meconium.

Irrigation with various solutions (i.e., saline, gastrograffin, N-acetylcysteine, etc.) is helpful to dissolve the thick inspissated meconium. The appendiceal stump is frequently the site chosen to instill these solutions and evacuate the meconium.

In neonates with meconium ileus complicated by ileal atresia or volvulus, surgical management usually includes resection of the dilated segment, distal irrigation, and primary anastomosis to restore bowel continuity. In cases of perforation or giant cystic meconium peritonitis, the preferred procedure is debridement, cyst resection, and temporary enterostomy. Ostomy closure is typically performed 4-6 weeks later. Other surgical options for complicated meconium ileus include the use of special ostomy procedures (i.e., Bishop-Koop, Mikulicz, Santulli-Blanc).

## Outcomes

Recent one-year survival rates for infants with simple meconium ileus are 92-100%. For infants with complicated meconium ileus, one-year survival is lower at 75-89%. Overall survival in these infants has benefited from improved long-term management of patients with cystic fibrosis. Pulmonary complications are responsible for the majority of late deaths in these children. Late complications associated with cystic fibrosis include:

1. distal intestinal obstruction syndrome (2-11%),
2. appendicitis (4-5%),
3. intussusception (1-2%),
4. rectal prolapse (11-30%),
5. colon strictures, and
6. gall bladder disease.

## Selected Readings

1. Rescorla FJ, Grosfeld JL. Contemporary management of meconium ileus. *World J Surg* 1993; 17:318.
2. Bishop HC, Koop CE. Management of meconium ileus: Resection, Roux-en-Y anastomosis and ileostomy irrigation with pancreatic enzymes. *Ann Surg* 1957; 145:410.
3. Santulli TV, Blanc WA. Congenital atresia of the intestine: Pathogenesis and treatment. *Ann Surg* 1961; 154:939.
4. Ziegler MM. Meconium ileus. *Curr Prob Surg* 1994; 31:736.
5. Rescorla FJ. Meconium ileus. In O'Neill Jr. JA et al, eds. *Pediatric Surgery*, 5th Edition. St. Louis: Mosby 1998; 1159-1171.

# Hirschsprung's Disease

*Robert M. Arensman*

Hirschsprung's disease or congenital megacolon is a developmental anomaly caused by migratory failure of neural crest cells. When these primitive neurogenic cells fail to take up positions in the submucosal and intermyenteric plexi of the bowel from lips to anus, motility disturbances result that most routinely present as chronic constipation in a newborn child.

## Incidence

Incidence is approximately 1:5000 live births with males affected four times as frequently as females (4:1 males to females).

## Etiology

Reasons for migratory failure are unknown. Nevertheless, the pattern of neural crest migration with localization in parasympathetic plexi from the proximal bowel to the distal bowel is well described. Characteristically, the distal extent of migration in children with Hirschsprung's disease is the rectosigmoid region. However, females and children with Down's syndrome often have longer segments of aganglionosis. Cases of total colonic aganglionosis and very rarely extensive small bowel aganglionosis are well reported.

Familial occurrence can be documented in 3-30% of reported cases, with a greater familial incidence in longer segment disease. Chromosomal mutations have been identified on chromosomes 10 and 13 in some families.

## Clinical Presentation

Ninety-eight percent of babies pass meconium within 24-48 hours of birth. In babies with Hirschsprung's disease 90% fail to achieve this passage. The disease progresses to abdominal distension, bilious vomiting, and possibly obstructive enterocolitis.

If a neonate leaves the hospital without diagnosis, he will generally reappear with chronic constipation within two years. This constipation often accompanies a dietary change such as the change from breast milk to formula or formula to solid foods. Rarely, children escape diagnosis until more advanced ages when chronic constipation and failure to thrive are seen.

The most common physical findings are abdominal distension, visible bowel loops with peristalsis, and poor muscle development secondary to poor nutrition. Rectal examination reveals a spastic rectum with little or no stool since the stool bolus is high and beyond the examining finger.

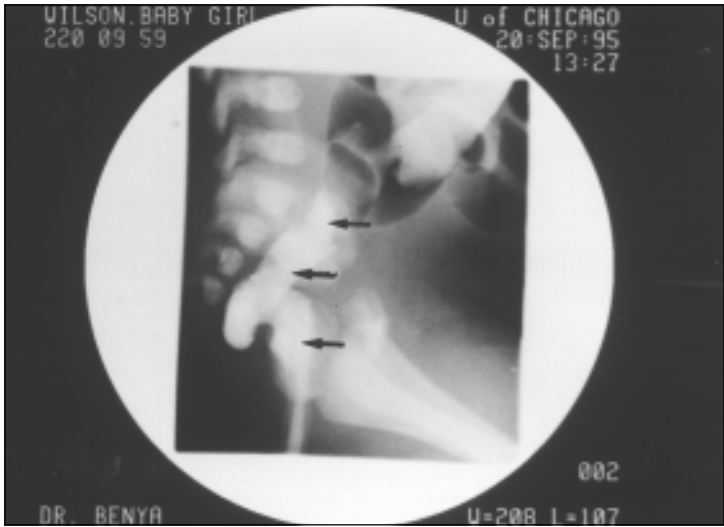

Fig. 61.1. Lateral radiograph of the rectum from a neonatal barium enema demonstrating the narrow caliber rectum and sudden transition to dilated colon.

Examination should include a check for associated syndromes: Down's syndrome, trisomy 18, Waardenburg syndrome, von Recklinghausen's syndrome, type D brachydactyly, and Smith-Lemli-Opitz syndrome.

### Diagnosis

When history and physical exam suggest Hirschsprung's disease, diagnosis has always rested on barium enema, anorectal manometry, and rectal biopsy. The first two can suggest the diagnosis but only the biopsy can conclusively confirm the diagnosis.

Barium enema reveals a spastic, poorly compliant rectum with eventual passage through a cone shaped transition zone into dilated colon (Fig. 61.1). These findings are often more apparent in older children who have had sufficient time to develop greater dilation. Delayed films often reveal slow clearance of contrast and may reveal the cone shaped transition zone better than the retrograde injection (Fig. 61.2).

In normally innervated colon, distention of the rectum produces reflex relaxation of the internal sphincter which is easily assessed with diagnostic manometry. Failure to demonstrate this normal reflex strongly suggests Hirschsprung's disease although the accuracy in neonates is an unsettled controversy at the present time.

Rectal biopsy (suction for neonates and infants; punch or strip for older children) demonstrates absence of ganglion cells and nerve hypertrophy in patients with Hirschsprung's disease. Special stains can further delineate acetylcholinesterase activity in abnormal quantities or a variety of neuronal markers. Biopsies can be repeated internally to establish the exact length of the aganglionic segment.

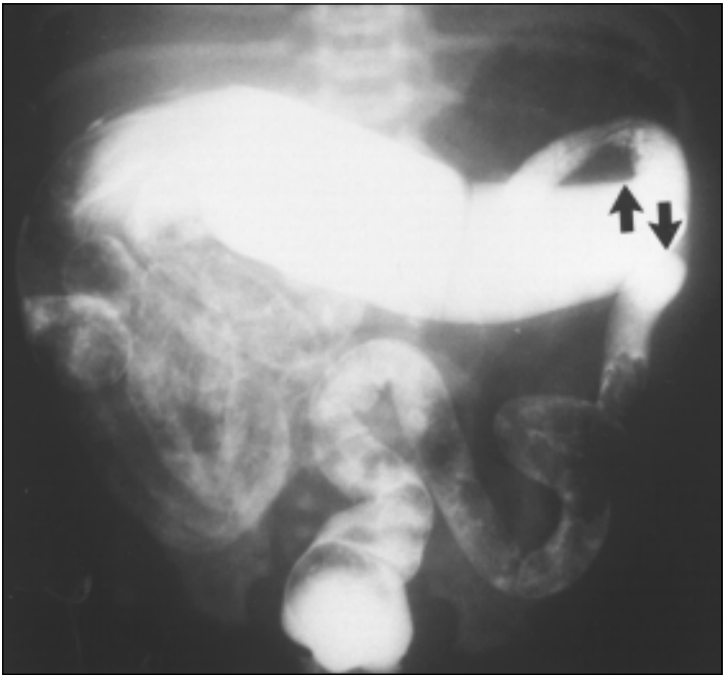


Fig. 61.2. Transition zone at splenic flexure demonstrating the change from bowel with ganglionic cells to the aganglionic distal segment.

### Pathophysiology

Long-term obstruction produces colonic dilation, often poor nutritional absorption or utilization, occasional small bowel dilation, and rarely vomiting. The result is a “sickly” child who fails to do well socially or educationally. In 20-40% of children with Hirschsprung’s disease, an obstructive enterocolitis develops: fever, vomiting, severe diarrhea, shock and sepsis. Mortality is high in this group of children despite aggressive resuscitation and antibiotics.

### Treatment

Suction rectal biopsy is the first treatment modality since it establishes the diagnosis and allows further and definitive therapy. If the child has passed the neonatal or infant period, it may be necessary to do a punch or strip biopsy to obtain a sufficiently deep specimen to make the diagnosis of aganglionosis.

Historically, these children were managed with initial colostomies in a normal piece of bowel followed by reconstructive surgery when they were older and larger. Today neonatal repair has been demonstrated safe and effective without use of an antecedent colostomy. Children first seen as older individuals can be managed by rectal irrigation and primary repair if the colon is not massively dilated. In that case,



a decompressing colostomy followed by elective repair after regression of colon size remains the best alternative.

Colonic pull down procedures of slightly different variation are the current definitive therapy. All have slight advantages and disadvantages but have been shown to give good, reliable and repetitive results. In all operations the goal is to eliminate or greatly reduce the aganglionic portion of bowel while bringing a piece of normal bowel close to the anal sphincter. Recent advances have allowed most of these procedures to be performed laparoscopically as well as via laparotomy.

In cases of total colonic aganglionosis, procedures similar to those used for inflammatory bowel disease have been used with fair results to achieve bowel function, continence, and sphincter control.

### *Selected Readings*

1. Sherman JO, Snyder ME, Weitzman JJ et al. A 40 year multinational retrospective study of 880 Swenson procedures. *J Pediatr Surg* 1989; 24:833.
2. Nixon HH. Hirschsprung's disease: progress in management and diagnosis. *World J Surg* 1985; 9:189.
3. Swenson O, Sherman JO, Fisher HG. Diagnosis of congenital megacolon: an analysis of 501 patients. *J Pediatr Surg* 1973; 8:587.
4. Swenson O, Bill AH. Resection of rectum and rectosigmoid with preservation of sphincter for benign spastic lesions producing megacolon. *Surgery* 1948; 24:212.
5. Duhamel B. A new operation for the treatment of Hirschsprung's disease. *Arch Dis Child* 1960; 35:38.
6. Soave F. Hirschsprung's disease: A new surgical technique. *Arch Dis Child* 1963; 39:16.

# Colonic Atresia

*P. Stephen Almond*

## Incidence

Colonic atresia is a rare disorder of the newborn. The incidence is estimated at one per every 20,000 to 40,000 live births. It is the least common intestinal atresia accounting for only 5-10% of reported cases.

## Etiology

Although the exact etiology of colonic atresia is unknown, it is believed by many to result from in-utero vascular occlusion of the large bowel.

## Clinical Presentation

Infants with colonic atresia present within the first 24 hours of life with abdominal distension, bilious vomiting, and failure to pass meconium. Intestinal loops are often both visible and palpable through the distended abdominal wall. On rare occasions, infants with colonic atresia present very ill with volvulus or with peritonitis secondary to perforation of the proximal dilated bowel.

The differential diagnosis includes malrotation with volvulus, small bowel atresia, meconium disease, and Hirschsprung's disease. Drug-induced ileus, megacystis hypoperistalsis syndrome, and hypoplastic left colon are other conditions to consider. Colonic atresia has been reported in infants with Hirschsprung's disease, small intestinal atresias, abdominal wall defects (i.e., gastroschisis, omphalocele), anorectal malformations, and other major anomalies (renal, cardiac, ocular). Polydactyly and syndactyly are also associated with colonic atresia.

## Diagnosis

Abdominal films demonstrate air-fluid levels and often a huge dilated loop just proximal to the obstruction. Barium enema shows a small unused colon that ends abruptly at the level of obstruction before refluxing in the small bowel. If associated with a small bowel atresia, the diagnosis is often not made until laparotomy.

## Classification

The classification of colonic atresias is the same as that of small intestinal atresias. An intraluminal membrane obstructing an otherwise intact colon wall is a Type I lesion. In type II lesions, the bowel segments remain connected via a cord-like band and there is no mesenteric defect. Type III atresias lack a connection between the bowel segments and often have large mesenteric defects. Atresias isolated to the

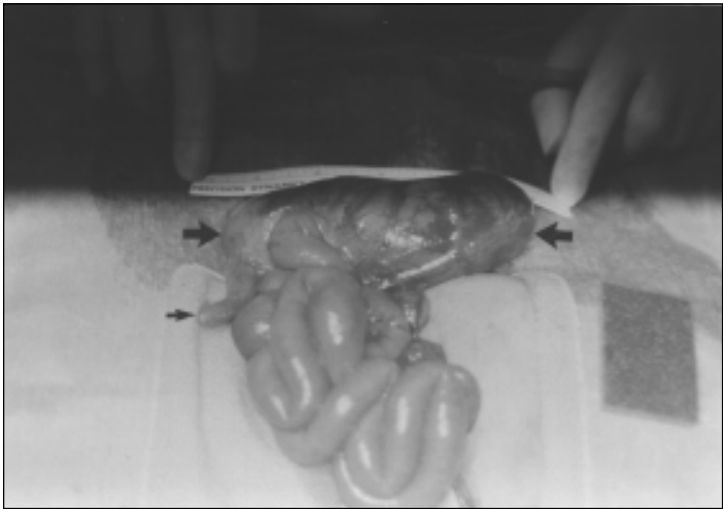


Fig. 62.1. Photograph of a child with colonic atresia. Small arrow indicates the appendix and the large arrows demonstrate the right colon with abrupt end at the hepatic flexure. Transverse and descending colon were normal and ganglion cells were present throughout (excluding Hirschsprung's disease).

colon are equally distributed by type and location. However, type III atresias are the most common lesions if ileocolonic atresias are also included. Type IV lesions contain multiple atresias.

### Treatment

The infant should be brought to the operating room euvoletic and normothermic. At operation, proximal and distal atresias should be identified (Fig. 62.1) and colonic biopsies taken to assess for the presence of Hirschsprung's disease (aganglionosis). In infants with Hirschsprung's disease, a leveling colostomy should be performed. Infants without Hirschsprung's disease can be managed in one of two ways. In one method, the proximal bulbous tip is either resected or tapered and a primary anastomosis is performed. Alternatively, an end colostomy can be performed.

### Selected Readings

1. Potts WJ. Congenital atresia of the intestine and colon. *Surg Gynecol Obstet* 1947; 85:14.
2. Powell RW, Raffensperger JG. Congenital atresia of the intestine. *J Pediatr Surg* 1982; 17:166.
3. Oldham KT. Atresia, stenosis and other obstructions of the colon. In: O'Neill Jr. JA et al, eds. *Pediatric Surgery*, 5th Edition. St. Louis: Mosby 1998; 1361-1368.

# Gastrointestinal Duplications and Mesenteric Cysts

*Riccardo Superina and Daniel A. Bambini*

## Gastrointestinal Duplications

### *Incidence*

Duplications of the alimentary tract occur infrequently. Although an exact incidence is unknown, duplications are identifiable in 1 of every 4500-5000 autopsies performed. Two types of gastrointestinal duplications exist: tubular and cystic. The tubular kind are relatively uncommon compared to the cystic type.

Gastric duplications account for only 3-4% of all gastrointestinal duplications, occur twice as often in females than males, and occur along the greater curvature of the stomach in over 50% of cases. Intestinal duplications account for 45-55% of all gastrointestinal duplications. Most occur at the terminal ileum. Duodenal duplications are slightly more common than gastric duplications representing 5-6% of the total seen. Colon duplications are the rarest reported. Rectal duplications are also exceptionally rare.

### *Etiology*

#### **Split Notochord Mechanism**

Early in embryonic life, the neurenteric canal is formed connecting the primitive neural tube with the developing intestine. During closure of the neurenteric canal, remnants of developing intestine may be deposited anywhere from the intraspinal space to the chest and abdominal cavities. Intestinal duplications originating in this fashion are usually of the tubular type.

#### **Incomplete Recanalization**

After the intestine goes through its solid phase, recanalization yields a long continuous tube. Errors in this process can leave cystic structures composed of intestinal remnants beside the normal gut. These types of duplications are usually of the cystic type.

#### **Incomplete Twinning**

Duplications of long segments of the intestinal tract can be secondary to an aborted twinning process. This type of duplication most commonly involves the hindgut causing duplications of the colon, rectum and anus.

## *Clinical Presentation*

### **Intestinal Obstruction**

Duplications most commonly come to clinical attention through the development of obstructive symptoms. Obstruction may be caused by three predominant mechanisms:

1. The mass of an expanding duplication can compress the adjacent intestine and narrow the lumen enough to cause colicky pain, vomiting and distension if low enough in the intestinal tract.
2. The duplication may act as the lead point of an intussusception.
3. The duplication may cause a segmental volvulus with closed loop obstruction.

Obstructive symptoms vary, depending on the location of the duplication and whether it is cystic or tubular. In the chest, they may cause difficulty in swallowing. Duplications should always be suspected when a child presents with a picture of intestinal obstruction if there has been no previous surgery and intussusception is ruled out.

### **Gastrointestinal Bleeding**

Tubular duplications often contain ectopic gastric mucosa. Acid secretion can cause peptic ulcers in the adjacent bowel with which they communicate. Since duplications can occur anywhere along the gastrointestinal tract, bleeding may be of the upper type with hematemesis and melena, or it can present as bright red blood per rectum. Bleeding is often very noticeable and requires transfusion of blood for patient stabilization.

### **Perforations**

Another presentation of duplications that secrete acid is perforation. Peptic ulceration and perforation of adjacent bowel occurs by a mechanism similar to gastric peptic ulcer disease.

### **Neurologic Symptoms**

Not infrequently, tubular duplications of the abdomen and chest are associated with intraspinal cysts with which they may communicate via a patent channel, or through an atretic fibrous cord extending through the adjacent vertebral body. These intraspinal cysts may also contain intestinal mucosa and cause symptoms of muscle weakness or paralysis before the extra-spinal cysts have declared themselves.

### **Asymptomatic Masses**

With the increasing use of ultrasound for the diagnosis of genitourinary symptoms, asymptomatic cystic lesions may sometimes be observed. Prenatal diagnosis of cystic lesions of the intestine is also being made more frequently.

### **Diagnosis**

A Meckel's scan is usually positive for tubular duplications that contain ectopic gastric mucosa. They appear as large areas which take up tracer and may be located in areas where a Meckel's diverticulum would not normally be found such as the chest.

Esophageal duplications, if large enough, can often be observed as posterior mediastinal radiopaque bodies on plain radiographs of the chest. Esophageal duplications are frequently associated with vertebral anomalies that if present on the plain film confirm the diagnosis. The esophageal lumen is compressed on a barium swallow study. The most definitive study is the CT scan, which can clearly outline the size, position and density of a paraesophageal mass.

Diagnosis of a duplication in the abdomen may be more difficult. Patients with intestinal obstruction by any mechanism show dilated intestinal loops and air fluid levels. Vertebral anomalies should be carefully looked for when duplications in the abdomen are suspected. Abdominal ultrasound often successfully demonstrates a fluid filled cystic duplication. Frequently, however, intra-abdominal duplications are only diagnosed at the time of laparotomy.

### *Pathology and Pathophysiology*

Intestinal duplications may contain epithelium of the bowel to which they associated, or they may contain ectopic intestinal or respiratory epithelium. Spinal cysts contain intestinal epithelium that secretes mucous. The cyst expands slowly until it causes compressive symptoms of the spinal cord. Gastric mucosa, when present, secretes acid. Normal adjacent bowel with which the duplication communicates may develop peptic ulceration with potential for bleeding or perforation.

### *Classification*

#### **Cystic**

Cystic duplications are the more common type. As their name implies, cystic duplications are rounded, hollow intestinal segments located most commonly in the distal ileum. They can occur anywhere along the intestinal tract. There is usually no communication with the adjacent bowel, so that the natural history is for the duplication to grow until it causes symptoms since there is no way for the duplication to empty. Cystic duplications usually involve only a short segment of bowel and can therefore be easily removed surgically. Cystic duplications share a muscular layer with the adjacent bowel but have a separate mucosal layer. The mucosal lining is similar to that of the adjacent bowel.

#### **Tubular Duplications**

Tubular duplications are often long segments of bowel and can occur anywhere from the esophagus to the rectum. They run parallel to the normal bowel. If they communicate with the normal bowel at the distal end, they do not distend and cause obstruction. Tubular duplications often have ectopic gastric mucosa and can present with bleeding or perforation. Tubular duplications also are commonly associated with fibrous cords to thoracic vertebrae, intraspinal cysts, and anomalies of vertebral bodies reflecting their origins in the neurenteric canal.

#### **Multiple Duplications**

Defective neurenteric canal development may result in multiple duplications in the same patient along the obliterated tract of the canal. Duplications have been described crossing from the chest into the abdomen, communicating with the gall-

bladder, or replacing most of the bowel. Symptoms can be bizarre and initially puzzling until the embryological origins of these structures is understood.

### *Treatment*

The treatment for symptomatic gastrointestinal duplications is surgical removal. Small cystic duplications can be removed quite easily with the adjoining bowel. Since intestinal duplications are situated on the mesenteric side of the intestine, it is not possible to resect them without also compromising the blood supply to the adjacent normal bowel. Removal of short segments of bowel is not usually a problem. Large esophageal duplications can be resected leaving the esophageal mucosa intact, and closing the resultant muscular defect.

Long tubular duplications can also be removed, unless the amount of adjacent bowel that has to be sacrificed is considered too much for the welfare of the patient. In these cases, the seromuscular layer of the duplication can be opened and the mucosa can be stripped from the entire length of duplication. The seromuscular cuff can be resected and closed over the area of denuded epithelium. Resection can be limited to the area where the duplication communicates with the intestine. Alternatively, the duplication and adjoining bowel can be anastomosed over a long length to ensure free drainage.

### *Outcomes*

The outcome after removal of most duplications is very favorable. When bowel loss is kept to a minimum, the effect on absorptive capacity is negligible. Major loss of bowel length occurs when the bowel is affected by very long tubular duplications, or when diagnosis and treatment is delayed with resulting ischemic loss of bowel from closed loop obstruction or intussusception.

Treatment of long tubular duplications through mucosal ablation and marsupialization of the cyst remnant is usually successful. In some cases, despite best efforts, the patient may be left an intestinal cripple and may require intestinal rehabilitation, special enteric feeds and parenteral nutrition.

Neurologic damage from intraspinal duplications is often at least partially irreversible.

## **Mesenteric Cysts**

### *Incidence*

Like duplications, mesenteric cysts are very uncommon. At least 25% of all these lesions occur in children less than 10 years old. Mesenteric cysts are responsible for about 1 of every 15,000-20,000 admissions to pediatric hospitals.

### *Etiology and Classification*

Mesenteric cysts have been classified in the past based on their presumed etiology. Mesenteric cysts can result from infectious, neoplastic, traumatic, or abnormal embryonic developmental processes. Congenital cysts are the most commonly encountered mesenteric cysts in children and are better classified based on histologic findings (Table 63.1). Approximately 90% of mesenteric cysts encountered in the neonate are lymphangiomas. Mesothelial cysts are the next most common.

**Table 63.1. Classification of mesenteric cysts by histology**

Type of Mesenteric Cyst	Histologic Findings
1. Lymphangioma	Lined by endothelium
2. Mesothelial cyst	Lined by mesothelium
3. Enteric cyst *	Lined by enteric mucosa, no muscle layers present *
4. Pseudocyst (nonpancreatic)	Fibrous wall with epithelial lining.

\* lack of muscle layer distinguishes it from intestinal duplication

### *Clinical Presentation*

Clinical presentation can be quite variable. Classically, children with mesenteric cysts present with signs of partial bowel obstruction (pain, nausea, vomiting, anorexia, distention) and have a palpable, free-moving intra-abdominal mass. Occasionally, volvulus with intestinal ischemia or infarction can occur. Symptoms may have an acute onset if rapid enlargement of the cyst occurs secondary to hemorrhage. The differential diagnosis of a mesenteric cyst includes ovarian cyst, choledochal cyst, pancreatic cyst, enteric duplication, loculated ascites, renal or splenic cyst, hydro-nephrosis, cystic teratoma, and hepatic or omental cysts.

### *Diagnosis*

Radiographic studies are helpful to confirm the diagnosis. Abdominal ultrasonography helps localize cystic lesions within the abdomen and can determine whether they are complex or simple, unilocular or multilocular, and single or multiple.

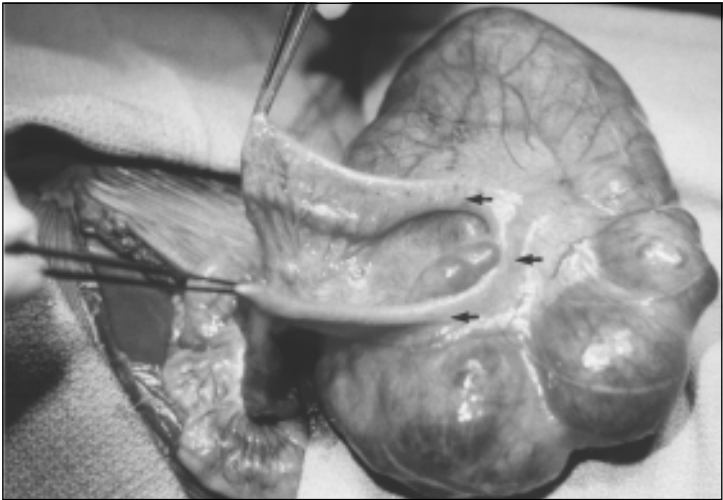


Fig. 63.1. Arrows demonstrate bowel path across the superior aspect of a large, multiloculated mesenteric cyst.



Most mesenteric cysts are single and multilocular (Fig. 63.1). CT scan does not add much additional information but occasionally can exclude other abdominal organs as the source of the cystic mass.

### *Treatment*

The treatment of mesenteric cysts is complete resection. Bowel resection may be required in over 50% of children. If complete resection is not possible, partial excision with marsupialization of the remaining cyst remnant with sclerosis of the lining may prove successful. Partial excision alone is associated with a high recurrence rate.

### *Outcomes*

Recurrence rate after resection is around 6-13%. Mortality is extremely rare and generally associated with cysts complicated by volvulus and ischemic bowel necrosis.

### *Selected Readings*

1. Bond SJ, Groff DB. Gastrointestinal duplications. In: O'Neill Jr. JA et al, eds. *Pediatric Surgery*, 5th edition. St. Louis: Mosby 1998; 1257-1267.
2. Grosfeld JL, O'Neill JA, Clatworthy HW. Enteric duplications in infancy and childhood: an 18-year review. *Ann Surg* 1970; 172:83.
3. Norris RW et al. A new surgical approach to duplications of the intestine. *J Pediatr Surg* 1986; 21:167.
4. Ricketts RR. Mesenteric and omental cysts. In: O'Neill Jr. JA et al, eds. *Pediatric Surgery*, 5th edition. St. Louis: Mosby 1998; 1269-1275.
5. Chung MA et al. Mesenteric cysts in children. *J Pediatr Surg* 1991; 26:1306.

## **Section VIII: Peritonitis in Infancy**

# Necrotizing Enterocolitis

*Fawn C. Lewis and Daniel A. Bambini*

## Incidence

The incidence of necrotizing enterocolitis (NEC) in the United States is 1-3 cases per thousand live births, or 25,000 cases per year. NEC is the most serious and frequent disorder of low-birth-weight infants with an incidence of approximately 6% in infants below 1500 g. NEC is primarily, but not exclusively, a disease of premature infants born in nations with well-developed neonatal intensive care systems. Among the most developed countries, the incidence of NEC is unequal with the United States, Canada, United Kingdom, and Australia having the highest rates of disease. NEC is rare in Switzerland, Scandinavia, and Japan.

## Etiology

There is no single identified cause of necrotizing enterocolitis. Currently, there are three main factors that are present and seem to contribute to the development and progression of NEC in infants:

1. intestinal ischemia (thrombotic, embolic, or selective as in the diving reflex),
2. bacterial colonization of the intestine, and
3. substrates in the gut lumen.

Prematurity is the major predisposing factor to NEC development. Premature newborns have immature guts in which the gastrointestinal barrier defense mechanisms are limited by inadequate production of mucus, complement, immunoglobulins (i.e., IgA, IgM), and poor phagocyte function. Exposure to antibiotics, pathogenic bacteria, and formula feeds create a luminal environment suitable for bacterial overgrowth. With intestinal ischemia, bacteria breach the mucosal layer and NEC begins. Many additional factors may contribute to the development of NEC (Table 64.1).

## Classification

Necrotizing enterocolitis follows a variable clinical course. The stages of NEC are commonly classified as outlined in Table 64.2. However, clinical distinction between each stage is often difficult.

**Table 64.1. NEC associated factors or conditions**

Umbilical catheters
Hypotension
Enteral feeds
Pneumonia
Maternal cocaine use
Hyperosmolar formula feedings
Vasoconstrictive medical therapy (indomethacin)
Patent ductus arteriosus

**Table 64.2. Clinical classification of NEC and survival**

Stage	Clinical Findings	Radiographic Findings	Treatment	Survival
I: Suspected NEC	Emesis, mild distention, intolerance to feeds	Ileus pattern	medical evaluation, treat for NEC, sepsis evaluation.	100%
II: Definite NEC	Bilious emesis or gastric drain output, marked abdominal distention, occult or gross GI hemorrhage	Ileus, pneumatosis intestinalis, portal vein gas	aggressive medical resuscitation and therapy for NEC	96%
III: Advanced NEC	Bilious gastric output, abdominal distention, occult or gross GI hemorrhage, abdominal wall erythema, deterioration of vital signs, septic shock	Ileus, pneumatosis intestinalis, portal vein gas, pneumoperitoneum, ascites	Surgical	50%

### Pathology/Pathophysiology

NEC can involve any segment of the intestine, but the most commonly affected region is the ileocecal area (45%) supplied by the most distal branches of the superior mesenteric artery. Isolated small intestinal involvement is noted in 30% of cases. NEC is limited to the colon in 25% of cases, and the splenic flexure is the most common site of colonic involvement. Pan-necrosis (involvement of more than 75% of the bowel) occurs in 14-30% of cases. NEC occurs as a single continuous lesion in only about half of cases.

Grossly, the affected bowel is distended. The intestinal wall is thinned with hemorrhagic or graying areas. Subserosal or intravascular gas is observed in 50% of cases. White colored bowel indicates areas of nonperfusion. Histologically, coagulation

necrosis of the mucosa is the predominant feature. Full or partial thickness involvement of the subserosa and muscular layers is also common. Viable areas of bowel demonstrate features of acute and chronic inflammation. Granulation tissue, fibrosis, and epithelial regeneration are signs of an extended duration of injury and recovery.

### Clinical Presentation

Although the clinical presentation can be quite variable, early NEC presents as intestinal ischemia. An ileus is often present producing abdominal distention, tachypnea, lethargy, feeding intolerance, gastric distention, and bilious or nonbilious emesis. Gross or occult blood in the stool is identified in 25-55% of patients. As the disease progresses, clinical indicators of shock and sepsis become evident including temperature instability, increased lethargy, apnea, bradycardia, and oliguria. Increasing oxygen requirement and a need for intubation and mechanical ventilation are also signs of disease progression.

Abdominal exam is notable for distention, diminished bowel sounds, and tenderness. Initially the abdomen is soft but often become firm and increasingly tender with erythema, discoloration, abdominal wall edema, and crepitation. Tympany on abdominal percussion is frequently present in cases with perforation and free intraperitoneal air. Peripheral perfusion is diminished.

Laboratory testing reveals leukocytosis or leukopenia and thrombocytopenia that occur as a response to gram negative bacterial septicemia. Metabolic acidosis occurs as a result of sepsis as fluid lost into the interstitial space causes intravascular volume depletion and hypoperfusion. Prothrombin (PT) and activated partial thromboplastin time (PTT) are frequently prolonged due to disseminated intravascular coagulopathy (DIC).

### Diagnosis

The diagnosis of NEC should be suspected in premature or low birth weight infants with abdominal distention, an increasing need for respiratory support, feeding intolerance, or lethargy. Initial evaluation of an infant suspected of having NEC includes a careful physical exam, laboratory evaluation, and plain abdominal radiographs. On a flat anteroposterior view, bowel distension is the earliest and most common radiographic finding of NEC (Fig. 64.1). Intramural bowel gas (pneumatosis intestinalis) occurs in almost all patients with NEC. However, pneumatosis intestinalis is not a specific finding and has been reported in several other diseases including Hirschsprung's disease with enterocolitis, pyloric stenosis, and carbohydrate intolerance. Other plain film findings include portal venous gas, pneumoperitoneum, ascites, or fixed and persistently dilated bowel loops. Only 63% infants with intestinal perforations due to NEC demonstrate pneumoperitoneum on pre-operative abdominal films (Fig. 64.2).

### Treatment

As is true for most diseases, the best treatment is prevention. Prenatal care helps to decrease the number of premature births. NEC is rare among infants receiving breast milk, when compared to formula fed infants in the neonatal intensive care unit. The frequency of NEC in babies whose feeding schedule is advanced quickly is not different from that observed in infants whose feedings are advanced more slowly.

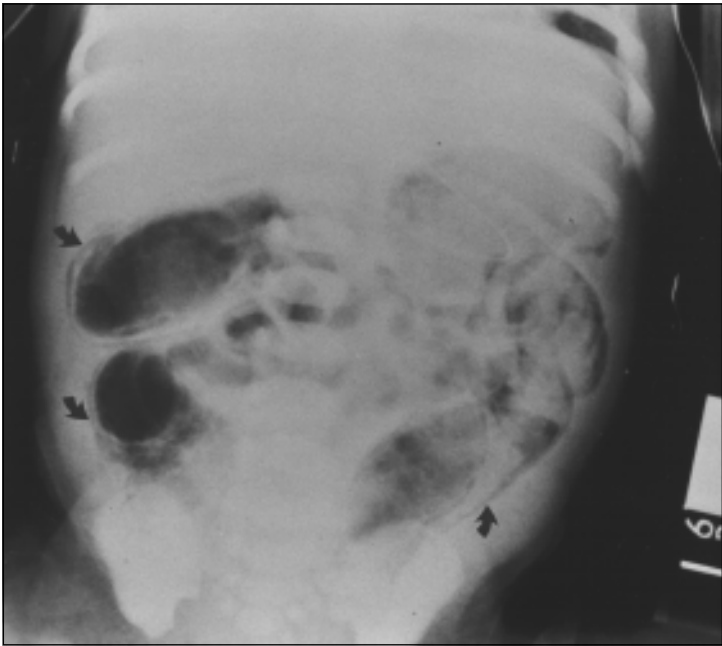


Fig. 64.1. Extensive pneumatosis intestinalis consistent with severe necrotizing enterocolitis.

---

**Table 64.3. Medical management of NEC**

---

Cultures: Blood cultures are necessary.  
Urine/sputum/CSF as indicated

---

Orogastric or nasogastric decompression of stomach.

---

Intravenous fluid resuscitation to restore tissue perfusion and renal function

---

Antibiotics: synergistic coverage for gram positives and gram negatives, with additional coverage for anaerobes. A penicillin, and aminoglycoside, and either clindamycin or metronidazole are most commonly used.

---

Correction of anemia and coagulopathy: transfuse packed red blood cells and platelets. Fresh frozen plasma is used as coagulation parameters indicate.

---

Abdominal supine and gravity-dependent (cross-table or left lateral decubitus) radiographs, repeated serially as clinical picture indicates.

---

Frequent repeat abdominal exams by the same physician at least every 6 hours until infant stable, then as clinical picture indicates.

---

Surgical intervention if the infant worsens, fails to improve on intensive nonsurgical therapy, or for advanced NEC with perforation and gangrene.

---

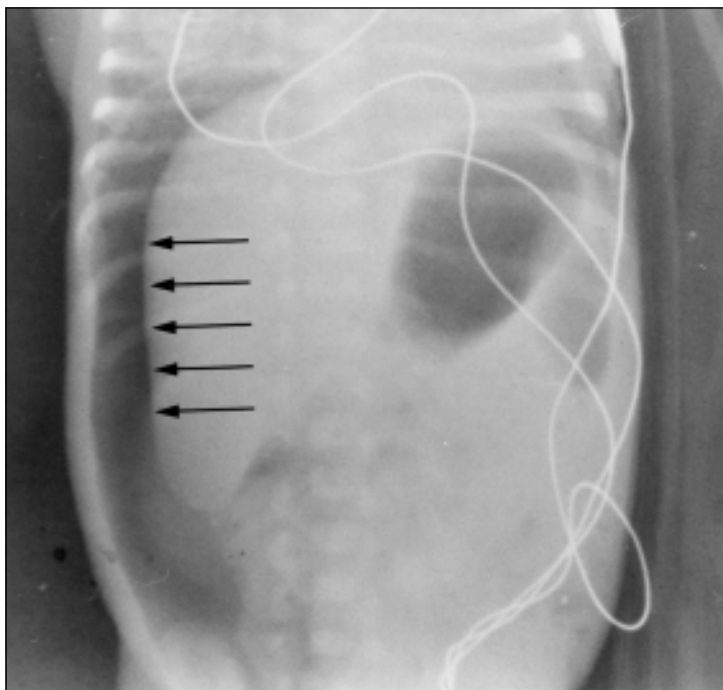


Fig. 64.2. Premature neonate (800 grams) with massive free air from necrotizing enterocolitis. Arrows outline hepatic edge on decubitus radiograph.

Medical therapy is instituted immediately once the diagnosis of NEC is suspected (Table 64.3). The goals of medical management include restoration of tissue perfusion, control of infection or sepsis, and careful observation for evidence of gangrene or perforation. An orogastric or nasogastric tube is placed to decompress the stomach and diminish further gastrointestinal distention. Aggressive volume resuscitation with isotonic fluids restores intravascular volume and helps improve organ perfusion as indicated by reversal of hypotension, oliguria, and acidosis. Because ischemic bowel sequesters large amounts of fluid in its walls and lumen, surprisingly large resuscitation volumes are often required.

Systemic antibiotics for control of bacteremia are given, targeting broad coverage of enteric bacteria (i.e., gram-positive, gram-negative, anaerobic). Many centers use ampicillin, gentamicin, combined with metronidazole or clindamycin. In some institutions with a high prevalence of coagulase negative staphylococcus, vancomycin is used to provide broader gram-positive coverage.

After initial resuscitation, surveillance includes serial abdominal exams with serial evaluation for leukopenia, thrombocytopenia, anemia, acidosis, and hypoxia. Abdominal films are repeated when there is a clinical change or increased suspicion

of gastrointestinal perforation. Indicators of intestinal gangrene or perforation and potential need for operative intervention include:

1. an inability to resuscitate the infant,
2. subsequent deterioration of vital signs and hematologic indices (i.e., thrombocytopenia, leukopenia),
3. septic shock,
4. intestinal hemorrhage,
5. increasing ascites,
6. radiographic evidence of a persistent, fixed, dilated loop of intestine and
7. pneumoperitoneum.

Of these, pneumoperitoneum is probably the only absolute indication for surgical intervention.

The morbidity and mortality of laparotomy in septic, premature neonates is high. The ideal timing of surgical intervention is often difficult to identify during the progressive course of NEC; however, it is important to operate once it is clear that a perforation has occurred. If nonsurgical therapy is ineffective after 4-6 hours of intense treatment, strong consideration for surgical intervention is warranted.

The main surgical options for an infant with NEC include:

1. peritoneal drainage,
2. laparotomy with resection and stoma(s),
3. laparotomy with resection and primary anastomosis,
4. laparotomy with proximal diversion, or
5. a combination of 1-4.

In cases of severe pan-necrosis, the surgeon (and family) may choose to explore the abdomen and close with no further surgical intervention. In this scenario, surgery is performed to confirm the diagnosis and to allow the provision of comfort care to infants with no chance of survival. The choice of procedure is individualized for each patient based on size, severity of illness, and presence of other comorbid factors (i.e., intraventricular hemorrhage (IVH), etc.). Regardless of the procedure chosen, great care is taken to minimize evaporative heat and water losses during surgery (i.e., warming pads, plastic coverings, warmed fluids, and efforts to keep the intestine inside the abdominal cavity whenever possible).

For laparotomy, the usual incision is a right-sided, transverse supraumbilical incision which allows careful examination of the entire intestine. White-appearing areas often represent full-thickness ischemic necrosis. Transparent areas of bowel indicate areas of mucosal necrosis penetrating through to the muscularis and are at high risk of perforation. Other areas of dull greenish-black or purple discolored intestine may or may not recover. Bowel segments with questionable viability are left in place and a "second look" operation is planned to re-evaluate the integrity of these segments. Frankly necrotic segments require resection. If multiple necrotic segments are resected, the surgeon must decide whether to bring out multiple stomas and/or mucous fistulas or to create distal anastomoses. This decision depends on the clinical status of the patient, the number of bowel segments, the individual bowel segment lengths, the total length of remaining viable bowel, the presence/absence of an ileocecal valve, and the ability of bowel ends to reach the anterior



abdominal wall. The length of the remaining viable intestine, its location, and the presence or absence of the ileocecal valve are carefully noted in the medical record.

Peritoneal drainage is often performed in infants weighing less than 1000 gm and in some larger infants who are physiologically unstable. A drain (e.g., penrose) is placed into the peritoneal cavity usually via a right lower quadrant incision. Some infants improve with this therapy and do not require emergent laparotomy. Approximately one third of infants with NEC and weight < 1000 gm treated with peritoneal drainage require no further surgical intervention. However, subsequent exploration may be indicated if there is no improvement.

After recovery from a NEC episode, enteral feeding is introduced slowly after about 10-14 days of medical therapy. Enteral feeds are slowly advanced toward goal rates and concentration; nutrition is supplemented by intravenous hyperalimentation (TPN) as needed. After recovery from NEC, 25% of infants develop intestinal strictures resulting from circumferential scarring of nonperforated intestinal segments. Enteral nutritional goals are frequently not met due to feeding intolerance related to post-NEC stricture formation. Strictures are usually treated surgically by resection and primary anastomosis well after the recovery phase and after significant growth has occurred.

Infants with stomas are allowed to feed and grow well before these stomas are closed. An arbitrary time or size such as two months or five kilograms is sometimes used as a goal. Intestinal continuity is restored earlier if:

1. the intestinal segment proximal to the stoma is short causing failure to thrive or difficult water and/or salt loss problems, or
2. stomal complications occur (i.e., stenosis, prolapse).

Patients with resections leaving insufficient absorptive intestinal length have short bowel syndrome (SBS) (Chapter 95) and require long-term TPN. In some of these infants, SBS is a temporary problem that resolves as intestinal length and diameter increase with age, but central venous catheter infections and complications (i.e., cholestatic liver disease, etc.) are sometimes serious, life-threatening problems.

## Outcomes

Overall survival from NEC is improving, especially in those infants weighing less than 1000 gm. Overall survival has increased from near 50% in the 1980s to approximately 80% in the 1990s. Early diagnosis and treatment are important. Infants who progress to intestinal perforations have nearly a 65% perioperative mortality, whereas infants without perforation at the time of surgery have a 30% mortality. Survival rates for surgically treated NEC are similar between infants receiving laparotomy and those receiving peritoneal drainage except in very low birth weight infants (< 1000 gm) in which laparotomy results in only a 22% survival rate compared to a 69% survival rate following peritoneal drainage.

Of infants surviving acute NEC, 25% will develop a late circumferential intestinal stricture. Recurrent NEC occurs in about 6% of infants and typically occurs 3-5 weeks after the first episode. NEC also occurs as an infrequent postoperative complication, most commonly following gastroschisis or myelomeningocele repairs. The mortality rate of postoperative NEC is 46-67%.

Significant neurological impairment is observed in 15-30% of infants that survive NEC, but this rate is similar to the rate expected in premature hospitalized infants of comparable size without NEC. Other gastrointestinal sequelae include a 10% incidence of short bowel syndrome (SBS) and malabsorption.

### *Selected Readings*

1. Bell MJ, Ternberg JL, Feigin RD. Neonatal necrotizing enterocolitis; therapeutic decisions based upon clinical staging. *Ann Surg* 1978; 187:1-7.
2. Ricketts RR, Jerles ML. Neonatal necrotizing enterocolitis: experience with 100 consecutive surgical patients. *Wld J Surg* 1990; 14:600-615.
3. Ein SH, Shandling B, Wesson D, Filler RM. A 13 year experience with peritoneal drainage under local anesthesia for necrotizing enterocolitis. *J Pediatr Surg* 1990; 25:1034-1037.
4. Morgan JL, Shochat SJ, Hartman GE. Peritoneal drainage as definitive management of perforated NEC in the very low birth weight infant. *J Pediatr Surg* 1994; 29:30-34.
5. Mollitt DL, Golladay ES. Postoperative neonatal necrotizing enterocolitis. *J Pediatr Surg* 1982; 17:757-763.
6. Grosfeld JL, Cheu H, Schlatter M et al. Changing trends in necrotizing enterocolitis: experience with 302 cases in two decades. *Ann Surg* 1991; 214:300-307.

# Gastrointestinal Perforation in the Newborn

*Daniel A. Bambini*

## **Incidence**

Spontaneous perforations of the gastrointestinal (GI) tract occur in the stomach, duodenum, small intestine or colon. The problem is encountered only infrequently; so, the exact incidence is unknown. Male infants are affected more often than females (approx. 4:1). Although neonatal gastric perforation is a well-recognized entity, other spontaneous GI perforations are much rarer and often incorrectly attributed to other disease processes (i.e., necrotizing enterocolitis).

## **Etiology and Pathophysiology**

Almost all spontaneous perforations of the GI tract are considered to be the result of ischemic necrosis. The perforation is the end result of "selective circulatory ischemia," a defense mechanism of the neonate to hypoxia, physiologic stress, and shock. Microembolic phenomena may also play a role. In response to physiologic stress (hypoxia, hypovolemia, etc.), blood is selectively shunted away from mesenteric vessels to the more vital heart and brain. Local mesenteric ischemia can progress to microvascular thrombosis and subsequent gastrointestinal wall necrosis and perforation. Although ischemia is likely the underlying problem, other factors including bacterial colonization, hyperosmolar feeds, and an immature neonatal immune system may also contribute. Indomethacin may also play a causal role in spontaneous GI perforations particularly in preterm infants as it does in the etiology of necrotizing enterocolitis. Risk factors for neonatal gastrointestinal perforation include all causes of severe fetal distress (abruption, emergent c-section, etc.).

## **Clinical Presentation**

Most infants with spontaneous gastrointestinal perforation present within the first week of life (usually 4-5 days) with an abrupt onset of abdominal distention and associated tachycardia, hypovolemia, and poor systemic perfusion. With severe pneumoperitoneum, respiratory function is compromised requiring urgent intubation. Typically, the abdomen is markedly distended and tympanitic to percussion. Pneumoperitoneum is usually present in these infants. The clinical course of neonates with spontaneous gastrointestinal perforation may mimic those of NEC or other diseases associated with perforation.

## Diagnosis

The diagnosis is confirmed by plain abdominal x-rays (flat and decubitus views) that demonstrate free intraperitoneal air. Additional laboratory evaluation includes blood cultures, blood leukocyte and platelet counts, arterial blood gases, and serum pH. Serial abdominal films are to be obtained if perforation cannot be demonstrated initially but remains highly suspected.

## Treatment

Treatment commences as soon as possible, simultaneous to the diagnostic work-up. Rapid deterioration is anticipated and prevented with aggressive fluid resuscitation, intravenous antibiotics, correction of acid-base disturbances, and nasogastric decompression. Intubation and ventilatory support is required in infants with respiratory distress. Aspiration of the massively distended pneumoperitoneum can be helpful in infants with severe life-threatening respiratory compromise. Surgical exploration is indicated. The site of perforation is identified although in up to 10% of cases the perforation site has sealed spontaneously and cannot be identified. Surgical treatment is dictated by the infants physiologic condition and the findings at laparotomy (i.e., site of perforation, tissue condition, soilage, etc) and include primary repair, resection with external diversion, resection with anastomosis, drainage, etc. Obstruction distal to the site of perforation is excluded whenever possible.

## Outcomes

Survival in neonates with spontaneous gastrointestinal perforation is approximately 30-60%. Infants with isolated stomach perforations have the best overall survival. The prognosis is adversely affected by prematurity, the presence of other anomalies, and a delay in diagnosis.

## Selected Readings

1. Grosfeld JL et al. Gastrointestinal perforation and peritonitis in infants and children: Experience with 179 cases over ten years. *Surgery* 1996; 120:650.
2. Touloukian RJ. Gastric ischemia: the primary factor in neonatal perforation. *Clin Pediatr* 1973; 12:219.
3. Rosser SB, Clark CH, Elechi EN: Spontaneous neonatal gastric perforation. *L Pediatr Surg* 17:390.
4. Weinberg G, Kleinhaus S, Boley SJ. Idiopathic intestinal perforations in the newborn: An increasingly common entity. *J Pediatr Surg* 1989; 24:1007-1008.

# Neonatal Ascites

*Vinh T. Lam and Daniel A. Bambini*

## Incidence

Ascites in the newborn is an uncommon condition that can occur as a result of three major medical problems. The exact incidence of ascites in the newborn is not known. The most common surgical conditions that lead to accumulation of fluid within the peritoneal cavity of the neonate are:

1. obstructive uropathy (urinary ascites),
2. spontaneous perforation of the biliary tree (bile ascites), and
3. lymphatic obstruction (chylous ascites).

Ascites from hepatocellular failure ( neonatal hepatitis, inborn errors of metabolism, alpha 1- antitrypsin deficiency, biliary atresia, etc.) can occur in neonates but more commonly occur in older infants and children.

## Urinary Ascites

### *Etiology*

Urinary ascites, the most common cause of neonatal ascites, usually occurs as a complication of posterior urethral valves. Other conditions that cause urinary ascites include:

1. ureteropelvic junction (UPJ) obstruction,
2. distal ureteral stenosis,
3. ureterocoele,
4. urethral atresia,
5. neurogenic bladder,
6. bladder neck obstruction,
7. ureterovesicle obstruction, and
8. spontaneous bladder rupture.

Urinary ascites rarely occurs in the absence of urinary tract obstruction.

### *Pathology/Pathophysiology*

Ascites occurs secondary to extravasation of urine from a perforation in the urinary tract with accumulation of urine in the peritoneal cavity. Perforations, most often in the upper tracts, are identifiable in about 64% and occur proximal to the urinary tract obstruction. Rupture of a dilated renal pelvis or the renal parenchyma allows a perirenal collection of urine to accumulate in the retroperitoneum. Perforation through the peritoneum allows the fluid to enter the peritoneal cavity.

### ***Clinical Presentation***

Neonates with urinary ascites are mostly males (male:female 6:1). Gross abdominal distension and ascites is usually present from birth. Abdominal distention is frequently so severe that it causes respiratory distress. Other clinical features include oliguria, hyponatremia, and hyperkalemia.

### ***Diagnosis***

Plain abdominal films demonstrate diffuse opacification with centrally located "floating" intestines. The lower rib cage may appear widened. Contrast studies may help to locate the site of extravasation. Computed tomography with intravenous contrast or intravenous pyelography (IVP) may demonstrate extravasation of contrast into the perirenal space that produces the characteristic "halo" sign. In males with posterior urethral valves, voiding cystourethrogram identifies the site of extravasation and demonstrates the underlying cause of urinary ascites.

Paracentesis returns urine. A sample is sent to the laboratory for measurement of creatinine, urea nitrogen, and potassium. All are elevated when compared to simultaneously obtained serum values.

### ***Treatment***

Large volume paracentesis is performed to relieve respiratory distress. Electrolyte and metabolic imbalances are identified and corrected appropriately. The obstructed urinary tract is decompressed by either nephrostomy or catheter drainage of the urinary bladder depending upon the level of perforation. When the general condition of the patient is satisfactory, surgical correction of the underlying cause of urinary obstruction is performed.

## **Biliary Ascites**

### ***Etiology***

Neonatal biliary ascites is a rare condition that occurs most commonly secondary to spontaneous perforation of the extrahepatic bile ducts. The site of perforation is most often at the junction of the cystic duct and the common bile duct. The etiology of spontaneous perforation is not known. Viral infections, congenital malformation, or weakness of the bile duct wall have been proposed as explanations, but the current theory suggests that vascular compromise produces an area of segmental ischemia at the junction. Rarely, distal biliary obstruction can lead to secondary perforation of the biliary tree.

### ***Pathology/Pathophysiology***

Bile leakage into the peritoneal cavity causes progressive abdominal distension and accumulation of ascites. In some cases, the bile leak may lead to diffuse peritonitis with hypovolemia and cardiovascular collapse. In other cases, a pseudocyst forms rather than generalized ascites.

### ***Clinical Presentation***

Biliary ascites usually occurs between one week and three months of age. Bile duct perforations are most frequent between the ages of 4-12 weeks. The clinical course varies between a chronic, indolent disease to one with an acute, fulminating

illness progressing rapidly to shock and cardiovascular collapse. Usually, these infants develop progressive abdominal distension, ascites, jaundice, and acholic stools. Occasionally, biliary ascites becomes infected and the infant is acutely ill with jaundice, fever, and sepsis.

### *Diagnosis*

Abdominal paracentesis is useful to make the diagnosis. The ascitic fluid has a markedly elevated bilirubin level. Hepatobiliary radioisotope scanning is an effective, accurate, and noninvasive method to make the diagnosis of biliary ascites. The isotope will collect diffusely in the peritoneal cavity rather than in the duodenum and small bowel.

### *Treatment*

The treatment of biliary ascites is surgical. Surgical therapy includes intra-operative cholangiogram performed through the gallbladder wall to identify the leak and possibly a site of biliary obstruction. Treatment options range from simple drainage to biliary diversion procedures. If the bile duct is not obstructed and simple drainage is selected, cholecystostomy is performed to provide access to the biliary tree for postoperative study. The drains remain in place until a cholangiogram demonstrates no leak or obstruction. Roux-en-Y or other biliary reconstruction is necessary in cases of distal bile duct obstruction.

## **Chylous Ascites**

### *Etiology*

Chylous ascites is caused by lymphatic obstruction. The source of lymphatic obstruction can be:

1. congenital malformation of the lymphatic ducts (39%),
2. trauma,
3. occlusion of mesenteric lymphatics by extrinsic forces (i.e., malrotation, peritoneal bands, incarcerated hernia),
4. injury to the cisterna chyli,
5. inflammation (5%), and
6. neoplasm (3%).

Congenital malformations of the lymphatics that lead to ascites include lacteal or cisterna chyli atresias, mesenteric cysts, and lymphangiomatosis. However, the exact cause of chylous ascites in many neonates is never known with certainty.

### *Pathology/Pathophysiology*

Lymphatic fluid accumulates in the peritoneal cavity causing progressively increased abdominal distention and girth. Chylous ascites becomes milky white in color after oral feeding is initiated due to high fat content.

### *Clinical Presentation*

Most of these infants present with abdominal distention and ascites at birth or within the first days of life. If a mechanical occlusion of lymphatics is present (i.e., malformation, etc), there may be symptoms of intestinal obstruction. Peripheral lymphedema of the extremities is present in 10% of newborns with chylous ascites.

### ***Diagnosis***

Abdominal x-rays demonstrate an opaque, fluid-filled abdomen with centrally located intestines. Paracentesis obtains fluid that has a high triglyceride content (> 1500 mg/dl) and high lymphocyte count (differential 70-90% lymphocytes) confirming the diagnosis.

### ***Treatment***

Chylous ascites in the newborn is usually managed nonoperatively. The majority of patients respond to gastrointestinal rest and central hyperalimentation. An enteral diet that is high in protein and contains medium-chain triglycerides is often helpful to control chylous ascites. If the ascites is severe, progressive, intractable, and compromises respiration, laparotomy is performed to exclude correctable situations. If no fixable lesion is identified, a peritoneovenous shunt can be used successfully to control ascites.

### ***Outcomes***

The outcome from treatment of neonatal ascites depends heavily upon the underlying etiology. Urinary ascites responds well to correction of the underlying urologic problem. The mortality from urinary ascites is near zero. Similarly for biliary ascites, external drainage is effective in greater than 80% and no additional surgical intervention is required. Eighty percent of bile duct perforations heal within 2-3 weeks. Unfortunately, chylous ascites does not respond so favorably. For chylous ascites, nonsurgical management is successful in 60-70% of patients. The death rate from chylous ascites is about 25-30%.

### ***Selected Readings***

1. Lilly JR, Weintraub WH, Altman RP. Spontaneous perforation of the extrahepatic bile duct and bile peritonitis in surgery. *Surgery* 1974; 75:664-673.
2. Stringel G, Mercer S. Idiopathic perforation of the biliary tract in infancy. *J Pediatr Surg* 1983; 18:546.
3. Unger SW, Chandler JG. Chylous ascites in infants and children. *Surgery* 1983; 93:455.
4. Mann CM, Leape LL, Holder TM. Neonatal urinary ascites: a report of 2 cases of unusual etiology and a review of the literature. *J Urol* 1974; 111:541.



## **Section IX: Jaundice in Infancy and Childhood**

## Biliary Atresia

*Riccardo Superina*

Extra hepatic biliary atresia (EHBA) is an acquired disorder of the bile ducts. It affects babies in the first month of life. As its name implies, it is a progressive obliterative process primarily involving the extra hepatic bile ducts. The onset of the disease is heralded by progressive jaundice which is often mistaken for hemolytic jaundice of the newborn or a breast milk induced cholestasis. It is the most common cause of obstructive jaundice in the newborn period.

### Incidence

Worldwide, biliary atresia occurs at a rate of approximately 0.8-1.0 per every 10,000 live births. Females are slightly more affected than males (female:male ratio near 1.4:1). There are no apparent racial differences in the incidence of this disease.

### Etiology

The etiology of EHBA is uncertain. There is evidence which supports a viral etiology, including the presence of giant cells and electron microscopic appearance of viral like particles in some studies. EHBA may be a part of a more global developmental disorder which is suggested by the frequent presence of associated anatomical abnormalities. The more frequent of these include venous anomalies such as preduodenal portal vein, interrupted vena cava and azygous continuation of the portal vein. Other commonly associated anomalies include polysplenia, situs inversus abdominis, and intestinal rotational anomalies. Occasionally, it has been associated with congenital absence of the portal vein. An ischemic intrauterine event which causes progressive obliteration of the extra hepatic biliary tree has been proposed as a mechanism for the occurrence of so called "correctable atresia".

The obliterative process which affects the extra hepatic ducts does not necessarily affect all the extra hepatic ducts at the same rate. The gall bladder can remain patent and communicate with an abnormal albeit patent distal duct in continuity with the duodenum, or with a patent proximal duct connected to the intrahepatic biliary tree. This does not imply that the patent ducts are normal, but that the process, which is a progressive one, has not yet reached completion.

### Clinical Presentation

Jaundice with acholic stools during the first month of life are the most common presenting symptoms. There is rarely any other significant medical history. On examination, scleral icterus and jaundice are usually obvious. Stools are pale and

colorless. The urine is usually dark. The liver may be enlarged and indurated if the diagnosis is made beyond the first eight weeks of life. Splenomegaly is another common physical finding but generally occurs quite late in the clinical course. Another late sign of EHBA is the appearance of enlarged abdominal veins signaling the onset of portal hypertension.

Jaundice secondary to EHBA in the newborn period is often mistaken for other less ominous reasons for hyperbilirubinemia. Parents may be reassured that the jaundice is a normal physiological phase even though the time is well beyond what would be considered an acceptable time period. ABO antigen incompatibility and "breast milk" jaundice are the two most common diagnostic errors. Diagnostic inaccuracy is increased when a baby has a normal period of unconjugated hyperbilirubinemia that persists beyond what would normally be considered acceptable. Any jaundice in a baby beyond 14 days of life should not be discounted as "physiologic".

## Diagnosis

Liver function tests show a conjugated or direct hyperbilirubinemia with a normal or slightly raised unconjugated fraction. Transaminase levels also show moderately raised values, usually above 100 IU/dL. Serum GGTP levels are elevated far above normal levels, consistent with an obstructive jaundice.

Ultrasonography is the principle radiologic test used to evaluate persistent neonatal jaundice. In EHBA, ultrasound findings are often limited to identifying a hypoplastic or absent gallbladder. In the early stages of the disease, before complete obliteration of the extra hepatic ducts, cystic lesions may be identifiable in the area of the hepatic hilum, leading to the erroneous diagnosis of a choledochal cyst. The spleen may be enlarged, and the liver consistency often shows increased echogenicity secondary to fibrosis. At times, ultrasonography may show no identifiable abnormalities.

Radionuclide imaging studies (HIDA or DESIDA) scans show failure of tracer excretion into the intestine after 24 hours. Failure of excretion may also be seen in cholestatic conditions such as severe neonatal hepatitis, but when it is found in combination with the appropriate clinical and biochemical profile, it is a very accurate predictor of biliary atresia. Phenobarbital given for 5 days prior to the scan may decrease the false negative rate.

A liver biopsy is an extremely accurate way of diagnosing EHBA. Typical findings include bile plugging in major bile ducts, bile ductule proliferation, and increased fibrosis (see Pathology). When all signs point to EHBA, the diagnosis is confirmed by open biopsy and cholangiogram. If the diagnosis of EHBA is entertained early, many of the diagnostic radiological and histological features may not be as well defined. Careful observation and early repetition of the tests may be necessary. Liver biopsy early in the course of the disease may show more inflammatory than cholestatic changes and may be mistaken for neonatal hepatitis. Therefore, whenever the diagnosis is considered, it must be confirmed with operative cholangiogram.

## Pathology

Histologically, EHBA is characterized by bile ductule proliferation, fibrosis originating in the portal triads, and bile plugging in the major ducts. In advanced cases there may be evidence of cirrhosis. The process may also be accompanied by a lobular

inflammatory response resulting in the formation of giant cells, syncytial giant cells, and in more severe cases, bridging hepatocyte necrosis.

### **Classification and Staging**

EHBA can be classified into two main types: correctable or uncorrectable. Correctable atresia (uncommon) can be characterized as an intact intrahepatic biliary tree and a short segment of dilated extrahepatic duct that communicates with the bile ducts in the liver but comes to an abrupt stop. Uncorrectable atresia is more common and characterized by progressive sclerosis and obliteration of the intra- and extrahepatic biliary tree. No recognizable bile ducts can be discerned at the time of exploration.

### **Treatment**

The only treatment possible is a surgical attempt at reestablishing bile drainage into the intestine. If the diagnosis is the correctable type of atresia, then a simple choledochenterostomy establishes long term bile drainage. If exploration and operative cholangiography confirms 'uncorrectable' biliary atresia, the usual course of action is to proceed with dissection of the liver hilum in order to transect proximal ductules which may still be patent and drain bile. This procedure is called the Kasai procedure after Morio Kasai who first described this dissection for the treatment of uncorrectable atresia. The fibrotic tissue, which may still contain remnants of the extra hepatic biliary tree, is dissected off the portal vein and hepatic arteries and followed up to the portal plate where it is transected. A loop of intestine (usually Roux-en-Y) is then brought to the hilum of the liver and fixed to the capsule of the liver (portoenterostomy). Following portoenterostomy, ursodeoxycholic acid is often started to promote bile secretion and fat-soluble vitamin supplementation is begun.

### **Outcomes**

Unfortunately, the Kasai procedure is not a cure for biliary atresia. In approximately one third of cases, no improvement in bile drainage is seen, and progressive liver dysfunction ensues. In most of these cases, liver failure or death from complications of portal hypertension takes place between the ages of one and two years.

In one third of babies, bilirubin returns to normal. Liver function tests, however, continue to demonstrate a cholestatic picture with a modest but persistent abnormality in serum transaminase values. Serum bile acids are also elevated above normal values. These children may demonstrate relatively normal growth and development for indefinite periods of time. Portal hypertension may develop despite normal synthetic hepatic function and has to be addressed if complications develop.

One third of children have an improvement in serum bilirubin after portoenterostomy but jaundice persists. These children may have a few years of relative good health, but liver function deteriorates progressively and death ensues from liver failure in early childhood.

Cholangitis is a frequent complication following portoenterostomy and requires admission and treatment with broad-spectrum intravenous antibiotics. Frequent episodes of cholangitis may cause deterioration in children who have achieved good biliary drainage.

When bile drainage after successful portoenterostomy stops, re-exploration has been advocated to try and re-establish bile drainage. This approach has lost proponents in the era of liver transplantation because of the low chances of prolonged benefit and causes increased scarring which may further complicate transplantation.

Liver transplantation has become the treatment of choice in children with failed Kasai operations. The timing of referral for transplantation is a critical issue to ensure that children with unsuccessful operations receive transplants in a timely manner.

### *Selected Readings*

1. Kasai M et al. Surgical treatment of biliary atresia. *J Pediatr Surg* 1968; 3:665.
2. Altman RP: The portoenterostomy procedure for biliary atresia: a five-year experience. *Ann Surg* 1978; 188:357.
3. Vazquez-Estevez et al. Biliary atresia: early determination of prognosis. *J Pediatr Surg* 1989; 24:48.
4. Okazaki T et al. Long-term postsurgical outcome of biliary atresia. *J Pediatr Surg* 1999; 34:312-315.
5. Bates MD et al. Biliary atresia: pathogenesis and treatment. *Semin Liver Dis* 1998; 18:281-293.
6. Ryckman FC et al. Biliary atresia: surgical management and treatment options as they relate to outcome. *Liv Transpl Surg* 1998; 4:S24-33.

# Choledochal Cysts

*Riccardo Superina*

## **Incidence**

Choledochal cysts are one of the more common bile duct anomalies in children and occur in approximately one in 10,000 live births. Racial and geographic differences exist. The malformation is more common in areas of Asia, notably Japan. It is also more common in girls.

## **Etiology**

The cause of choledochal cysts is uncertain and several theories have been proposed. Choledochal cysts have been associated with a long common channel of the terminal bile duct and pancreatic duct, as visualized on transhepatic or retrograde studies of the common duct. A long common channel is defined as a junction of the two ducts at least one centimeter prior to the sphincter in the wall of the duodenum. This theory implies pancreatic juices with their proteolytic enzymes reflux into the distal common bile duct and weaken the integrity of the duct tissue leading to progressive dilatation and cyst formation. Common channels, however, are not detectable in all cases.

A genetic basis for the disease is possible or even likely since choledochal cysts occur in concert with other organ system dysfunction. Cysts are commonly identified in patients with congenital hepatic fibrosis, intrahepatic biliary cysts, and polycystic kidney disease.

Some choledochal cysts may occur as a result of congenital duct wall anomalies. It is likely that isolated weakening in the common bile duct wall from ischemic events can lead to duct wall outpouching. Choledochoceles may result from abnormal development of the hepato-biliary bud in the embryonic foregut.

## **Clinical Presentation**

Classically, choledochal cysts present with jaundice, right upper quadrant pain and a palpable mass. Pain is usually the predominant symptom. Jaundice with serum bilirubin levels in the 2-5 mg/dl range is also common. A mass is rarely palpable. The serum amylase or lipase levels may also be elevated in children presenting with acute abdominal pain and choledochal cysts.

Asymptomatic choledochal cysts are being identified on a more regular basis as ultrasound examination of the abdomen has become a more frequently used modality for the investigation of numerous symptoms. Children with polycystic kidney disease should have ultrasound examination of the biliary tree to rule out small or

asymptomatic choledochal cysts. Prenatal ultrasound examination can also detect cystic masses near the liver in the fetus. Infants with prenatally diagnosed choledochal cysts can be examined and evaluated in more detail after birth.

## Diagnosis

If a choledochal cyst is suspected, the diagnosis is confirmed by blood chemistry studies and abdominal ultrasonography. All liver function tests are elevated during periods of acute pain: direct hyperbilirubinemia, elevated GGT (gamma-glutamyltransferase), and modest elevation of transaminase values. Serum amylase and lipase can be elevated if there is an accompanying pancreatic inflammation.

Abdominal ultrasound is the imaging test of choice for making the diagnosis of choledochal cyst. A cystic dilatation of the common bile duct and gall bladder is the most common finding. The dilatation can extend into the common hepatic duct, but typically does not extend into the hepatic ducts.

Idiopathic pancreatitis with secondary biliary duct dilatation can be confused with choledochal cysts. Continued observation in cases of pancreatitis will often demonstrate resolution of the ductal dilatation, whereas true choledochal cysts will not resolve spontaneously.

## Pathology

Examination of the cyst wall demonstrates chronic inflammatory changes and often complete denudation of the epithelium. In undiagnosed or incorrectly treated cysts, chronic epithelial inflammation rarely leads to malignant degeneration. Cholangiocarcinoma has been reported in choledochal cysts first diagnosed in adults and in cyst remnants not resected after childhood diagnosis. The usual malignancies are adenocarcinoma or small cell carcinoma.

## Classification

### *Type 1*

This is by far the most common form of cyst (Fig. 68.1). It involves most of the common bile duct, cystic duct, gall bladder and common hepatic duct. Type 1 choledochal cysts do not typically extend into the hepatic ducts. They frequently communicate with the duodenum through a lumen so small that it can barely be perceived at surgery. These cysts are sometimes subclassified as either cystic (Type 1c) or fusiform (Type 1f).

### *Type 2*

This type of cyst is an outpouching or diverticulum of the common bile duct, involving all layers of the duct wall. It typically involves a short segment of an otherwise normal duct. It does not affect the gallbladder. It is extremely rare.

### *Type 3*

This type is called a choledochoceles and is located at the distal end of the common duct. Often it is completely contained within the duodenal wall. It causes obstruction through compression of the normal duct and is sometimes considered a duplication cyst. The rest of the ductal system is normal.

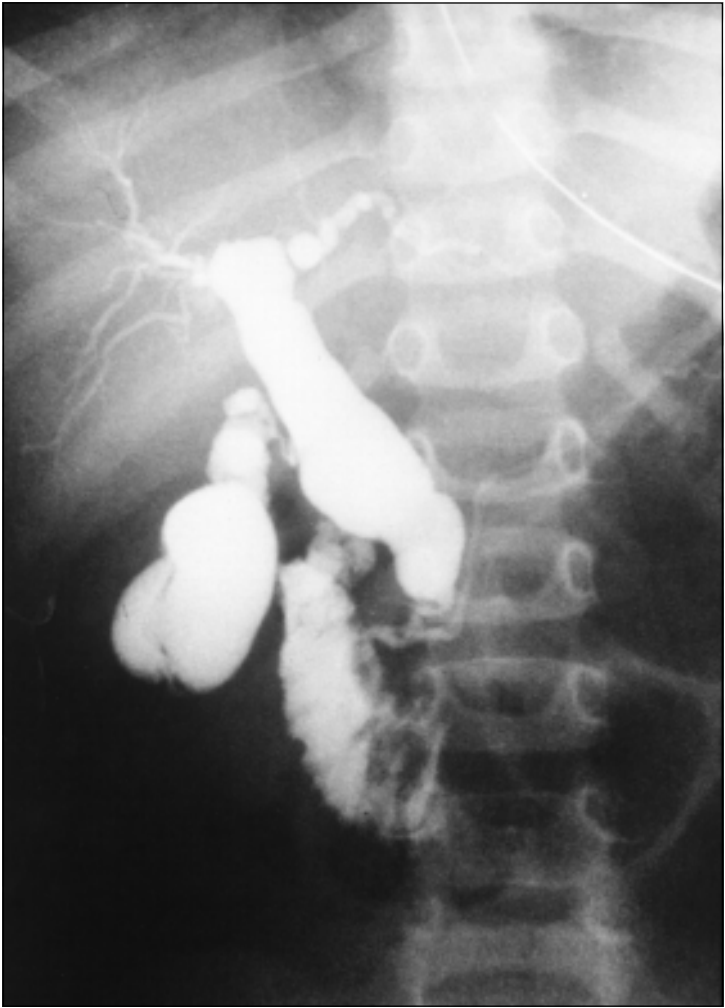


Fig. 68.1. Demonstration of the most common type of choledochal cyst (type 1): a fusiform dilation of the common and common hepatic ducts with only minor dilation of the intrahepatic ducts.

#### *Type 4*

This cystic lesion involves both the intrahepatic and extrahepatic biliary system. The intrahepatic portion consists of areas of normal ducts interspersed with areas of saccular dilatation.



### *Type 5*

Type 5 lesions are single or multiple intrahepatic biliary cysts. There is no extrahepatic component in this type. The intrahepatic biliary cysts may be localized to one lobe or segment, but it is usually a bilateral, diffuse process. Type 5 (and sometimes Type 4) lesions are often called Caroli's disease, in which there are multiple, irregular segmental dilatations of the intrahepatic bile ducts. Caroli's often occurs in association with hepatic fibrosis and polycystic kidney disease. Cirrhosis and portal hypertension can develop in both type 4 and 5 lesions.

### **Treatment**

Treatment consists of cyst excision and biliary reconstruction with a Roux-en-Y choledochojejunostomy for all type 1 and type 4 cysts. In the past, anastomosis of a loop of bowel to either the gallbladder or cyst wall to re-establish bile drainage was considered adequate treatment. The realization that malignancies can develop in cyst remnants has led to the recommendation that as much of the cyst as can be safely removed be resected.

For type 2 cysts, an attempt at simple resection should be made with primary repair of the common duct. Because of the small size of the duct, postoperative strictures may complicate the recovery, but these can usually be successfully dilated.

Type 3 cysts are resected via a transduodenal approach. Alternatively, marsupialization of the cyst into the duodenum is another acceptable treatment if the cyst cannot be resected without causing further damage to the distal common duct. Leaving cyst wall remnants in type 3 cases does not seem to have the same potential for malignant degeneration as for type 1 cysts.

Type 5 (and some type 4) lesions pose a more difficult treatment problem. For intrahepatic cysts localized to one lobe or segment, hepatic resection is only rarely beneficial. Many of these patients may eventually require liver transplantation (see below).

For cases complicated by severe cholangitis and advanced inflammatory changes, cyst drainage and biliary decompression either operatively or with the assistance of an interventional radiologist may be necessary before any attempts at cyst resection.

Prophylactic cystectomy may sometimes be necessary. In patients with polycystic disease and renal failure, dealing with the cyst before renal transplantation may be wise. Development of cholangitis is more serious in an immunosuppressed host, and cyst excision before transplantation all but eliminates that possibility.

Prenatal diagnosis of choledochal cysts is becoming more common. Cysts rarely cause problems in the newborn period, and therefore it is almost never necessary to operate right after birth. A period of 4-6 weeks for observation is usually a good idea. Cysts may regress, and there is no significant risk for an acute cyst-related complication. Additionally, a waiting period allows the baby to grow and may lower anesthetic and surgical risks.

### **Outcomes**

Type 1 cysts completely excised have an excellent prognosis. Periodic evaluation of liver function tests and ultrasonographic examination of the biliary tree should be performed for the first 5 years as indicated. If everything appears normal, only rarely is additional follow-up testing needed. Type 2 and 3 cysts may have complications

of biliary strictures in the short-term postoperative period. However, long-term outlook is excellent.

The outcome for type 4 and 5 cysts is much more guarded. These children will suffer from intermittent bouts of cholangitis and experience progressive fibrosis of the liver. Ultimately, liver failure may ensue, and liver transplantation may be indicated. Further palliative surgery to improve intrahepatic strictures is rarely indicated. Radiological dilatations of dominant strictures may add years of life to children with these difficult problems and may delay the need for transplantation.

In patients with congenital hepatic fibrosis and choledochal cysts, long term problems related to portal hypertension and liver failure are likely to develop. Cystectomy may, however, significantly add to the quality of life as well as provide improved bile drainage to decrease the risk for development of biliary cirrhosis.

### *Selected Readings*

1. Todani T, Watanabe Y, Narusue M et al. Congenital bile duct cysts. Classification, operative procedure and review of 37 cases including cancer arising from a choledochal cyst. *Am J Surg* 1977; 134:263-269.
2. Caroli J. Diseases of the intrahepatic bile ducts. *Israel J Med Sci* 1968; 4:21-35.
3. Chijiwa K, Tanaka M. Late complications after excisional operation in patients with choledochal cyst. *J Am Coll Surg* 1994; 179:139.
4. Tugo-Vicente HL. Prenatally diagnosed choledochal cysts: observation or early surgery. *J Pediatr Surg* 1995; 30:1288.

## **Section X: Respiratory Distress**

# Upper Airway Obstruction in the Newborn

*Daniel A. Bambini*

The principle features of upper airway obstruction in infants are stridor and cyanosis. Neonatal airway obstruction most commonly originates in the larynx but may be caused by nasal or postnasal lesions, pharyngeal pathology, or narrowing of the trachea or major bronchi. Respiratory distress in the newborn is an acute emergency and requires rapid assessment and treatment. This Chapter discusses the features of upper airway obstruction in the neonate.

## **Incidence**

The exact incidence of upper airway obstruction in the newborn is difficult to estimate due to the large array of conditions that may cause this problem. The incidence of some of the more common etiologies are listed in Table 69.1.

## **Etiology**

Airway obstruction can occur at any level from the nose to the tracheobronchial tree. Table 1 lists the common etiologies by level of obstruction. A full discussion of the embryologic, genetic, and anatomic basis of each lesion is beyond the scope of this Chapter. Some lesions are discussed in detail within other Chapters of this book.

## **Pathology/Pathophysiology**

Newborn infants are obligatory nose breathers. Conditions that obstruct the nasal passages or pharynx cause obstructive apnea. Supraglottic lesions tend to cause inspiratory stridor, while those of the trachea or bronchi cause an expiratory or biphasic stridor. Lung lesions that cause respiratory distress usually do not produce obstructive signs. Although the severity of stridor can be mild and self-limited in many instances, severe airway obstructions may be lethal or cause hypoxic brain injury.

Stridor is the sound produced as air flows across a narrowed airway. As air flows through a tube, the lateral forces holding the tube open decrease (Venturi principle). At narrowed segments, the walls may collapse and touch causing vibration of the walls which is acoustically appreciable as a stridor. The pitch of the stridor is dependent more upon the thickness of the vibrating wall than the anatomic level of obstruction.

**Table 69.1. Causes of airway obstruction in the newborn****Nose and Oropharynx**

Nasal agenesis or atresia  
 Traumatic nasal deformities (septal hematoma or dislocation, nasal fracture, etc)  
 Stuffy nose syndrome (turbinate hypertrophy)  
 Choanal atresia (unilateral or bilateral)  
 Nasopharyngeal mass (encephaloceles, teratoma, glioma, adenoids)

**Oral Cavity and Oropharynx**

Craniofacial abnormalities (Apert's, Crouzon's, Treacher-Collins, etc.)  
 Micrognathia with glossoptosis: Pierre Robin Sequence  
 Treacher-Collins syndrome  
 Macroglossia (hypertrophy, tumor, lingual thyroid, thyroglossal duct cyst)  
 Oropharyngeal tumors (dermoid, epignathus or teratoma, tongue duplication, etc.)  
 Hypertrophy of tonsils or adenoids  
 Peritonsillar or retropharyngeal abscess/mass  
 Larynx  
 Laryngomalacia  
 Vocal cord paralysis  
 Congenital or acquired subglottic stenosis  
 Laryngeal webs (glottic, interarytenoid) or atresia  
 Neoplasms (hemangioma, lymphangioma, papillomatosis)  
 Congenital laryngeal cleft  
 Laryngeal trauma from endotracheal intubation

**Tracheobronchial Tree**

Tracheomalacia  
 Vascular rings and slings  
 Innominate artery compression syndrome  
 Tracheoesophageal fistula with esophageal atresia (secondary tracheomalacia)  
 Tracheal agenesis, webs, and stenosis  
 Compression from bronchogenic cyst, esophageal duplication, sequestration, etc

**Clinical Presentation**

The clinical presentation of an upper airway obstruction in a neonate is proportional to both the degree and anatomic level of the obstructing lesion. Cyanosis and severe respiratory distress (dyspnea, retractions, agitation, wheezing, stridor) are the hallmark signs of upper airway obstruction but are also common to the presentation of other lesions of the pulmonary, gastrointestinal, and cardiovascular systems. The first indication of a potential airway problem may be "noisy respirations" observed

by the family or nurses in the neonatal unit. The onset and duration of stridor should be documented and information regarding possible trauma, relationship to feeding, possible aspiration, or congenital malformation is noted.

Stridor that is present from birth is most often caused by congenital laryngomalacia. Considerably less likely are subglottic stenosis, vocal cord paralysis, or a vascular ring. The stridor associated with a vocal cord paralysis is frequently louder when the infant is awake.

Progressively increasing stridors may be secondary to neoplastic lesions causing gradual compromise of the airway. Subglottic hemangiomas usually occur between 1 and 3 months of age (85% before 6 months) and 50% of these infants will have associated skin hemangiomas.

## Diagnosis

After careful history and physical examination, radiographic evaluation of the upper airway is indicated. Anteroposterior and lateral plain cervical radiographs are obtained to view the soft tissues of the neck and chest. The films are obtained during inspiration if possible. Fluoroscopy is useful to localize the level of airway obstruction if inspiratory films are not obtainable. Barium swallow allows assessment of the pharynx for obstructing lesions and can identify vascular rings encroaching on the esophagus and/or trachea. Ultrasound can be useful to identify vocal cord paralysis. Computed tomography and magnetic resonance imaging are occasionally used to localize and assess size of soft tissue lesions and aberrant vessels.

Endoscopy (flexible nasolaryngoscopy, fiberoptic or rigid bronchoscopy, esophagoscopy) confirms the diagnoses suggested by radiologic studies. The pharynx, trachea, larynx, vocal cords, and bronchi are carefully visualized. Supraglottic airway collapse, vocal cord paralysis, and laryngomalacia are all best visualized in spontaneously breathing infants. In neonates with stridor, the endoscopic evaluation is most safely performed in the operating room. Resuscitation equipment, small endotracheal tubes (2.5-3.5 mm), and tracheotomy instruments should be immediately available.

## Treatment

Prior to administering anesthesia, the surgeon caring for the infant with upper airway obstruction must select proper sized equipment (bronchoscope, etc.) and be absolutely sure that all necessary equipment (suction, lenses, etc.) is functional. After careful laryngoscopy, a ventilating bronchoscope is passed through the glottis under direct vision. The identification of the lesion and its location and the ability to pass a bronchoscope are key determinants for the ability to perform safe endotracheal intubation. If bronchoscopy cannot be performed (tracheal diameter < 2.5 mm), tracheostomy or anterior cricoid split may be necessary. After intubation, other endoscopic procedures (esophagoscopy, nasopharyngoscopy, etc.) can be performed to evaluate for masses, fistulas, or foreign bodies. Postoperative care after bronchoscopy should include close observation for possible delayed swelling and/or need for intubation. Racemic epinephrine nebulizers and dexamethasone may help prevent delayed airway swelling.

The definitive treatment of upper airway obstruction is guided by the underlying etiology. A full discussion of all lesions is beyond the limits of this Chapter.

### *Selected Readings*

1. Holinger LD. Upper airway obstruction in the newborn. In: Raffensperger JG ed. Swenson's Pediatric Surgery, 5th Edition. Norwalk: Appleton & Lange 1990; 669-682.
2. Holinger PH. Neonatal respiratory tract obstruction. *Cardiopulmon Dis* 1962; 4:285.
3. Benjamin B. Airway obstruction: Part 1. Laryngeal Obstruction. In: Freeman NV et al, eds. *Surgery of the Newborn*. Edinburgh: Churchill Livingstone 1994; 409-424.

## Vascular Rings

*Robert M. Arensman*

Vascular rings and slings are a series of anatomical variations in the formation of the aortic arch, ductus arteriosus or pulmonary artery that can produce vascular compression of the trachea or esophagus.

### Incidence

These anomalies are reasonably rare and may go undetected in the general population since many are asymptomatic. The aberrant right subclavian artery is the most common sling, possibly present in 1:200 individuals. The other sling (aberrant pulmonary artery sling) and two most common forms of rings (double aortic arch, right arch with left ductus) are seen much less frequently and present for surgical correction only a few times each year, even at large metropolitan children's hospitals.

### Etiology

The cause of branchial vessel persistence or malformation is not identified, but all rings and slings represent some variation on maldevelopment of branchial vessels three, four and six. The double aortic arch forms a complete vascular ring and results from persistence of the double fourth branchial vessels. In a right aortic arch with left ductus arteriosus, the right fourth arch vessel persists rather than the left yet the ductus forms normally, encircling the trachea and esophagus.

In the aberrant pulmonary artery sling, the sixth arch vessel develops abnormally, passing over the right main bronchus between the trachea and esophagus. Normally the pulmonary artery passes in front of both and divides into its right and left branches anterior to the trachea. In cases of aberrant right subclavian sling, the third branchial vessel fails to form the typical innominate vessels. Instead, the right subclavian artery arises directly from the descending aorta, passes to the right and behind the esophagus, or very rarely between trachea and esophagus.

### Clinical Presentation

Children, 1-2 months to 2 years of age, present with biphasic stridor and/or dysphagia (dysphagia lusoria). Dysphagia occurs much less commonly than stridor. Onset of symptoms is often insidious. As the child grows, the trachea and/or the esophagus are gradually compressed producing and then worsening the symptoms.

Examination reveals stridor that is often worse with agitation or anger. Minimal respiratory infections often exacerbate the problem and dramatically worsen symptoms. An affected child may have respiratory retractions and use accessory muscles



to breathe. Signs of thinness, malnutrition or frank failure to thrive may be present if dysphagia and vomiting are severe.

Severe respiratory infections, croup, obstructing airway lesions, and gastroesophageal reflux are the most commonly considered problems in the differential diagnosis. The more bizarre forms of rings and slings have a high incidence of congenital cardiovascular anomalies that should be identified prior to an attempt at repair.

## Diagnosis

Severe and recurrent tracheal/esophageal symptoms indicate the need for chest x-ray and barium esophagram (Fig. 70.1). A characteristic set of indentations, narrowings, and deviations allow almost all these anomalies to be diagnosed with these two radiographic studies.

Arteriography is avoided because it is highly invasive, can permanently damage tiny arteries, requires dyes and radiation, and is largely unnecessary. However, magnetic resonance imaging (Fig. 70.2) and computed tomography with contrast are now frequently used and provide excellent delineation of the anatomy without invasion and with much less radiation.

Endoscopy can be done at the time of operative correction to document the degree of tracheomalacia but is not needed for diagnosis or therapy.

## Pathophysiology

Tracheal compression producing tracheomalacia and airway compromise explains the problem. Interestingly, the esophageal compromise is much less commonly seen, and most children continue to eat and thrive long after the stridor appears.

Rarely, neonates present with bilateral pulmonary hyperinflation (air block syndrome). These infants have sufficient compression to prevent normal expiration and develop a pattern of obstruction that looks like bilateral extensive congenital lobar emphysema. Intubation with tube placement below the ring will usually stabilize these neonates until surgical division is accomplished.

## Treatment

If a vascular ring or sling presents with symptoms, surgical repair is indicated. Preoperative management entails sufficient study to define the anatomy correctly and obtaining blood for type and cross-match.

Left thoracotomy is the normal approach for all these lesions except the aberrant left pulmonary artery sling which is approached via median sternotomy. For the vascular rings, division of the nondominant ring and ductus or the ductus alone usually suffices. The aberrant left pulmonary artery sling was originally repaired without cardiopulmonary bypass but today most centers would choose bypass to insure stability while the left artery is switched. Rarely aortopexy is added to more readily stabilize tracheomalacia, but this is only seldom necessary.

Families should be warned that stridor persists for 6-24 months after correction. Feeding problems, if present before surgery, abate quickly. Short and long-term outcomes are excellent in virtually all these children. Intraoperative mortality and perioperative morbidity are exceedingly low.

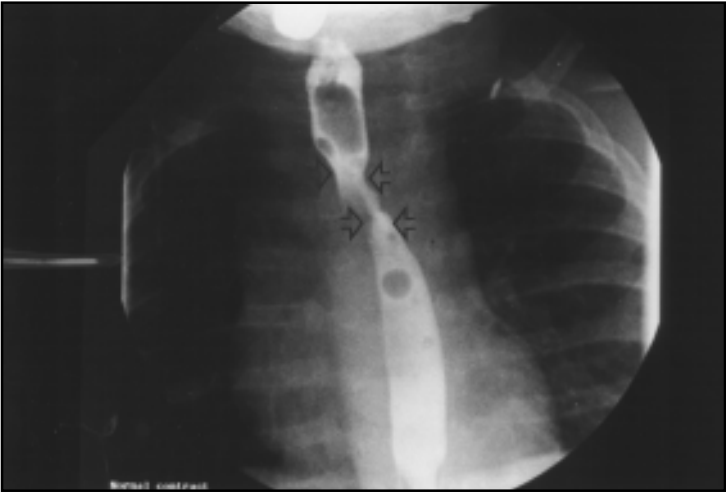


Fig. 70.1. Typical double indentation of esophagus on barium swallow in an infant with a double aortic ring. Notice that one indentation often occurs somewhat higher than the other does.

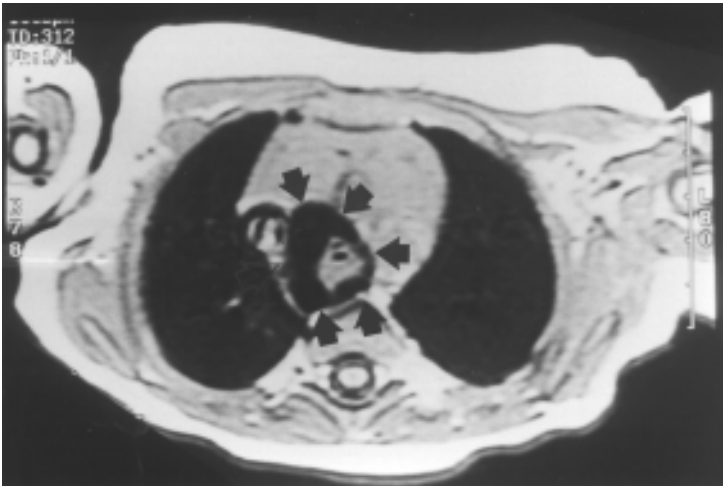


Fig. 70.2. MRI demonstrating complete encirclement of the esophagus and trachea by a double aortic ring.

*Selected Readings*

1. Gross RE. Surgical relief for tracheal obstruction from a vascular ring. *N Engl J Med* 1945;233:586.
2. Potts WJ, Holinger PH, Rosenblum AH. Anomalous left pulmonary artery causing obstruction to right main bronchus: Report of a case. *JAMA* 1954; 155:1409.
3. Nikaidoh H, Riker WL, Idriss FS. Surgical management of "vascular rings." *Arch Surg* 1972; 105:327.
4. Backer CL, Ilbawi MN, Idriss FS et al. Vascular anomalies causing tracheoesophageal compression. Review of experience in children. *J Thorac Cardiovasc Surg* 1989; 97:725.

# Tracheoesophageal Fistula and Esophageal Atresia

*Daniel A. Bambini*

## **Incidence**

The incidence of congenital tracheoesophageal malformations in the U.S. is approximately one in every 4,500 births. In some areas of the world (i.e., Finland), the incidence may be as high as one in 2,440 births. Tracheoesophageal fistula and esophageal atresia affects males slightly more commonly than females (1.26:1).

Although most cases of tracheoesophageal anomalies are sporadic, familial patterns of inheritance are reported. About 6% of infants with tracheoesophageal malformations are twins. Parents with one affected child have a 0.5-2% chance of a tracheoesophageal anomaly affecting subsequent offspring. If more than one offspring is affected, the risk is 20%. Newborns with a parent having history of TEF/EA are affected 3-4% of the time.

## **Etiology**

Although the association of this disease with many other congenital abnormalities suggests that these lesions occur after a major disturbance in embryogenesis, the exact cause remains unidentified. Environmental teratogens have been implicated but specific causal relationships are unproven. At 22-23 days of gestation, the esophagus and trachea are recognized as a common diverticulum of the foregut. Division into separate tubular structures occurs primarily in the fourth week of development and is complete at 34-36 days. Although several embryonic theories have been proposed to explain the formation of tracheoesophageal malformation, none fully explains all of the anatomic variants of the anomaly that have been described. A high incidence of coincidental anomalies suggests generalized damage to mesenchymal tissue during the 4th week of gestation.

## **Classification**

Although many anatomic variations have been described, only five types of tracheoesophageal anomalies occur commonly, accounting for 98% of the lesions encountered. The Gross-Vogt classification is the most commonly used anatomic classification system (Table 71.1). Type A lesions are isolated esophageal atresia without a tracheoesophageal fistula and are frequently associated with a "long gap" between the proximal and distal esophageal segments. Type B lesions are esophageal atresias

**Table 71.1. Anomalies associated with tracheoesophageal fistula and esophageal atresia**

Cardiovascular		35%
	Ventricular septal defect (most common), tetralogy of Fallot, atrial septal defect, patent ductus arteriosus, coarctation of the aorta (1-1.5%)	
Genitourinary		20%
	Hypospadias, cryptorchidism, renal agenesis, renal hypoplasia, cystic renal disease, hydro-nephrosis, vesicoureteral reflux, ureteric duplication, pelvoureteral or vesicoureteral obstruction, urachal anomalies, intersex abnormalities, cloacal or bladder exstrophy, megalourethra, urethral duplication, posterior urethral valves	
Gastrointestinal		24%
	Anorectal atresia, duodenal atresia, ileal atresia, malrotation, annular pancreas, pyloric stenosis	
Neurologic		10%
	Hydrocephalus	5.2%
	Neural tube defects	2.3%
	Holoprosencephaly	2.3%
	Anophthalmia or microphthalmia	2.3%
	Microcephaly	
Skeletal		13%
	Vertebral anomalies, radial limb deformities	
VACTERL association		25%
CHARGE association		3%
Choanal atresia		5.2%
Facial cleft		7.2%
Abdominal wall defect		4.3%
Diaphragmatic hernia		2.9%
Tracheobronchial anomalies		40+ %
	Unilateral pulmonary agenesis, ectopic or absent right upper lobe bronchus, congenital bronchial stenosis, decreased cartilaginous: membranous trachea ratio, laryngotracheoesophageal cleft	
Cleft lip or palate		
Deafness		
Other syndromes:	Downs syndrome, Fanconi's syndrome, Townes-Brock syndrome, Bartsocas-Papas syndrome, McKusick-Kaufman syndrome	

in association with a proximal tracheoesophageal fistula and are very rare, accounting for only about 1% of lesions. Type C lesions constitute the most common congenital esophageal anomaly (85-89%) and include a blind-ending proximal esophageal pouch with a distal tracheoesophageal fistula. In Type D anomalies, there are two tracheoesophageal fistulas, one each from the proximal and distal esophageal segments. In Type E anomalies, a tracheoesophageal fistula is present without an atresia (H-type fistula). Type F anomalies, congenital esophageal stenosis, are exceptionally rare (i.e., 1 in 25,000-50,000 births)

### **Pathology/Pathophysiology**

For most type C lesions, the proximal esophagus ends blindly with a 1-2 vertebral body gap between it and the distal esophagus (Fig. 71.1). The distal esophagus opens into trachea via an end-to-side fistula located approximately 1 cm above the carina. Rarely the fistula may be to the right or left main bronchus.

Esophageal obstruction prevents the fetus from swallowing amniotic fluid in utero. In cases of pure atresia of the esophagus, polyhydramnios is usually present (85%). Polyhydramnios is present in only about 30% of mothers with fetuses having esophageal atresia and distal TEF since the fluid can reach the neonatal gut via the fistula. In the postnatal period, the infant will be unable to swallow his own secretions, saliva, or feedings. If appropriate precautions are not taken, spillover into the airway and lung parenchyma occurs causing respiratory compromise.

The distal fistula is usually narrow but allows free passage of air from the trachea into the gastrointestinal tract. Gastroesophageal reflux in newborns with TEF/EA is common and occurs in part due to immaturity of the lower esophageal sphincter and poor lower esophageal motility. Reflux of gastric acid or bile into the respiratory tract via the fistula causes a chemical pneumonitis. The tracheas in infants with TEF/EA have a relatively reduced amount of cartilage and relatively increased amount of muscle in the tracheal wall. As a consequence, the tracheas of these neonates are prone to collapse (i.e., tracheomalacia). The presence of a dilated, hypertrophied proximal esophageal pouch may also contribute to tracheomalacia by direct external compression on the trachea.

### **Clinical Presentation**

Infants with esophageal atresia and tracheoesophageal fistula most commonly become symptomatic within the first few hours of life. However, prenatal diagnosis is sometimes suspected if prenatal ultrasonography demonstrates a small or absent stomach bubble in association with maternal polyhydramnios. Occasionally, the dilated blind upper esophageal pouch is also identifiable.

The symptom that occurs shortly after birth is excessive salivation. Excessive salivation results from pooling of secretions in the proximal esophageal pouch and posterior pharynx. Feeding frequently results in regurgitation, choking, gagging, or cyanosis. Tachypnea, atelectasis, and respiratory distress result from reflux of gastric contents into the airway or aspiration from the proximal blind pouch. These events cause a chemical pneumonitis. Abdominal distension results from inspired air entering the gastrointestinal tract via the fistula and causes worsening respiratory distress and pulmonary compromise. Symptoms may be less apparent in children with tracheoesophageal fistula without esophageal atresia (H-type fistula).

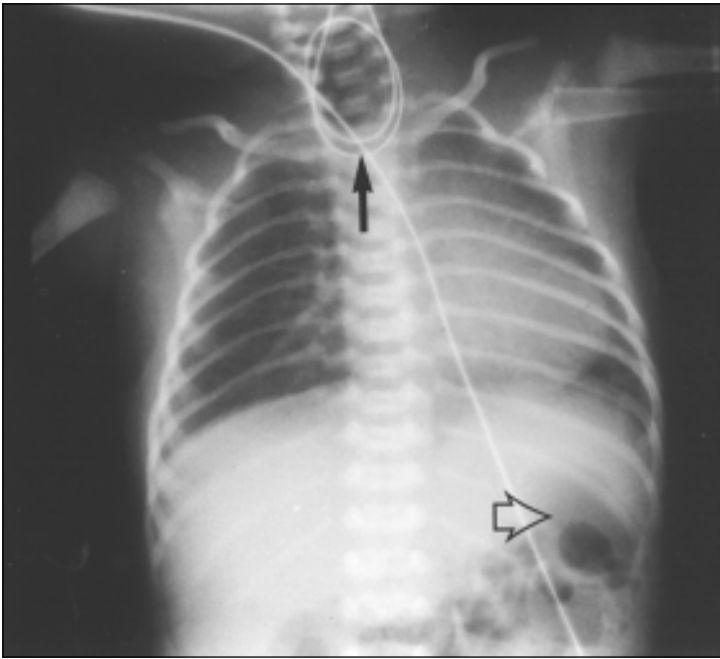


Fig. 71.1. Plain x-ray in child with a Type C tracheoesophageal fistula and esophageal atresia. The nasogastric tube is coiled in the blind proximal pouch (solid arrow) and air present in the bowel (white arrow) confirming the presence of a distal fistula.

The incidence of other associated congenital anomalies is between 50-70%. Infants with esophageal atresia without tracheoesophageal fistula (Type A) are the group most likely to have other anomalies, while infants with H-type fistula (Type E) are least likely to have other lesions. While cardiovascular anomalies predominate (35%), genitourinary (20%), gastrointestinal (24%), skeletal (13%) and neurologic anomalies (10%) are also common (Table 71.2). Tracheoesophageal anomalies are sometimes identified in infants with a broad range of associated malformations known as the VACTERL association, that includes vertebral, anorectal, cardiac, tracheoesophageal, renal, and radial limb deformities. Esophageal atresia is also identified in infants with the CHARGE association that includes coloboma, heart defects, choanal atresia, retardation, genital hypoplasia, and ear deformities (i.e., deafness).

Esophageal atresia occasionally occurs in infants with DiGeorge sequence, Pierre-Robin sequence, Holt-Oram syndrome, polysplenia syndrome, cleft lip and palate, omphalocele, and even more rarely with Schisis association.

**Table 71.2. Gross-Vogt classification of tracheoesophageal anomalies**

Type A	Isolated Esophageal atresia	7.8%
Type B	Esophageal atresia + Proximal TEF	0.8%
Type C	Esophageal atresia + Distal TEF	85.8%
Type D	Esophageal atresia + Double TEF	1.4%
Type E	Isolated TEF (H-type fistula)	4.2%
Type F	Esophageal Stenosis	*

\* not included

## Diagnosis

The diagnosis of esophageal atresia is strongly suggested when there is difficulty or inability to pass (or repass) a nasogastric or orogastric tube. Resistance is typically encountered when the tube is passed to about 11-12 cm. A babygram x-ray frequently confirms the nasogastric tube coiling within the proximal esophageal pouch. To estimate the "gap" or distance between the esophageal segments, a nasogastric tube is passed until resistance is encountered and a chest x-ray is obtained. The distance between the tip of the tube and the carina estimates the "gap." A distance of less than 2-2.5 vertebral bodies is favorable.

The abdominal portion of the babygram is inspected for the presence of distal bowel gas (confirmation of a fistula), a "double bubble sign (i.e., suggesting an associated duodenal atresia), or other dilations.

The diagnostic evaluation of infants with tracheoesophageal anomalies includes screening for other associated congenital defects. Physical examination identifies defects of the VACTERL and CHARGE associations. Echocardiography and renal ultrasonography are obtained to identify cardiovascular defects, define cardiac and aortic arch anatomy, and identify genitourinary malformations. Chromosomal analysis is also indicated.

## Treatment

Initial treatment of infants with tracheoesophageal anomalies includes measures to prevent aspiration and pneumonitis. A sump catheter (i.e., Replogle tube) is positioned in the proximal esophageal pouch to continuously aspirate saliva. The infant is positioned in an upright or head-up prone position to minimize gastroesophageal reflux and prevent aspiration pneumonitis. An H<sub>2</sub>-blocker and broad-spectrum antibiotics are empirically started. Routine endotracheal intubation is avoided since ventilated air entering through the tracheoesophageal fistula can cause gastric perforation and worsening respiratory distress secondary to abdominal distension.

The surgical approach depends on the exact TEF/EA anomaly present. For Type C lesions, division of the fistula and primary anastomosis of the esophagus is the pro-



**Table 71.3. Waterston classification (1962) and current survival**

Group	Description	Survival (%)
A	Birthweight > 5.5 lbs. and otherwise well	100
B	Birthweight 4 – 5.5 lbs. and otherwise healthy Or Birthweight > 5.5 lbs. with moderate pneumonia	85
C	Birthweight < 4 lbs. or higher with severe pneumonia or severe cardiac anomalies	65

cedure of choice. The operation is usually performed via a right posterolateral thoracotomy (4<sup>th</sup> interspace) unless a right-sided aortic arch has been identified pre-operatively in which case a left thoracotomy is preferred. Most pediatric surgeons use an extrapleural approach. For isolated tracheoesophageal fistulas (Type E), a cervical approach is possible in most cases and the fistula is divided via a right-sided, low cervical incision. Esophageal replacement (i.e., colonic interposition, gastric pull-up, etc.) is sometimes required in cases of “long gap” esophageal atresia, esophageal atresia without fistula, or when attempted primary repair and anastomosis has failed.

### Outcomes

Overall survival in modern series is around 85-95%. Infants with other major associated anomalies have a poorer prognosis. The original Waterston's classification (Table 71.3) grouped patients based on birthweight, associated congenital anomalies, and presence/absence of pneumonia; these factors predicted infants with risk of poor survival and helped guide surgical therapy. With the development of modern neonatal critical care, more low birth weight infants with anomalies are surviving. Today, the infants at highest mortality risk include those with:

1. birthweight < 1500 grams,
2. major congenital heart disease,
3. severe associated anomalies, and
4. ventilator dependency.

The Spitz classification (Table 71.4) stratifies infants by birthweight and the presence of major cardiac disease and is currently the most commonly used means to predict survival. Of course,, infants with tracheoesophageal atresia and features of the VACTERL association have a higher mortality rate (20-25%).

Complications after repair of tracheoesophageal anomalies include anastomotic leak (14-16%), recurrent tracheoesophageal fistula (3-14%), esophageal stricture (20-40%) or dysmotility, gastroesophageal reflux (40-70%), tracheal obstruction, and tracheomalacia (10-20%). Recurrent laryngeal injury following repair of tracheoesophageal fistula, particularly H-type, is an uncommon but potentially devastating complication.

**Table 71.4. Spitz classification and survival**

Group	Description	Percent of Total (%)	Survival (%)
I	Birthweight > 1500 g without major congenital cardiac defect	79	97
II	Birthweight < 1500 g or major congenital cardiac defect	19	59
III	Birthweight < 1500 g and major congenital cardiac defect	2	22

***Selected Readings***

1. Waterston DJ, Bonham-Carter RE, Aberdeen E. Esophageal atresia: Tracheoesophageal fistula. A study of survival in 218 infants. *Lancet* 1962; 1:819.
2. Spitz L, Kiely E, Brereton RJ. Esophageal atresia: Five year experience with 148 cases. *J Pediatr Surg* 1987; 22:103.
3. Harmon CM, Coran AG. Congenital anomalies of the esophagus. In: O'Neill Jr. JA et al, eds. *Pediatric Surgery*, 5<sup>th</sup> edition. St. Louis: Mosby 1999; 941-967.
4. Haight C, Towsley H. Congenital atresia of the esophagus with tracheoesophageal fistula: extrapleural ligation of fistula and end-to-end anastomosis of esophageal segments, *Surg Gyn Obstetr* 1943; 76:672.
5. Spitz L. Esophageal atresia: past, present, and future. *J Pediatr Surg* 1996; 31:19.

# Diaphragmatic Anomalies

*Daniel A. Bambini*

## Incidence

Congenital diaphragmatic hernia (CDH) refers to a congenital defect in the posterolateral diaphragm at the “foramen of Bochdalek.” It is a relatively common cause of neonatal respiratory distress with an overall incidence between 1:2000 and 1:5000 live births. CDH accounts for about 90% of congenital diaphragmatic defects. Eighty to ninety percent of congenital diaphragmatic hernias occur on the left side. A hernia sac is only present 20% of the time. Retrosternal hernias (Morgagni) are much less common and only account for 2-6% of congenital diaphragmatic defects. Diaphragmatic eventration is even rarer but is a postoperative complication in 1-2% of children undergoing surgery to repair congenital heart defects.

## Etiology

The specific etiology of CDH is unknown but it is believed to result from a defective formation of the pleuroperitoneal membrane. In the early weeks of development, the pleural and peritoneal cavities communicate via the paired pleuroperitoneal canals. During the 8th week, the pleural cavity becomes separated from the peritoneal cavity by the developing pleuroperitoneal membrane. If the pleuroperitoneal membrane fails to develop, closure of the pleuroperitoneal canal is incomplete and a posterolateral diaphragmatic defect results. A newer hypothesis has arisen from the nitrofen rat model of CDH. Electron microscopy of these nitrofen exposed rat embryos suggests that CDH results from a defective development of the “posthepatic mesenchymal plate” which also contributes to closure of the pleuroperitoneal canal. Although familial cases are reported, most cases of CDH are sporadic. CDH is associated with trisomies 18, 21, and 23 but a specific genetic etiology has yet to be identified.

Morgagni hernias result from failure of the sternal and crural portions of the diaphragm to fuse at the site where the superior epigastric artery traverses the diaphragm. Morgagni hernias are associated with congenital heart disease and trisomy 21. A variant of the retrosternal hernia is associated with the pentalogy of Cantrell which includes: omphalocele, inferior sternal cleft, severe cardiac defects (including ectopia cordis), diaphragmatic hernia and pericardial defects. The diaphragmatic defect results when the septum transversum fails to develop in the embryo.

Eventration of the diaphragm may be either a congenital or acquired lesion. Neonatal eventration may be due to defective central development or enervation of

the diaphragm. It may also result from a traction injury to the nerve roots of the phrenic nerve during traumatic delivery. Eventration most often results from iatrogenic phrenic nerve injury complicating cardiac or mediastinal surgery.

### Clinical Presentation

Thirty percent of fetuses with CDH will be stillborn. If born alive, neonates with CDH usually present with respiratory distress. The onset of respiratory distress can be immediate at the time of delivery or may be delayed for 24–48 hours. Only 10% of patients with CDH present beyond the neonatal period. These children (or adults) may present with vague gastrointestinal symptoms or may be completely asymptomatic discovered only as an incidental finding. Rarely, an older child with CDH may present with life-threatening respiratory and cardiopulmonary distress. Hemodynamic instability may result from severe mediastinal shift caused by a massively distended, intrathoracic stomach. Volvulus and intestinal obstruction are exceedingly uncommon, but reported, presentations of CDH beyond the neonatal period.

The initial signs of CDH in the neonate include tachypnea, grunting respirations, chest retractions, cyanosis, and pallor. Physical exam may reveal a scaphoid abdomen, shifting of the heart sounds to the right (i.e., left hernia), and bowel sounds within the chest. Breath sounds are decreased bilaterally, but are often more diminished on the side of the hernia. Disparity between preductal and postductal pulse oximetry may confirm the presence of right-to-left shunting and persistent fetal circulation. The differential diagnosis of CDH includes cystic adenomatoid malformation, cystic teratoma, pulmonary sequestration, bronchogenic cyst, neurogenic tumors and primary lung sarcoma.

The majority of children with Morgagni (retrosternal) hernias are asymptomatic. Diagnosis is often not made until adulthood. Children with this lesion may present with recurrent respiratory infections, coughing, vomiting or epigastric pain/discomfort. Intestinal obstruction and bowel ischemia/necrosis may result from incarceration of bowel within the hernia sac.

Eventration in the neonate can be asymptomatic but most present with tachypnea, respiratory distress and pallor. Chest physical signs include ipsilateral dullness to percussion and unilateral or bilateral diminished breath sounds. The point of maximal cardiac impulse is shifted away from the side of the lesion. Neonates with diaphragmatic eventration have difficulty sucking and tire easily with feedings. This combination often causes inadequate weight gain. Older children may present with recurrent pneumonia or upper gastrointestinal symptoms. The differential diagnosis of eventration includes tumors, bronchogenic cysts, pulmonary sequestration, pulmonary consolidation, and pleural effusion.

### Diagnosis

Prenatal diagnosis of CDH can be made by fetal ultrasonography as early as 25 weeks gestation. CDH suspected in a newborn infant with respiratory distress is confirmed by “babygram” performed simultaneously with resuscitation. The common radiographic findings of left-sided CDH include air/fluid filled loops of bowel in the left chest, mediastinal shift, and the stomach gas bubble within the chest (Fig. 72.1). A nasogastric tube may appear to coil in the chest if the stomach lies

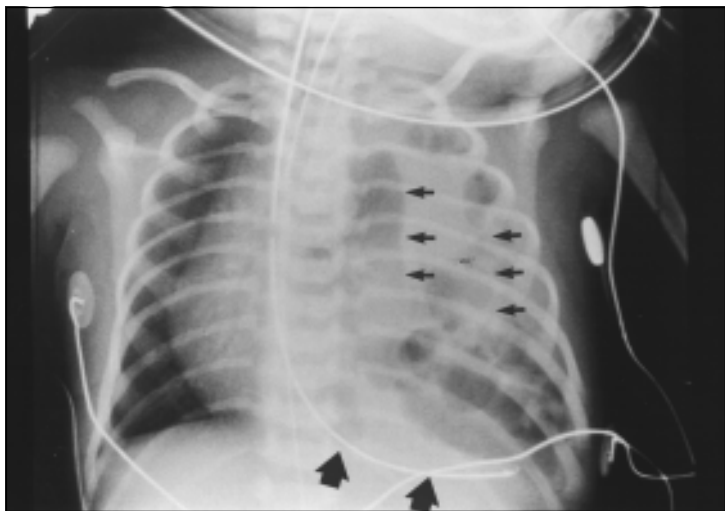


Fig. 72.1. Typical chest x-ray of neonate with left-sided diaphragmatic hernia (Bochdalek type). Small arrows outline loops of bowel within the left chest while large arrows demonstrate nasogastric tube turning back toward the chest. Note also the heart displaced into the right hemithorax.

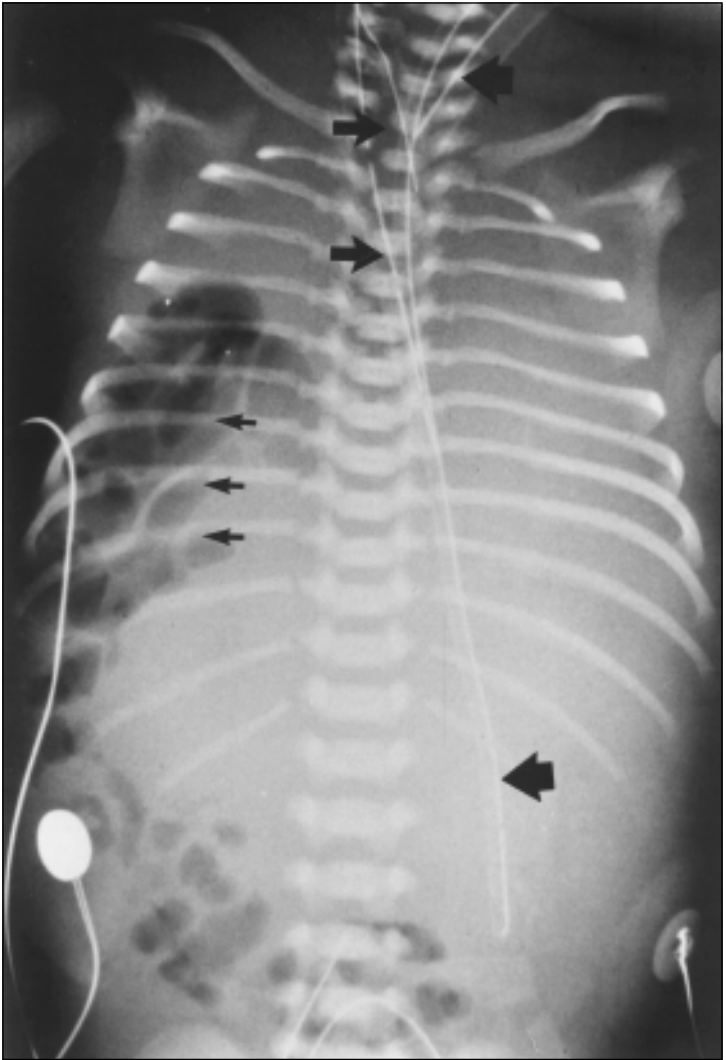
within the thorax. Right-sided CDH (Fig. 72.2) is often more difficult to discern and on x-ray examination may resemble lobar consolidation, fluid within chest, or diaphragmatic eventration.

For Morgagni hernias, posteroanterior and lateral chest radiographs often demonstrate an air-fluid filled structure located immediately posterior to the sternum (Fig. 72.3). This diagnosis is frequently made when gastrointestinal symptoms lead to a contrast study that demonstrates herniated stomach, small bowel or colon within the chest.

Chest radiographs in patients with eventration demonstrate an elevated hemidiaphragm although this finding can be obscured by intubation and positive pressure ventilation. The diagnosis is confirmed by ultrasonographic or fluoroscopic demonstration of paradoxical diaphragmatic motion. Occasionally, computed tomography may be necessary to distinguish eventration from other mass lesions.

### Pathology/Pathophysiology

Congenital diaphragmatic hernia has a complex pathophysiology. Lung hypoplasia occurs as a direct consequence of progressive compression of the developing lungs by herniated viscera. The severity or degree of pulmonary hypoplasia depends upon both the duration and timing of visceral herniation into the chest. Hypoplasia is most severe on the ipsilateral side but occurs on both sides. Gas exchange within these grossly small lungs is limited by a reduced functional area, decreased number of bronchial divisions, a reduced number of mature alveoli, and surfactant deficiency. Alveoli of CDH lungs are immature and have thickened intra-alveolar septa.



72

Fig. 72.2. Neonatal chest x-ray demonstrating the much rarer right-sided diaphragmatic hernia with bowel entering the right hemithorax around the liver. Small arrows indicate bowel loops, large arrows demonstrate nasogastric tube and endotracheal tube, while medium arrows indicate the cannulae of an extracorporeal life support system.

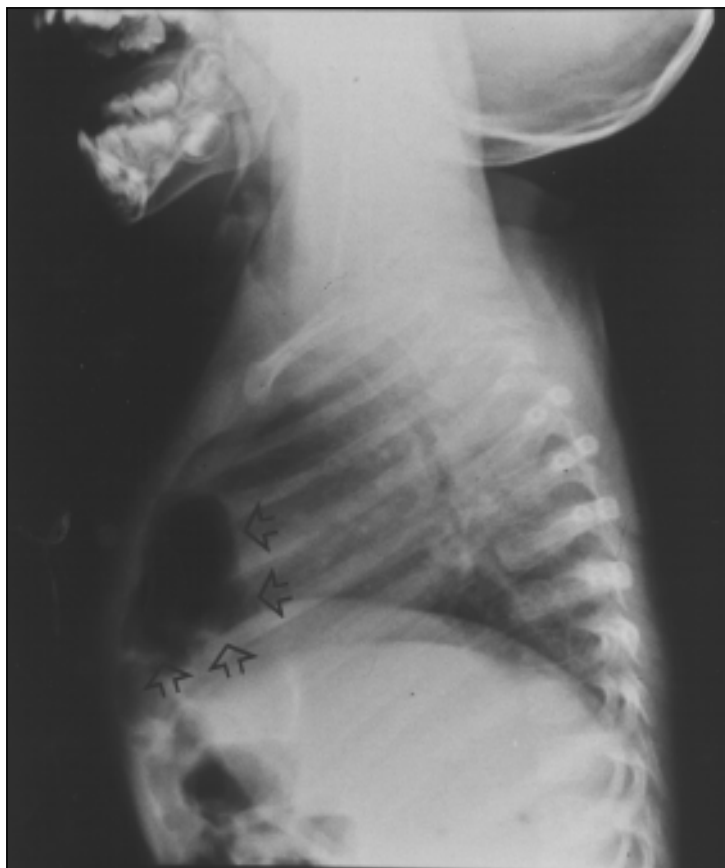


Fig. 72.3. Lateral chest x-ray demonstrating the central, anterior diaphragmatic herniation generally referred to as a hernia of Morgagni.

The pulmonary vasculature is best characterized by the presence of increased muscularization of the pulmonary arterioles. The abnormally muscularized and reactive pulmonary vasculature bed contributes to persistent fetal circulation, pulmonary hypertension and acute respiratory failure. Left ventricular hypoplasia is also present in CDH and may adversely affect cardiopulmonary function.

The hypoplastic lungs in patients with CDH are functionally immature and have limited capability for gas exchange. In many cases, alveolar function is inadequate. Hypoxemia, hypercarbia and acidosis can quickly develop causing further deterioration in pulmonary function. The overly muscularized pulmonary artery tree quickly vasoconstricts in response to reduced oxygen tension and acidosis. This vasoconstrictive response is both exaggerated and sustained causing pulmonary hypertension. Pulmonary hypertension in the newborn with CDH may effect a return

to the fetal pattern of circulation with right-to-left shunting across both the ductus arteriosus and foramen ovale. Intrapulmonary shunting also occurs. Right-to-left shunting further limits gas exchange exacerbating hypoxia, hypercarbia and acidosis. A vicious cycle ensues which can rapidly progress to hypotension, shock and cardiorespiratory failure/arrest.

Morgagni hernias do not typically produce the pathophysiologic problems encountered with the posterolateral diaphragmatic defect. Gastrointestinal obstruction or ischemia and their associated pathophysiologic changes are the presenting features of this lesion when symptomatic.

Unilateral diaphragmatic eventration results in abnormal respiratory mechanics. Ventilation may be ineffective due to a paradoxical motion of the ipsilateral diaphragm during inspiration. Contralateral lung ventilation is also impaired. During inspiration, the mediastinum shifts toward the contralateral side reducing the effective tidal volume on that side.

## Treatment

The treatment of CDH depends upon the time of diagnosis and the clinical presentation. Institutional expertise and the availability of advanced life support techniques (i.e., extracorporeal membrane oxygenation (ECMO)) also influence the management strategy of these infants. Once considered a surgical emergency, CDH is now managed by a delayed surgical approach. Preoperative stabilization and control of pulmonary hypertension is advised. Mechanical ventilation techniques which avoid barotrauma are helpful. High frequency and oscillatory ventilation, nitric oxide administration, surfactant replacement, and ECMO are interventions and therapies readily employed to manage these infants. Fetal interventions (i.e., fetal repair, tracheal ligation), liquid ventilation and lung transplantation are currently experimental therapies investigated at only a few specialized centers.

Neonates with CDH may present with severe respiratory distress that requires aggressive resuscitation to include endotracheal intubation, neuromuscular blockade, and positive pressure ventilation. Initial ventilation should attempt to maintain preductal saturation at or above 90% using the lowest airway pressures capable of providing oxygenation. Barotrauma to the hypoplastic lungs must be minimized.

Orogastric or nasogastric decompression is used to minimize bowel distension which can further compromise respiratory function. Echocardiography is performed to evaluate for associated cardiac anomalies and assess the severity of pulmonary hypertension and shunting. Inotropic agents are used to augment left ventricular function and to raise systemic pressure minimizing right-to-left ductal shunting. Hypervolemia and hypovolemia must be avoided. Hypoxemia, hypercarbia and acidosis must be identified and promptly corrected when present. Bicarbonate may be used to treat acidosis.

Several pharmacologic interventions may be useful in the perioperative management of neonates with CDH. Inhaled nitric oxide, a potent pulmonary vasodilator, may successfully control refractory pulmonary hypertension. Surfactant replacement therapy for CDH is controversial but may be beneficial in improving gas exchange.

ECMO is indicated for infants with CDH and respiratory failure that cannot be managed with conventional therapy. Candidates must have a reasonable chance for survival with no major, nonreversible anomalies. ECMO can be used as a preoperative



or postoperative therapy. Some centers perform diaphragmatic repair while on ECMO.

Surgical repair of congenital diaphragmatic hernia is delayed until after preoperative stabilization and resolution of pulmonary hypertension. The repair should be performed efficiently and expeditiously to minimize operative stress. The abdominal viscera are reduced from the chest via a transabdominal approach. The diaphragmatic defect is closed primarily if possible, or a prosthetic patch may be inserted for larger defects. Tube thoracostomy is optional. The abdominal wall is stretched prior to closure to increase the capacity of the abdominal cavity. Rarely, abdominal closure is achieved with a prosthetic silo or by creating skin flaps and a ventral hernia.

Postoperative ventilator management can be difficult. Chest compliance is decreased after repair and surgical stress can precipitate intense pulmonary vasoconstriction and pulmonary hypertension with recurrent fetal circulatory pattern. Respiratory failure can occur abruptly and ECMO may be required as a rescue therapy. Postoperative ventilation strategies should attempt to minimize barotrauma while maintaining normal  $PO_2$ ,  $PCO_2$  and pH.

Morgagni hernias are surgically repaired via a transabdominal approach. Primary closure of small defects is preferred, but larger defects may require prosthetic patch closure. The treatment of symptomatic eventration is also surgical. The diaphragm on the affected side is plicated via either a transthoracic or transabdominal approach. Plication effectively immobilizes the flaccid diaphragm, reducing the paradoxical movement and mediastinal shift that occurs with respiration.

## Outcomes

Despite the many therapeutic options available to manage patients with CDH, the overall survival remains about 60%. Institutional variation in survival is great and ranges from 25-80%. CDH accounts for 4-10% of neonatal deaths occurring as a result of congenital anomalies. ECMO improves survival by 15-20% at institutions employing this therapy.

Most survivors of CDH are generally healthy and are without respiratory problems. Long-term respiratory status is dependent on the severity of pulmonary hypoplasia at birth and the degree of lung injury sustained during the perinatal period. Gastroesophageal reflux is common in survivors of CDH repair; surgical intervention may be required in 10-15%. Survivors of CDH are at increased risk for neurodevelopmental delays. The overall incidence of neurologic abnormalities is 10-45%.

Surgical results from repair of Morgagni hernias are in general excellent. Complication rates are low. Morbidity and mortality is usually due to associated cardiac anomalies which are frequently found in these children.

The perioperative morbidity and mortality of diaphragmatic plication for eventration is low. Complications are mostly secondary to prolonged mechanical ventilation and/or cardiac dysfunction associated with an underlying cardiac pathology. Plication results in immediate improvement in pulmonary mechanics but long-term respiratory function depends on lung damage prior to plication surgery.

*Selected Readings*

1. Glick PL, Irish MS, Holm BA eds. New Insights into the Pathophysiology of Congenital Diaphragmatic Hernia. Clin Perinatol 1996; 23(4):625-907.
2. Puri P. Congenital diaphragmatic hernia. Current Probl Surg 1994; 31(10):784.
3. Kluth D, Keijzer R, Hertl M et al. Embryology of congenital diaphragmatic hernia. Semin Pediatr Surg 1996; 5(4):224.

# Congenital Malformations of the Lung

*Marleta Reynolds*

Within this section, four congenital malformations of the lung are discussed. All of these lesions are quite rare. Even in large metropolitan children's hospitals, these lesions are seen only a few times each year. The exact etiology of each of these conditions is unknown although there are multiple causation theories. To facilitate the study of this information, they are presented together with a short vignette on presentation, diagnosis and current treatment.

## **Congenital Lobar Emphysema**

Congenital lobar emphysema is an isolated hyperinflation of one lobe of the lung in the absence of extrinsic bronchial compression. Some cases are found to have abnormal bronchial cartilage. Symptoms of respiratory distress including tachypnea, chest wall retractions, and wheezing usually develop in infancy. Upper respiratory infections may precipitate severe symptoms. Physical exam reveals decreased breath sounds on the affected side with hyperresonance. The trachea and mediastinum are shifted to the contralateral side. A chest radiograph reveals hyperinflation of the affected lobe, atelectasis of the adjacent lobes, and mediastinal shift (Fig. 73.1). A chest CT may be helpful to rule out a perihilar bronchogenic cyst causing bronchial obstruction. The left upper lobe is affected most often followed by the right middle lobe.

Positive pressure ventilation can potentially cause overinflation of the involved lobe. Overinflation of the diseased lung can cause cardiovascular collapse and must be avoided. At surgery, the chest is opened and the lobe herniates out of the chest and allows safe ventilation (Fig. 73.2). The mediastinum should be inspected for lesions that could cause bronchial obstruction. Lobectomy is performed and the remaining lung expands to fill the space.

## **Pulmonary Sequestration**

A pulmonary sequestration is a segment or lobe of lung which has no bronchial communication with the tracheobronchial tree. The sequestered lung tissue has systemic arterial blood supply that may arise from the thoracic or abdominal aorta. Blood return from a pulmonary sequestration is usually via the pulmonary venous system. Occasionally the venous drainage will be to systemic veins. A sequestration probably develops from an aberrant lung bud that pinches off from the caudal foregut with its own blood supply.

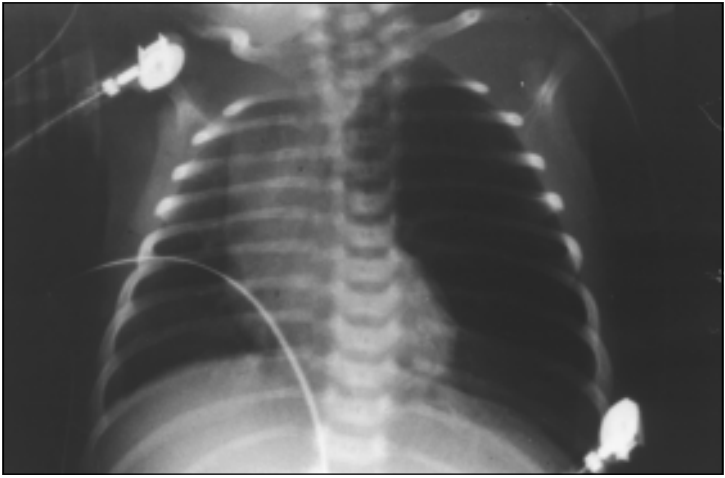


Fig. 73.1. Radiograph of a child with congenital lobar emphysema. This x-ray demonstrates hyperlucency of the left chest, spread ribs on the left, mediastinal shift, and a collapsed left lower lobe.

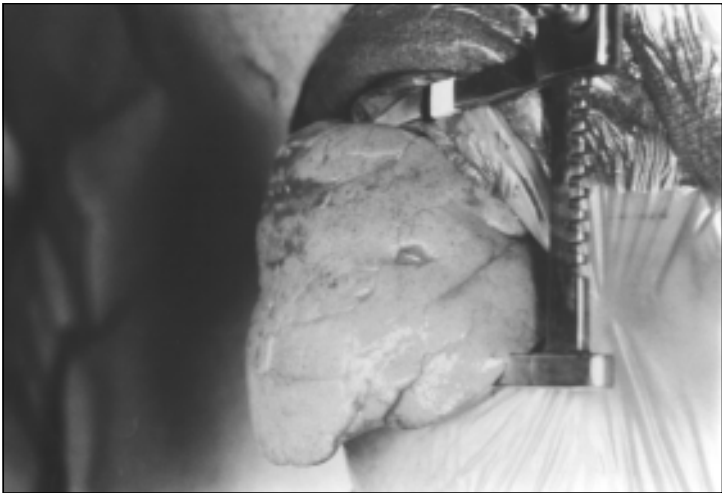


Fig. 73.2. Congenital lobar emphysema of the left upper lobe at the time of surgical resection. The left lung and lingula are herniating through the thoracotomy incision due to hyperexpansion of the lobe.

### *Extralobar Sequestration*

An extralobar sequestration is triangular in shape and is usually found in the posterior costophrenic angle adjacent to the aorta or esophagus. It can be found anywhere in the chest and upper abdomen. It is often associated with a congenital diaphragmatic hernia. Most children with extralobar sequestration are asymptomatic and the lesion is discovered as an incidental finding on chest radiograph. In a newborn or infant, an ultrasound can be diagnostic, but in older children CT of the chest is usually diagnostic. Very occasionally, angiography will be needed to identify the anomalous blood supply.

### *Intralobar Sequestration*

An intralobar sequestration is found within normal lung parenchyma (Fig. 73.3). The most common sites are the right lower lobe and left lower lobe. In the majority of cases, the venous return is to the pulmonary venous system.

Infection within the sequestered lung generally leads to the diagnosis. Chronic infection and lung abscess may prompt a chest radiograph and chest CT (Fig. 73.4). Angiography is seldom indicated. Degenerative arteriosclerotic changes of the anomalous arterial vessel may develop and lead to hemoptysis.

The involved lobe should be resected. Careful exploration and identification of the arterial supply of the affected lobe with suture ligation of the vessel will avoid exsanguinating hemorrhage from the systemic vessel that may retract into the abdomen if it is divided before control is obtained.

### **Congenital Cystic Adenomatoid Malformation (CCAM)**

The etiology of congenital cystic adenomatoid malformation is unknown, but the lesion is represented by a combination of solid and cystic components with an overgrowth of terminal bronchiolar-type tubular structures and a lack of mature alveoli (Fig. 73.5). The predominantly solid lesions are found in stillborn or premature infants and are associated with fetal anasarca, ascites and maternal polyhydramnios. The solid-cystic lesions can produce respiratory distress in the near-term infant. The cystic lesions usually do not present until late infancy or early childhood and occasionally into adulthood. The cystic lesions become secondarily infected and are identified after a bout of pneumonia or after recurrent pneumonias.

Prenatal ultrasound can identify this anomaly of the lung. When diagnosis is made prenatally the only predictor of poor outcome is the presence of hydrops. Fetal intervention has included placement of thoracoamniotic shunt or lobectomy. After birth, the chest radiograph can be diagnostic of a congenital cystic adenomatoid malformation but can be confused with a congenital diaphragmatic hernia. The lesion with few cystic spaces may be confused with a parenchymal bronchogenic cyst. CT scan may be very helpful in differentiating the pathology.

The abnormal histology found in the lesion consists of an adenomatoid increase of terminal respiratory bronchiolar-like structures lined with ciliated columnar epithelium. Cysts with bronchial-type epithelium may have polypoid overgrowths and can be interspersed with the solid tissue. There are no bronchial mucoserous glands or cartilage plates. Alveolar cysts may be lined with mucous-secreting cells. Malignancy has been reported in more than 10 cases.



Fig. 73.3. An intrapulmonary lobar sequestration without bronchial communication, infection, or abscess formation.

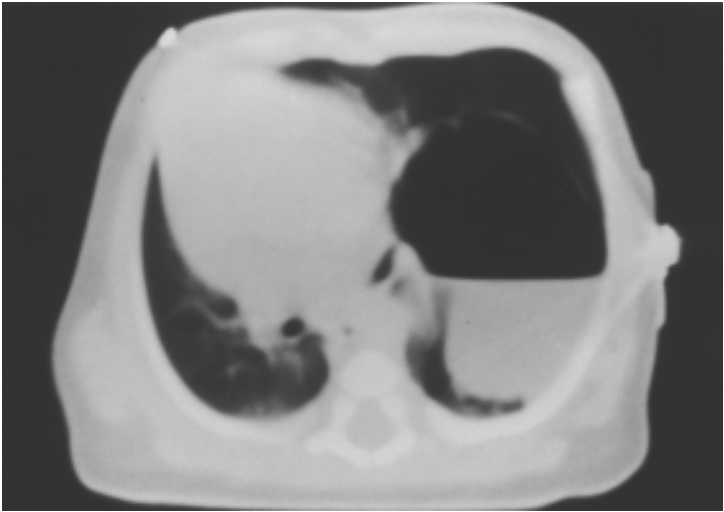


Fig. 73.4. An infected intrapulmonary sequestration that has developed into a thoracic abscess with an air-fluid level.

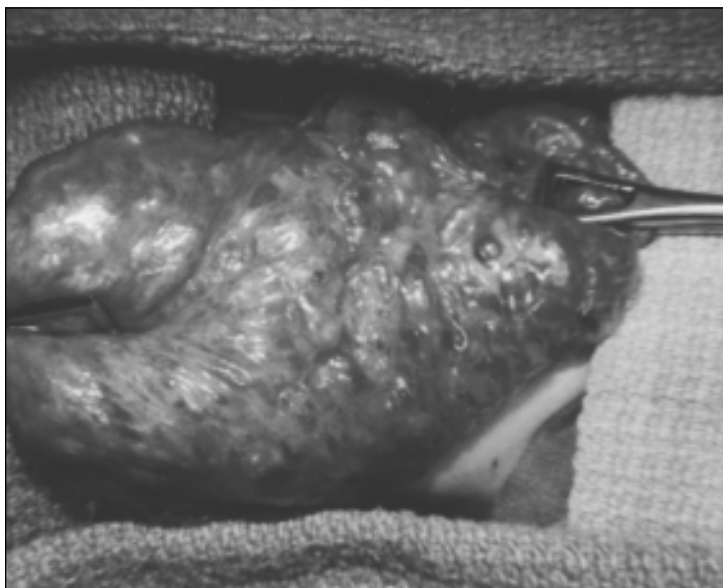


Fig. 73.5. Cystic adenomatoid malformation with macrocystic changes easily discernable by simple examination.

Surgical resection of the involved lobe is indicated. Exploration for an anomalous systemic arterial supply should be performed because an overlap in diagnosis between congenital cystic adenomatoid malformation and intrapulmonary sequestration has been reported.

### **Bronchogenic Cyst**

A bronchogenic cyst (Fig. 73.6) develops as a result of abnormal budding from the developing tracheo-bronchial tree. It occurs at the glandular stage of bronchial development. The cysts can be found in the hilum of the lung, the mediastinum, the posterior sulcus and within the pulmonary parenchyma. Parenchymal cysts present with fever and other signs of pulmonary sepsis. By compressing the airway, mediastinal cysts may produce wheezing, signs of airway obstruction, and may create distal pulmonary infection and its associated symptoms of fever and cough.

Diagnosis can be made by chest radiograph for parenchymal cysts and chest CT for mediastinal cysts. MRI may provide additional information about the cysts. The parenchymal cyst can be confused with a cystic adenomatoid malformation. The cysts can be filled with air or mucous. If the cyst becomes infected, the air and pus may create an air-fluid level on chest radiographs.

The cysts are lined with ciliated columnar or cuboidal epithelium on a fibromuscular base. If infected the cyst's epithelial lining may be destroyed. The cyst wall is thin and may contain cartilage and bronchial glands. Association with lower lobes is frequent, and there is rarely a communication with the tracheobronchial tree. A

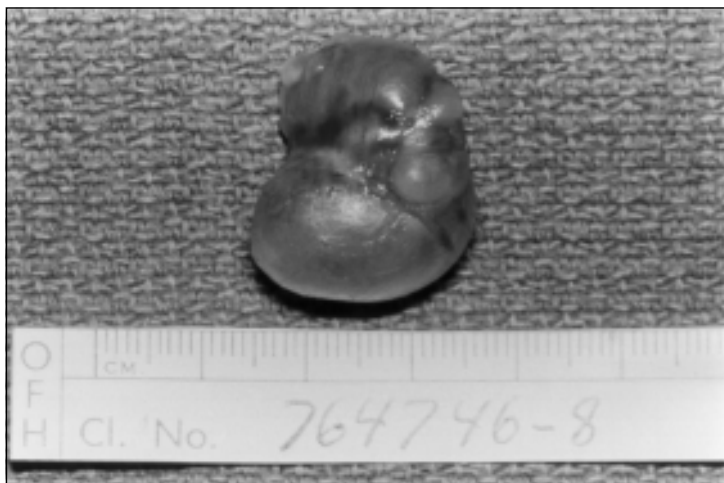


Fig. 73.6. Bronchogenic cyst after surgical removal with characteristic thin-walled cystic structure.

single case of adenocarcinoma has been reported in an 8-year old girl with a bronchogenic cyst.

Surgery is indicated for mediastinal and parenchymal bronchogenic cysts. If pulmonary sepsis has developed it should be aggressively treated prior to surgical resection. The mediastinal cyst requires simple excision and may be amenable to thoroscopic removal. The posterior wall of the trachea may need to be patched with a piece of pericardium if it is resected with the cyst. A lobectomy is usually required to treat parenchymal cysts. Incomplete resection of the cyst may lead to recurrence. Anesthetic management must be individualized but positive pressure ventilation and nitrous oxide can be used for most patients.

### *Selected Readings*

1. Savic B et al. Lung sequestration: Report of seven cases and review of 540 published cases. *Thorax* 1979; 34:96.
2. Reynolds M. Congenital lesions of the lung. In: Shields TW ed. *General Thoracic Surgery*, 4th Edition, Vol. 2. Williams & Wilkins, Media 1994; 859-87.
3. Miller JA, Corteville JE, Langer JC. Congenital cystic adenomatoid malformation in the fetus: Natural history and predictors of outcome. *J Pediatr Surg* 1996; 31(6):805-8.
4. Cass DL, Crombleholme TM, Howell LJ et al. Cystic lung lesions with systemic arterial blood supply: A hybrid of congenital cystic adenomatoid malformation and bronchopulmonary sequestration. *J Pediatr Surg* 1997; 32(7):986-90.
5. Suen HC, Mathiesen DJ, Grillo HC. Surgical management and radiologic characteristics of bronchogenic cysts. *Ann Thorac Surg* 1993; 55(2):476-81.



# Foreign Bodies in the Air Passages and Esophagus

*Marleta Reynolds*

## Foreign Bodies in the Esophagus

### *Incidence*

Children between the ages of 1 and 5 years are at risk for accidental ingestion of a foreign object. Most children in this age range swallow some toy, coin, or button at one time or another. The vast majority of swallowed foreign objects are probably never known, even to parents.

### *Clinical Presentation*

Most ingested objects pass through the gastrointestinal tract without difficulty. However, a foreign object may become lodged proximal to a congenital or acquired stricture of the esophagus. In addition, objects such as coins, toys, bones and open safety pins can become lodged in the hypopharynx or at one of three levels of physiologic narrowing of the esophagus: the cricopharyngeus, the aortic arch and gastroesophageal junction. Children may complain of dysphagia, develop sialorrhea or may develop respiratory symptoms from compression of the membranous trachea.

### *Diagnosis*

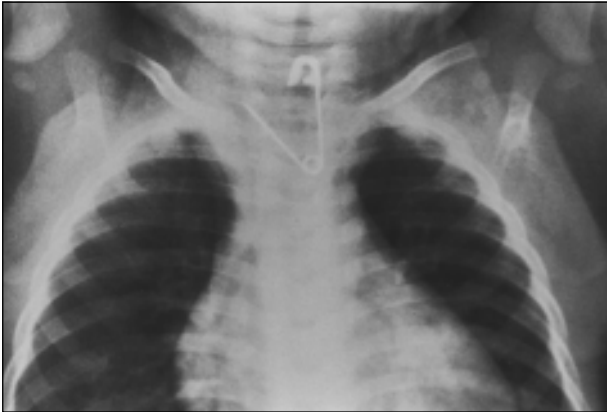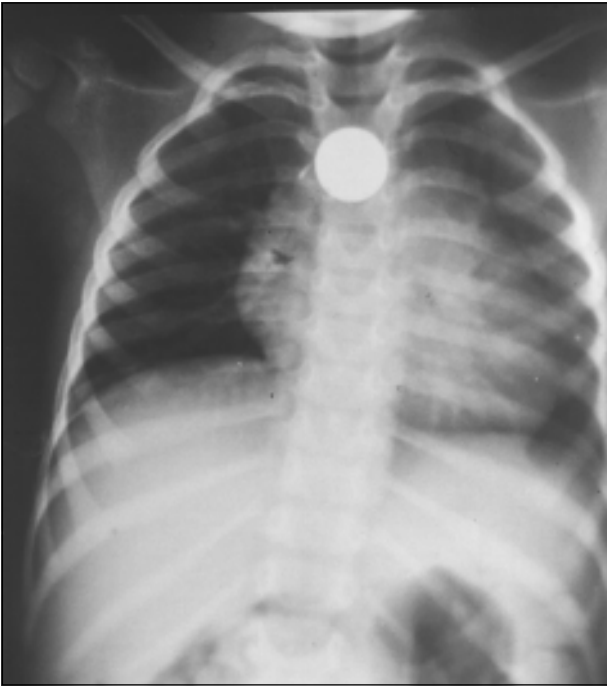Posterior and lateral neck radiographs and a chest radiograph (Figs. 74.1A and 74.1B) are needed to identify the location of the object and evaluate for extravasated air in the mediastinum, subcutaneous tissue, or chest. Water soluble contrast may be used to identify the object when plain films are negative and clinical suspicion is high.

### *Pathophysiology*

Complications of esophageal foreign bodies include perforation, aspiration, retropharyngeal abscess, mediastinitis, pericarditis, pneumothorax, pneumomediastinum and vascular injury. Complications that develop well after the ingestion include respiratory compromise, extraluminal migration, esophageal stricture, tracheoesophageal fistula and recurrent pneumonia.

### *Treatment*

Small blunt objects are of little concern but large or sharp objects may need to be removed. The urgency of removal will depend on the type of foreign body, the



Figs. 74.1A and 74.1B. (opposite) Coin and open safety pin within the esophagus. Since these foreign bodies are seen "en face" we know they are in the esophagus and not in the trachea (where foreign bodies generally are seen on edge). The safety pin is probably caught in the cricopharyngeus muscle while the coin is caught at the aortic arch.

length of time the object has been in the esophagus and the patient's symptoms. An algorithm for coin ingestion is included (Fig. 74.2) Foreign objects below the cricopharyngeus are removed under general anesthesia using a rigid or flexible esophagoscope and appropriate grasping forceps or baskets.

### *Outcomes*

Perforation and bleeding are the most frequent complications of extraction and occur in 2-13% of cases. Most foreign bodies that reach the stomach will pass and outpatient observation with instructions to return if abdominal complaints arise is indicated.

## **Foreign Bodies of the Air Passages**

### *Incidence*

Aspiration of a foreign body into the air passages usually occurs in older infants and toddlers. Boys are affected more than girls in a ratio of 2:1.

### *Clinical Presentation*

A caretaker may witness the child placing a toy or coin in the mouth and then choking, gagging or developing paroxysms of coughing and wheezing. Once the object becomes lodged in the airway, an asymptomatic period may follow. The object then may precipitate erosion or infection. The child may develop fever, malaise, cough and/or hemoptysis. Atelectasis, pneumonia, or lung abscess may result.

### *Diagnosis*

Posteroanterior and lateral chest radiographs (Fig. 74.3) are obtained to evaluate a child suspected of aspirating a foreign body. Posteroanterior and lateral soft-tissue neck radiographs are useful for identifying tracheal foreign bodies. Inspiratory and expiratory chest radiographs can also be helpful. On expiration the air is trapped behind the obstruction causing emphysema of the involved lobe or lung and mediastinal shift to the contralateral side.

### *Treatment*

General anesthesia is used to remove foreign bodies of the airway. The laryngoscope is used to expose the larynx and spray topical lidocaine before the bronchoscope is introduced. The rigid ventilating bronchoscope is used to visualize the foreign body (Fig. 74.4). The grasping forceps are introduced into the bronchoscope. The object is removed through or with the bronchoscope. Humidity, bronchodilators and steroids may be helpful in decreasing postoperative edema. Racemic epinephrine may also be administered. A postoperative chest radiograph should be obtained to identify a pneumothorax or mediastinal air complicating foreign body removal.

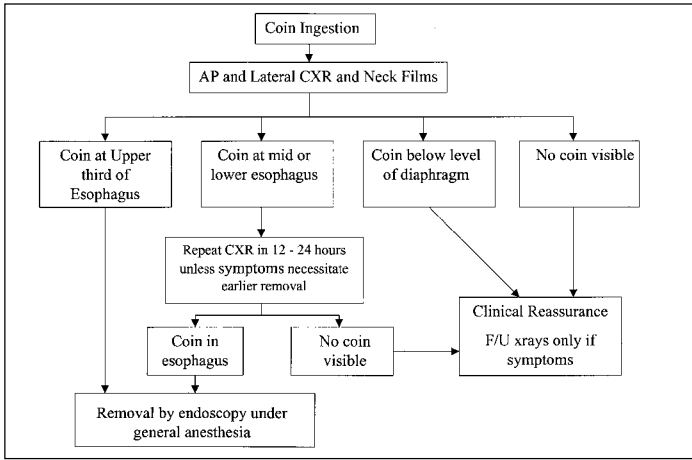


Fig. 74.2. Management algorithm for coin ingestion by a child.

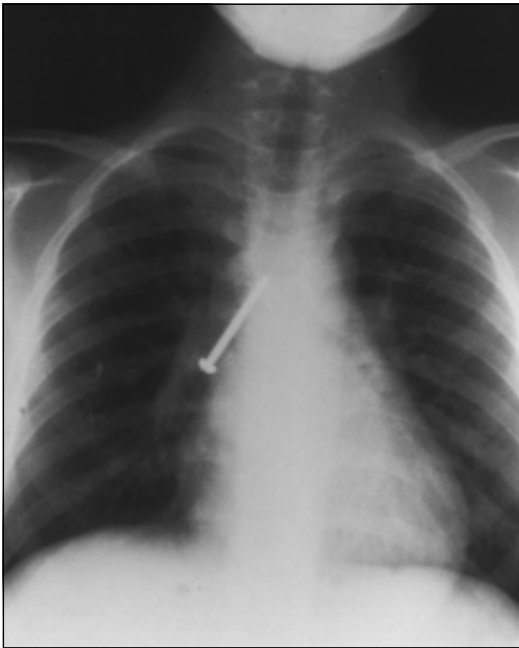

Fig. 74.3. Screw within the trachea, blunt end pointed downward (most common orientation), and passing into the right mainstem bronchus (always the most common location for an aspirated foreign body).

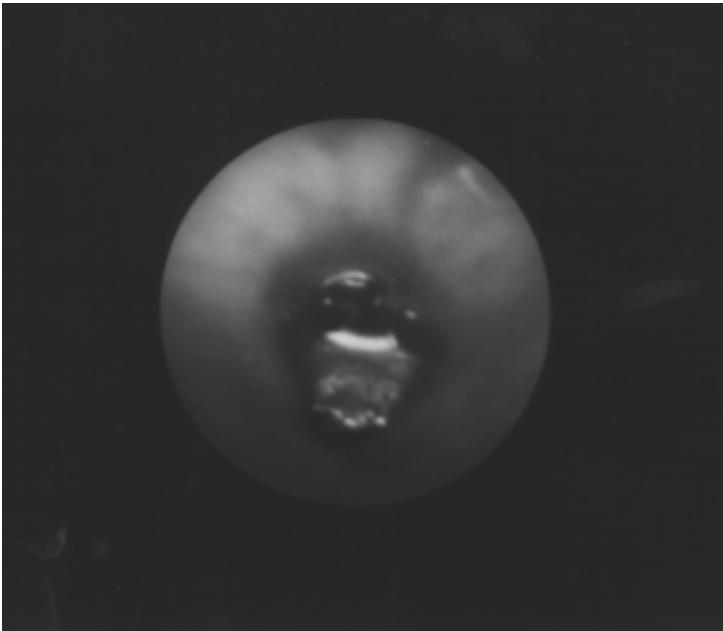


Fig. 74.4. Foreign body within the main trachea that proved on extraction to be part of a crayon.

### *Selected Readings*

1. Quinn PG, Conners PJ. The role of upper gastrointestinal endoscopy in foreign body removal. *Gastrointestinal Endoscopy Clin N Amer* 1994; 4(3):571-593.
2. Holinger LD. Foreign bodies of the airway & esophagus. In: Holinger LD, Lusk RP eds. *Pediatric Laryngology & Bronchoesophagology* 1997; 233-251.
3. Healy GB: Management of tracheobronchial foreign bodies in children: an update. *Ann Oto Rhin Laryn* 1990; 99:889-891.
4. Webb WA. Management of foreign bodies of the upper gastrointestinal tract. *Gastroenterology* 1988; 94:204-216.

## Chylothorax and Diseases of the Pleura

*Harry T. Papaconstantinou and Dai H. Chung*

### Chylothorax

#### *Incidence*

Chylothorax is an accumulation of lymphatic fluid in the pleural space. Most cases involve the right side, although bilateral chylothoraces do occur. Males are affected twice as frequently as females. In general, chylothorax occurs as a direct result of surgical trauma. Nontraumatic chylothorax is less common, and when bilateral, it is usually a result of venous hypertension in the brachiocephalic system due to superior vena caval thrombosis.

#### *Etiology and Pathophysiology*

The etiology of chylothorax can be classified into four groups:

1. congenital,
2. traumatic,
3. neoplastic, and
4. spontaneous (Table 75.1).

Congenital chylothorax occurs in the neonatal period (Fig. 75.1) and is associated with multiple congenital anomalies such as lymphangectasia. Trauma to the thoracic duct during delivery is possible due to difficult extraction during breech presentations; hyperextension of the spine may rupture the delicate lymphatic vessels lying over the vertebral bodies. However, intraoperative trauma to the thoracic duct is the most common cause of chylothorax in all age groups. Surgical procedures in the anatomic region of the thoracic duct, which is quite small and has many tributary lymphatic channels, may disrupt the thoracic duct and result in chylothorax. The most common of these procedures include congenital diaphragmatic hernia repair, tracheoesophageal fistula repair, PDA ligation, and especially cardiac procedures. Tumors such as lymphoma, neuroblastoma and other metastatic malignancies may cause chylothorax by obstructing the lymphatic flow in the thoracic duct. Causes of spontaneous chylothorax include forceful straining, coughing or vomiting, as well as subclavian or superior vena caval thrombosis. An increase in intraductal pressure due to elevated central venous pressure or increased chyle transport after a meal, coupled with an increase in intrathoracic pressure may result in a "blowout" or rupture of the thoracic duct.

**Table 75.1. Etiology of chylothorax****CONGENITAL**

- Lymphangiomatosis
- Lymphangiectasia
- Down's syndrome
- Noonan's syndrome
- Turner's syndrome

**TRAUMA**

- Operative
  - Cardiothoracic/esophageal procedures
  - Diaphragmatic hernia repair
  - Subclavian or left heart catheterization
- Blunt trauma
  - Birth trauma
  - Physical abuse
- Penetrating trauma

**NEOPLASTIC**

- Lymphoma
- Neuroblastoma

**SPONTANEOUS**

- Forceful straining, coughing or vomiting
- Subclavian/superior vena cava thrombosis

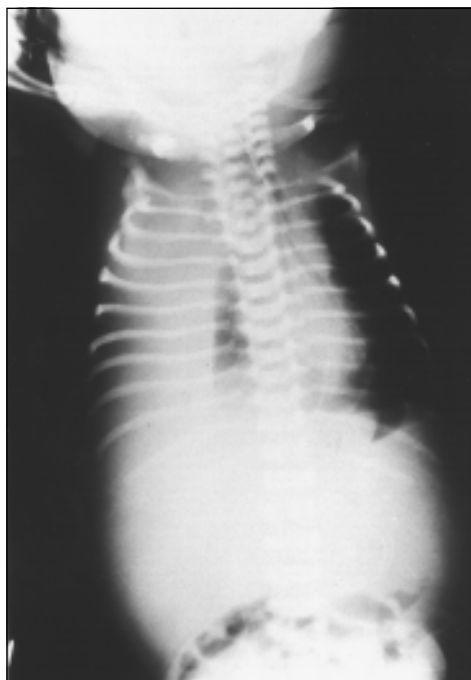


Fig. 75.1. Right hemithorax opacification from neonatal chylothorax.

## *Anatomy*

The thoracic duct originates in the abdomen as the cisterna chyli located over the second lumbar vertebrae. The duct passes through the aortic hiatus and extends upward into the posterior mediastinum on the right. At the level of the fifth vertebral body, the thoracic duct crosses the midline to the left hemithorax, where it continues its ascent posterior to the aortic arch. The thoracic duct empties into the venous circulation at the junction of the subclavian and internal jugular veins (Fig. 75.2).

Normal chyle flow ranges between 50-200 ml/hr and varies widely depending on volume of fat digestion and central venous pressure. Chyle contained in the thoracic duct transports nearly 75% of the ingested fats from the small intestine to the systemic circulation. Chyle is also rich in protein and lymphocytes. Consequently, prolonged loss of chyle from a thoracic duct fistula can result in malnutrition, hypoproteinemia, fluid and electrolyte imbalance, metabolic acidosis and immunodeficiency.

## *Symptoms and Diagnosis*

Chyloous compression produces acute respiratory distress symptoms: dyspnea, tachypnea and cyanosis. The involved hemithorax contains intrapleural fluid that produces percussion dullness and diminished breath sounds. If severe, the fluid produces mediastinal and tracheal shift to the contralateral side. There are other causes of pleural effusion and respiratory distress, but the chylothorax fluid has multiple characteristic physical and laboratory features that confirm the diagnosis (Table 75.2).

The presence of polyhydramnios, hydrops fetalis, and pleural effusion on fetal ultrasound is highly suggestive of congenital chylothorax. Congenital chylothorax is considered seriously in all cases of nonimmune hydrops fetalis in which pleural effusions develop early. In neonates with traumatic birth, symptoms of respiratory embarrassment observed in combination with pleural effusion are highly suggestive of chylothorax. Symptoms are usually rapid in onset with 50% of cases occurring within 24 hours of delivery.

Evidence of significant pleural effusion following thoracic surgery alerts the physician to the possibility of thoracic duct injury. Patients with chylothorax resulting from obstruction of the thoracic duct by a mass along with cervical or supraclavicular lymphadenopathy indicates the need to identify malignancy.

## *Treatment and Outcome*

The primary therapy for chylothorax is thoracostomy tube drainage. This allows quantitation of the daily chyle leak, promotes pulmonary reexpansion, and allows the leak to seal. In cases of congenital chylothorax, this drainage may be achieved with intrauterine thoracentesis or insertion of a pleuroamniotic shunt. In addition, dietary manipulations are useful to reduce lymph flow through the thoracic duct. Large-chain triglycerides are primarily transported to the systemic circulation by the cisterna chyli and thoracic duct; therefore restriction to medium- and short-chain triglycerides, which are absorbed directly into the portal venous circulation, results in reduced lymph flow through the thoracic duct and promotes fistula closure. Patients refractory to thoracostomy drainage and dietary manipulations require cessation of oral feedings and the implementation of total parenteral nutrition.



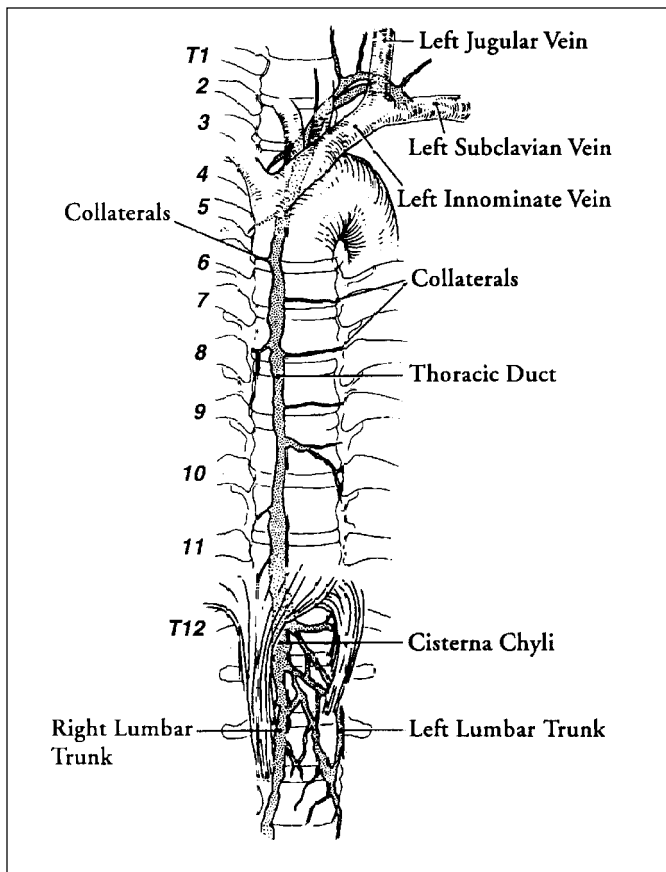


Fig. 75.2. Schematic drawing of the thoracic duct anatomy. Reprinted with permission from Cohen RG. The pleura. In: Sabiston DC, Spencer FC eds. Surgery of the Chest. 6<sup>th</sup> ed. W.B.Saunders, 1995.

**Table 75.2. Characteristic features of chylous fluid**

Color	Cloudy if patient on oral diet Serosanguinous if NPO
Specific gravity	1.012 – 1.025
Protein	> 5 g/2L
Fat	> 400 mg/ 2L
Triglycerides	> 220 mg/2L
Lymphocytes	> 90% of total cells
Gram stain	Negative
Sudan Red stain	Chylomicrons/fat globules

The rate of chyle leak from a thoracic duct fistula can be massive with significant volume and nutritional losses; they must be replaced appropriately. The immune status of the patient must also be monitored closely due to a steady decline in circulating lymphocytes and potential risks for sepsis. It is generally accepted that a 7-10 day trial of thoracostomy tube drainage and dietary manipulation is justified in patients with chylothorax. This regimen is successful in 70-80% of cases. However, when drainage exceeds 180 ml/day/year of age in a child (maximum 500 ml/day), surgical correction is required. Ingestion of cream or milk products prior to surgery will engorge the lymphatic vessels of the thoracic duct and facilitate visualization of ductal injury for suture ligation. Application of fibrin glue may also help seal the leak. Thoracoscopic management with suture ligation along with pleurodesis is an alternative intervention. When operative options fail or are exhausted, the pleuroperitoneal shunt may provide prolonged symptomatic relief.

### **Outcome**

Conservative management of chylothorax in the pediatric population is successful in 70-80% of cases, with the majority of the remaining patients successfully managed by operative intervention. Long-term follow-up in newborns with congenital chylothorax demonstrates less encouraging results due to the underlying pulmonary malformations in many of these children.

Introduction of total parenteral nutrition and enteral formulas containing medium-chain triglycerides as well as the operative thoracic duct ligation for chylothorax have significantly improved the overall outcome for postcardiotomy patients. However, mortality remains close to 10% in children who develop chylothorax following surgery for congenital heart disease. Most deaths are due to overwhelming bacterial and fungal infections, presumably as a consequence of excess loss of lymphocytes in chylous drainage.

## **Empyema**

### ***Etiology and Pathophysiology***

Empyema is the accumulation of infected fluid in the pleural space. In children, empyema is generally a sequelae of severe pneumonia and occurs in about 1% of cases. Other less common causes include trauma, intrathoracic perforation of the esophagus, or infection of the retropharyngeal or mediastinal spaces. The most common organisms identified in childhood cases of empyema are *Staphylococcus aureus*, *Hemophilus influenzae*, and *Streptococcus pneumoniae*. The development of empyema is described in three stages. The early stage or exudative stage (24-72 hours) is characterized by an accumulation of thin pleural fluid with low cellular content. This is followed by the fibrinopurulent stage (7-10 days) during which the infected pleural fluid consolidates, fibrinous material accumulates, and loculation formation results in decreased lung mobility. Finally, the organization phase ensues (2-4 weeks) and the involved lung frequently becomes entrapped by a pleural peel which forms as a result of fibroblast proliferation and fibrin deposition.

### ***Symptoms and Diagnosis***

Children with empyema present with fever, cough, respiratory distress, and chest pain. A recent history of pneumonia may be identified. Physical exam reveals decreased

breath sounds, dullness to percussion, and tactile fremitus on the involved hemithorax. Irritation of the pleura results in a friction rub on auscultation. Chest x-ray (Fig. 75.3) typically identifies thickened pleura in association with a pleural effusion. Ultrasound may be used to determine the presence of loculations; however, computerized tomography is the most sensitive study to determine the degree of pleural thickness, the presence and number of loculations, and presence of lung consolidation (Fig. 75.4). Thoracentesis with fluid analysis can occasionally confirm the diagnosis. The gross appearance of the fluid is turbid and thick. Laboratory data consistent with empyema include pH < 7.2, glucose level < 40 mg/dL, protein > 3 g/dL, LDH > 200 U/L, and WBC > 15,000/mm<sup>3</sup>. Gram stain and culture of the pleural fluid is important to help guide antibiotic therapy.

### *Treatment and Outcome*

Successful treatment of empyema depends on early diagnosis, with administration of appropriate antibiotics in combination with pleural drainage and maintenance of lung expansion. Diagnostic thoracentesis is occasionally therapeutic in the early exudative phase of empyema. Thoracostomy with closed drainage and intravenous antibiotics are necessary to treat fibrinopurulent stages of empyema. Failure of antibiotics and thoracostomy tube drainage is usually a result of inadequate drainage of loculated fluid or lung entrapment in the fibrotic peel. Simple loculations can be lysed by urokinase (20,000 IU of diluted urokinase, three installations per day) or streptokinase administered through a preexisting chest tube; however, if unresponsive, thoracoscopic pleural debridement and decortication can provide comparable clinical results to traditional open thoracotomy techniques. Lung abscess may require wedge resection, or even lobar resection. Mortality associated with empyema in children is less than 3%. Pulmonary function after recovery is usually normal, although mild restrictive or obstructive disease on follow-up spirometry has been reported.

## **Spontaneous Pneumothorax**

### *Etiology and Pathophysiology*

Pneumothorax is a collection of air in the pleural space. Pneumothorax occurs in 0.5-2.0% of all infants, and particularly in patients receiving high continuous positive airway pressure for treatment of hyaline membrane disease, meconium aspiration syndrome, or congenital diaphragmatic hernia. Uneven ventilation, poor pulmonary compliance, high viscosity of lung fluid, and high surface tension lead to increased intraalveolar pressure which often results in alveolar over-distention and rupture. The dissection of air through the parenchyma causes pulmonary interstitial emphysema. Once the visceral pleura is perforated, pneumothorax results.

Spontaneous pneumothorax may occur in children with no known underlying disease or may result from an underlying condition such as a congenital bleb, cystic adenomatoid formation, or cystic fibrosis. Typically, patients are adolescent males with ectomorphic features. Recurrence rates are 50% after the first episode, 62% after the second, and 83% after the third.

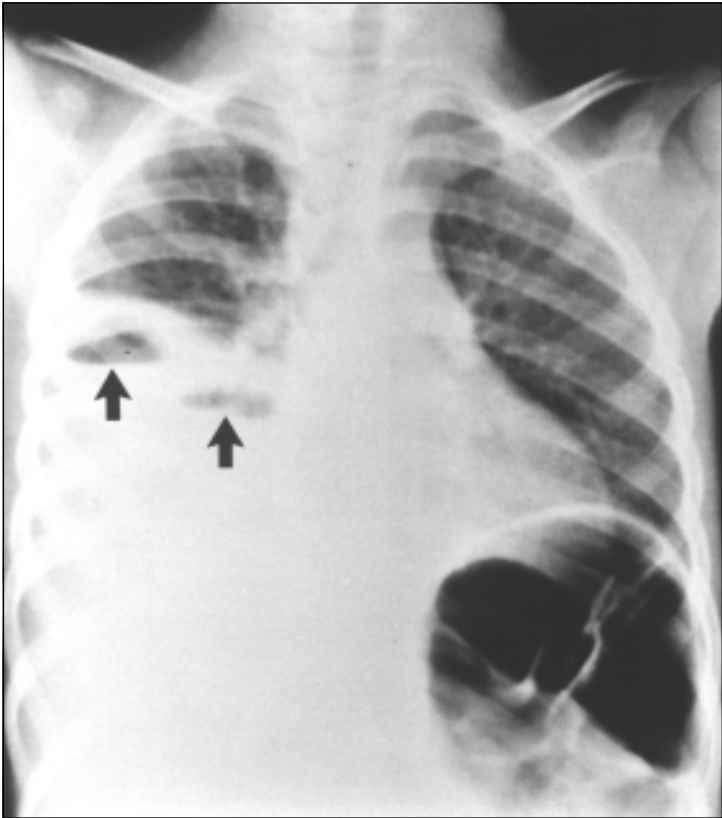


Fig. 75.3. Empyema demonstrated with lower thorax opacification and air fluid levels (arrows).

### *Symptoms and Diagnosis*

The most common presenting symptoms of spontaneous pneumothorax are ipsilateral chest pain and dyspnea. Other symptoms include tachypnea, intercostal retractions, cyanosis, and grunting. Physical exam reveals decreased breath sounds in the ipsilateral hemithorax. If a tension pneumothorax is present, the trachea is usually shifted to the contralateral side. Diagnosis is confirmed by chest x-ray, and radiographic findings are enhanced if films are taken at end expiration.

### *Treatment and Outcome*

Spontaneous unilateral pneumothorax of 15-20% in size may be monitored by serial chest x-rays if the patient is asymptomatic. Pleural air can be reabsorbed at a rate of 1.25% per day, and there are recurring reports, poorly documented or explained, that this rate may be increased by administration of 100% oxygen. If the patient is symptomatic or the size of the pneumothorax increases, a thoracostomy

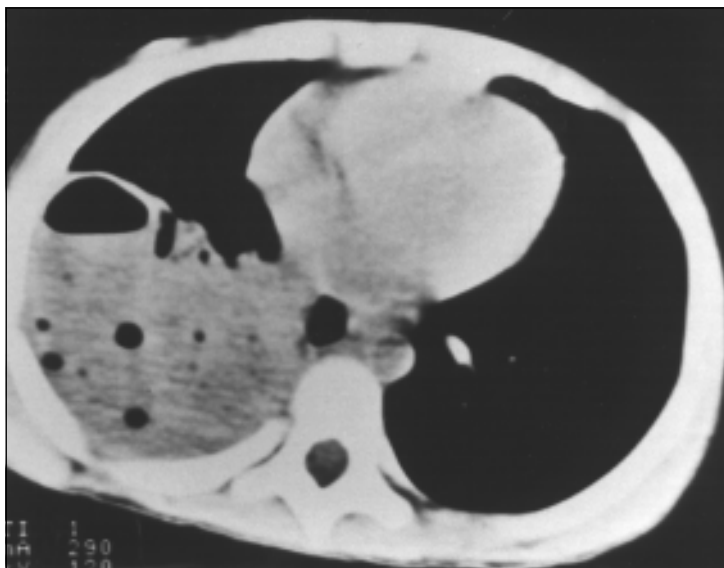


Fig. 75.4. Computed tomography shows the size and extent of an empyema with multiple air and fluid filled spaces.

tube must be inserted. In tension pneumothorax, a 14-gauge angiocatheter can be placed in the second intercostal space anteriorly to immediately relieve hemodynamic compromise. Continuous suction on the chest tube is maintained until the air leak ceases. Persistence of air leak may be seen in patients with a chronic underlying condition such as cystic fibrosis, bronchopulmonary dysplasia, lung cysts, or blebs. Treatment of these patients then requires resection of the diseased lung along with pleurodesis. Pleurodesis is usually performed by the administration of chemical irritants (talc, tetracycline) or mechanical rub through the thoracostomy tube, thoracoscope, or at thoracotomy. Talc is the agent of choice since it incites less pain and is more effective in treating pneumothorax in patients with cystic fibrosis. Pleurodesis is considered in any teenager after two episodes of spontaneous pneumothorax because of the high recurrence rate. Overall outcome is excellent after surgical treatment for pneumothorax.

### *Selected Readings*

1. Allen EM, van Heeckeren DW, Spector ML et al. Management of Nutritional and Infectious Complications of Postoperative Chylothorax in Children. *J Pediatr Surg* 1991; 26:1169-1174.
2. Rothenberg SS. Thoracoscopy in infants and children. *Semin Pediatr Surg* 1994; 3(4):277-282.
3. Merry CM, Bufo AJ, Shah RS et al. Early definitive intervention by thoracoscopy in pediatric empyema. *J Pediatr Surg* 1999; 34(1):178-180.
4. Chan W, Keyser-Gauvin E, Davis GM et al. Empyema thoracis in children: A 26-year review of the Montreal Children's Hospital experience. *J Pediatr Surg* 1997; 32(6):870-872.

# Patent Ductus Arteriosus

*Samer Kanaan and Daniel A. Bambini*

## Incidence

Patent ductus arteriosus (PDA) is the persistence in postnatal life of the ductus arteriosus. Overall, the incidence of PDA in term infants is approximately 1 in 2,000 live births. PDA, as an isolated lesion, accounts for about 5-10% of congenital heart disease. PDA affects girls twice as often as boys and frequently affects siblings suggesting a genetic component to etiology. PDA is particularly common in babies whose mothers contract rubella during the first trimester of pregnancy.

A high percentage of preterm infants have prolonged PDA after birth. The frequency of occurrence varies with gestational age and birth weight (BW). The incidence of PDA in premature infants born at 28-30 weeks of gestation is about 77%. Preterm infants born at gestational ages beyond 31 weeks have a lower incidence of PDA (i.e., 44% for 31-34 weeks vs. 21% for 34-36 weeks). Neonates born at weights less than 1000g have a high incidence (83%) of PDA, whereas, 47% of neonates with birth weights between 1000-1500 grams and 27% with birth weights between 1500-2000 grams have a PDA. However, only about half of PDAs in low birth weight infants (i.e., BW less than 1750 g) become hemodynamically significant.

## Etiology

The ductus is derived from the distal embryologic left sixth arch. In the normal fetal cardiovascular system, the ductus arteriosus connects the upper descending thoracic aorta and the proximal left pulmonary artery allowing oxygen-rich placental blood to bypass the fetal pulmonary circulation. In the normal fetal cardiovascular system, ductal flow is considerable and is directed exclusively from the pulmonary artery to the aorta. Although patent at birth, the ductus arteriosus spontaneously closes shortly after birth. Postnatal closure occurs in two stages. In full-term infants, the first stage is usually completed within 10-15 hours of birth as smooth muscle within the ductal wall contracts. The second stage of closure is usually completed by 2-3 weeks and results from diffuse fibrous proliferation of the intima. The ductus arteriosus is completely closed by 8 weeks in 88% of infants with an otherwise normal cardiovascular system. When closure is delayed or fails, patent ductus arteriosus results.

Ductus closure is mediated by:

1. release of vasoactive substances,
2. variations in pH,

3. increased oxygen tension, and
4. prostaglandins (PGE1, PGE2, PGI2).

Rising oxygen tension and prostaglandins produce opposite effects; increased partial pressure of oxygen (PO<sub>2</sub>) causes smooth muscle constriction while prostaglandins cause relaxation. The relative effects of oxygen and prostaglandins on the ductus varies at different gestational ages; the ductus is more sensitive to oxygen in the mature fetus and is more sensitive to prostaglandins in the premature fetus.

### Clinical Presentation

PDA occurs in four distinct forms:

1. an isolated cardiovascular lesion in an otherwise healthy infant,
2. an isolated cardiovascular lesion in a premature infant,
3. an incidental finding associated with more significant structural cardiovascular defects, and
4. a critical compensatory structure in cyanotic or left-sided obstructive lesions.

The signs and symptoms in PDA are related to left-to-right shunting. The magnitude of the shunt depends upon the size of the ductus and relative systemic and pulmonary vascular resistances. PDA is categorized as large, moderate, and small lesions.

For large PDAs, aortic and pulmonary artery pressures are essentially equal. After birth, the systemic vascular resistance remains fairly constant, therefore, the magnitude and direction of shunting depends mostly upon changes in pulmonary vascular resistance. As the pulmonary vascular resistance falls, left-to-right shunting rapidly develops and infants develop signs of severe congestive heart failure usually within a month. Signs include tachypnea, tachycardia, sweating, irritability, poor feeding, and slow weight gain. Pulmonary edema, pneumonia, or recurrent respiratory infections frequently occur. On examination, the precordium is "overactive" and associated with a systolic murmur and/or thrill (often continuous) that is maximal in the pulmonary area. Cardiac enlargement is suggested by a thrusting left ventricular apical impulse. The pulse pressure is widened and palmar pulses are frequently palpable. If the heart failure is severe, sometimes no murmur is heard. Hepatomegaly, jugular venous distention, and basilar rales can occur. If left untreated, cyanosis develops (usually by five years of age) as pulmonary vascular resistance increases above the systemic vascular resistance (Eisenmenger syndrome). Differential cyanosis may be noted with blueness of the feet and left hand, but not the face or right hand.

In moderate-sized PDA the shunt is regulated primarily by the size of the ductus arteriosus and the pulmonary artery pressure is only moderately elevated. As postnatal pulmonary vascular resistance falls, the shunt increases and heart failure occasionally occurs. Usually, compensatory left ventricular hypertrophy leads to clinical improvement and stabilization of symptoms by the second or third month of life. Physical developmental delay, breathlessness, and fatigue sometimes occur, but most children with moderate-sized PDA remain asymptomatic until the second decade of life. On examination, the pulse is jerky, the precordium is mildly overactive, and the apex of the left ventricle is palpable suggesting cardiac enlargement. The classical

continuous murmur is usually present by age 2-3 months. Eisenmenger syndrome does not routinely develop with this lesion.

In small-sized PDA the left-to-right shunt is small and pulmonary vascular resistance falls to normal after birth with no subsequent left ventricular failure. Symptoms are absent in infancy and childhood, but may appear much later in life as a murmur on physical exam. Physical development is normal, the pulse is normal, and the precordium is not overactive. The quality of the continuous murmur varies greatly and is sometimes only detectable when the patient sits or stands upright.

The differential diagnosis includes truncus arteriosus, aortopulmonary window, anomalous origin of the left or right pulmonary artery from the aorta, peripheral pulmonary stenosis, venous hum, and a centrally positioned arteriovenous malformation.

## Diagnosis

Patent ductus arteriosus suspected on physical exam can be reliably documented with echocardiography. Evaluation of left-sided chamber sizes and flow characteristics can provide an estimate of shunt size. The electrocardiogram is nonspecific but sometimes suggests left ventricular strain and hypertrophy, left atrial enlargement, and right ventricular hypertrophy. The chest radiograph shows cardiomegaly, plethora with or without interstitial pulmonary edema, or an enlarged ascending aorta.

## Treatment

In a term infant with a large PDA, spontaneous closure is extremely unlikely and treatment to physically close the PDA is indicated at the time of diagnosis. If symptoms are present, the procedure is done immediately. If no symptoms are present, elective closure is planned within three months. Because indomethacin and other medical interventions are not effective in term infants, some type of mechanical closure is needed. The usual approach is open surgical ligation, but recently other effective forms of therapy including transluminal placement of occlusive devices or thoracoscopic occlusion using metal clips have become more popular.

In premature infants, early closure of PDA is beneficial. Aggressive intervention is indicated once the diagnosis is established. The treatment for premature infants includes supportive therapy with nutritional support, volume restriction, diuretics, inotropic support, afterload reduction, ventilator support, and blood transfusion as indicated. Oral or intravenous indomethacin is then administered unless contraindicated. Failure to achieve closure of the ductus with indomethacin necessitates surgical ligation via a high left lateral thoracotomy. Tube thoracostomy following the procedure is optional.

Potential complications of PDA ligation include residual PDA, recurrent laryngeal or vagus nerve injury, pneumothorax, lung injury, chylothorax, and rarely ligation of wrong structure (i.e., aortic isthmus, left pulmonary artery, or left bronchus). Recurrent PDA following successful ligation is rare.

## Outcomes

In term infants, life expectancy is normal after surgical closure of an uncomplicated PDA during infancy or childhood. For children who are operated upon in infancy or childhood, the probability of early postoperative death is near zero. When



moderate or severe pulmonary vascular disease has developed preoperatively, late deaths occur due to progression of the pulmonary disease.

In preterm infants, overall surgical mortality (30 day) ranges from 10-30%. The mortality is not related to the interval between birth and operation but is more related to birth weight and gestational age. Only about one-half of premature hospital survivors of PDA ligation are alive and well 1-5 years later. About one-third have bronchopulmonary dysplasia and approximately one-sixth have severe complications of prematurity such as retrolental fibroplasia, blindness, and cerebral palsy.

The death rate from untreated PDA is estimated to be 30% in the first year of life. The risk of death (usually secondary to congestive heart failure) is highest in the first few months of life. Children with large PDAs who survive infancy without treatment frequently die in the second or third decade from acute or chronic right heart failure. For patients with untreated moderate-sized PDA, congestive heart failure causes death from the third and fourth decade onward. Subacute bacterial endocarditis sometimes occurs late in patients with small-sized PDAs.

### *Selected Readings*

1. Gross RE, Hubbard JP. Surgical ligation of a patent ductus arteriosus. Report of first successful case. *JAMA* 1939; 112:729.
2. Castaneda AR, Jonas RA, Mayer JE et al. Patent ductus arteriosus. In: Castaneda AR et al, eds. *Cardiac Surgery of the Neonate and Infant*. Philadelphia: W.B. Saunders 1994; 203-293.
3. Kirklin JW, Barratt-Boyes BG. Patent ductus arteriosus. In: Kirklin JW, Barratt-Boyes BG eds. *Cardiac Surgery: Morphology, Diagnostic Criteria, Natural History, Techniques, Results and Indications*. New York: Churchill Livingstone 1993; 841-859.

**Section XI: Congenital Malformations  
of the Chest Wall, Abdominal Wall  
and Perineum**

# Chest Wall Deformities

*Marieta Reynolds*

## **Pectus Excavatum**

### *Incidence and Etiology*

Of the congenital chest wall deformities, pectus excavatum (Figs. 77.1A and 77.1B) is the most common and occurs in approximately 0.2% of the population. Boys are affected more frequently than girls at a ratio of 4 to 1. The deformity usually presents at birth and becomes more prominent during the first few years of life. The defect can become more pronounced between 8 and 10 years and again during puberty. Children with severe deformities may have associated kyphosis and some degree of scoliosis. Pectus excavatum is also associated with congenital heart disease, lung cysts, Ehler-Danlos syndrome, Marfan's syndrome and some musculoskeletal anomalies. There is a familial tendency.

### *Clinical Presentation*

Symptoms related to a pectus excavatum vary depending on the severity of the lesion. There is some evidence that the moderate to severe deformities can compromise cardiorespiratory function. The symptoms of exertional dyspnea and tachycardia begin in the teens and become progressively worse. Decrease in exercise tolerance can develop.

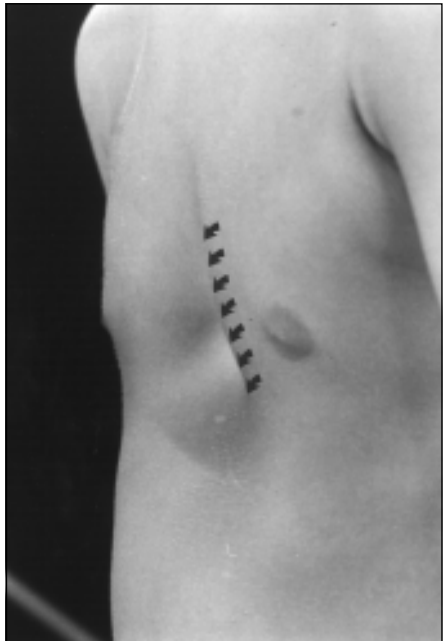
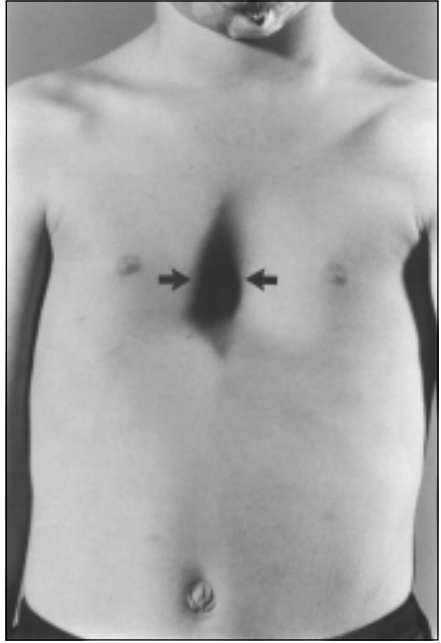
### *Diagnosis*

A child with a moderate to severe pectus excavatum should be evaluated with baseline pulmonary function studies, an echocardiogram to diagnose associated mitral valve prolapse and aortic root widening, and a CT of the chest with 3D reconstruction to demonstrate the full extent of the deformity.

### *Treatment*

After the initial evaluation, return office visits are scheduled on a yearly basis to quantify changes in the severity of the deformity and consider the most appropriate time for correction. Children with mild deformities are followed yearly until the lesion progresses or they reach their maximal growth in the late teens. Children with moderate or severe deformities may undergo surgical correction after 6 years of age. Surgical correction before 4 years of age has been shown to arrest chest wall growth causing cardiorespiratory symptoms in some children.

Fig. 77.1A and 1B. Two examples of pectus excavatum. Both are moderate in depression and in patients without symptoms other than complaints about the cosmetic appearance.



A new technique to repair a pectus excavatum deformity has been described. It entails placement of a bar behind the sternum through two small incisions. The bar is then flipped over and the deformity corrected. The bar is removed 2 years later. This technique shows promise and should be considered especially in children six to twelve years of age.

The standard operation to correct the pectus excavatum deformity includes subperichondrial resection of the deformed cartilage and an osteotomy of the sternum. Some type of temporary fixation of the sternum can be performed using stainless steel bars, Kirschner wires and other materials. Postoperative complications are rare and include wound infection, seroma or hematoma and recurrence of the deformity.

### **Pectus Carinatum**

Pectus carinatum or “pigeon” or “chicken” breast occurs much less frequently than pectus excavatum. Few physiologic studies have been performed on patients with pectus carinatum deformities. Preoperative evaluation is identical to that for pectus excavatum.

The surgical technique for repair of the carinatum deformity is tailored to the child’s anatomy. The cartilages are removed and at least one osteotomy of the sternum made. A wedge resection of the sternum may aid in bringing the sternum in line with the remainder of the chest. The intercostal muscle bundles may be reefed up to pull the sternum backward. Some surgeons use a metal strut or other device to fix the sternum in place. Complications and results are similar to the pectus excavatum repair.

### **Poland’s Syndrome**

Poland’s syndrome is manifested by congenital absence of the sternocostal head of the pectoralis muscle, hypoplasia of the breast, absent nipple, missing ribs and muscle, and syndactyly or absent fingers on the affected side. Preoperative evaluation should include a chest CT with 3D reconstruction; occasionally an arteriogram should be considered to evaluate the blood supply of local or distant combined flaps. The chest wall reconstruction is performed using rib grafts or local muscle flaps. The contralateral latissimus dorsi muscle can be used as a free tissue transfer. A breast prosthesis can be inserted to complete chest wall reconstruction. Follow-up MRI with 3D reformation can be used to evaluate the result.

### **Sternal Clefts and Ectopia Cordis**

The rare cleft, fissure or split of the sternum can be classified as superior, inferior or complete. These defects result from a failure of fusion of the sternum. Moderate size clefts can be primarily repaired. Larger defects may require rib grafts or artificial materials.

Ectopia cordis involves complete absence of the sternum with exposed heart. Few survivors have been reported since it is often associated with complex congenital heart disease. A rare successful repair was accomplished using a two-stage procedure. Initially, skin coverage of the heart was obtained with bilateral pectoral skin flaps. The second stage included placement of methyl methacrylate struts which were covered with bilateral pectoralis major muscle. Another repair was performed

in one stage using polytetrafluoroethylene membrane. Neither patient had associated congenital heart disease. In those patients with complex congenital heart disease, the skin coverage is done in the neonatal period and the cardiac defect is repaired at a later date.

### *Selected Readings*

1. Quigley PM, Haller, Jr. JA et al. Cardiorespiratory function before and after corrective surgery in pectus excavatum. *J Pediatr* 1996; 128:638-43.
2. Haller JA, Jr., Colombani PM, Humphries CT et al. Chest wall constriction after too extensive and too early operations for pectus excavatum. *Ann Thor Surg* 1996; 61(6):1618-24.
3. Nuss D. A 10-year review of a minimally invasive technique for the correction of pectus excavatum. *J Pediatr Surg* 1998; 33(4):545-52.
4. Beer GM, Kompatscher P, Hergan K. Poland's syndrome and vascular malformations. *Br J Plastic Surg* 1996; 49(7):482-4.
5. Knox L, Tuggle D, Knott-Craig CJ. Repair of congenital sternal clefts in adolescence and infancy. *J Pediatr Surg* 1994; 29(12):1513-6.
6. Kim KA, Vincent WR, Muenchow SW et al. Successful repair of ectopia cordis using alloplastic materials. *Ann Plastic Surg* 1997; 38(5):518-22.
7. Amato JJ, Zelen J, Talwalkar NG. Single-stage repair of thoracic ectopia cordis. *Ann Thorac Surg* 1995; 59(2):518-20.
8. Hornberger LK, Colan SD, Lock JE et al. Outcome of patients with ectopia cordis and significant intracardiac defects. *Circulation* 1996; 94(9 Suppl):1132-7.

# Abdominal Wall Defects

*Grant H. Geissler*

Abdominal wall defects represent unique challenges to pediatric surgeons and offer insight into normal fetal development. Omphalocele and gastroschisis are the major anomalies encountered in the neonate. The first description of an abdominal wall defect dates back to 1634, when Ambroise Paré first described an omphalocele—a defect in abdominal wall musculature and skin with protrusion of abdominal viscera contained within a membranous sac. Later, Calder described a child with gastroschisis—the defect in the abdominal wall was displaced to the right of the umbilicus and eviscerated bowel was not covered by a membrane. Survival of an infant born with an abdominal wall defect, especially gastroschisis, was unusual before the advent of modern antibiotics, nutritional support, and neonatal intensive care capabilities.

## Incidence

An accurate estimate of the incidence of gastroschisis and omphalocele is difficult to obtain due to the under reporting of stillbirths, confusion in defining ruptured omphaloceles as gastroschisis defects, and the voluntary terminations of pregnancies with sonographic evidence of abdominal wall defects. Reports from the United States suggest a combined incidence of 1 in 2000 live births, while estimates from Liverpool and British Columbia are closer to 1 in 4,000 live births. In the 1960s and 1970s, omphaloceles outnumbered gastroschisis 3:1, but over the last 20 years gastroschisis defects have predominated 2-3:1. This increase in incidence may represent increased selective termination of pregnancies of omphaloceles, more accurate classification of defects, or an actual increase in the gastroschisis birth rate. Males and females are equally affected by gastroschisis, and there may be a slight male predominance in omphalocele. No predilections based on race, maternal age, parity or geography have been substantiated.

## Etiology

No specific etiologies for abdominal wall defects have been identified in humans; however, an understanding of their embryology lends support to several theories.

## Omphalocele

At approximately the fourth week of gestation, the fetal abdominal wall is separated only by somatopleure, a thin membrane of ectoderm and mesoderm that is later replaced by simultaneous ingrowth of four mesodermal tissue folds in cranial,

caudad, and lateral to medial directions. Cranial downgrowth forms the thoracic and epigastric wall; caudad ingrowth forms the hypogastrium, bladder, and the hindgut. By the sixth week, further ingrowth occurs from lateral paravertebral myotomes. These ingrowths flatten medially to form the rectus abdominus muscles and fuse in the midline to complete enclosure of the abdominal cavity. It is theorized that the failure of ingrowth of lateral mesoderm gives rise to an arrested somatopleure defect characteristic of a standard omphalocele, and failure of ingrowth of cranial and caudad elements accounts for the spectrum of defects which accompany pentalogy of Cantrell, exstrophy of the urinary bladder, cloacal exstrophy, and imperforate anus. These fusion defects are thought to occur within the first 4-7 weeks of gestation and can be associated with other first trimester developmental anomalies and a 10-30% incidence of chromosomal anomalies (i.e., autosomal trisomies of 12, 18, and 21).

### *Gastroschisis*

Gastroschisis appears to arise from a specific weakness in the abdominal wall with secondary rupture and herniation of abdominal viscera. More rapid dissolution of the right umbilical vein occurs outside the standard period of organogenesis, leaving an area of relative weakness in the mesenchyme through which bowel or abdominal viscera can herniate and eventually rupture. This theory explains the 95% incidence of the defect being to the right of the umbilicus. Gastroschisis is usually an isolated mechanical defect and typically not associated with an increased incidence of other developmental anomalies.

## **Clinical Presentation**

### *Omphalocele*

At birth, omphalocele (Fig. 78.1) is recognized as a central defect of the abdominal wall beneath the umbilical ring. It is greater than 4 cm (defects less than 4 cm are generally called hernias of the cord) and is covered by a membranous sac or amnion. The umbilical cord inserts directly into the sac in an apical or occasionally lateral position. The sac may rupture in utero in 10-18% or from the delivery process in 4%. If the sac is intact, it contains normal appearing abdominal viscera including the liver in 48%. Giant omphaloceles have sacs that replace most of the abdominal wall, contain most of the intra-abdominal viscera, and have associated underdeveloped peritoneal cavity and pulmonary hypoplasia.

The incidence of associated major congenital anomalies has previously been estimated at 35%, but with improvement in neonatal survival, data collection, and imaging techniques, more recent series report associated anomalies in up to 81%. Cardiovascular defects are present in 20% of the patients and include tetralogy of Fallot, ASD, and VSD most commonly. Defects associated with cranial fold failure include congenital heart disease, diaphragmatic hernia, ectopia cordis, sternal cleft, and when all of these elements are present represent the pentalogy of Cantrell. Defects of caudad fold ingrowth may include imperforate anus, genitourinary malformations, bladder or cloacal exstrophy, colon atresia, sacral and vertebral anomalies, and meningomyelocele.



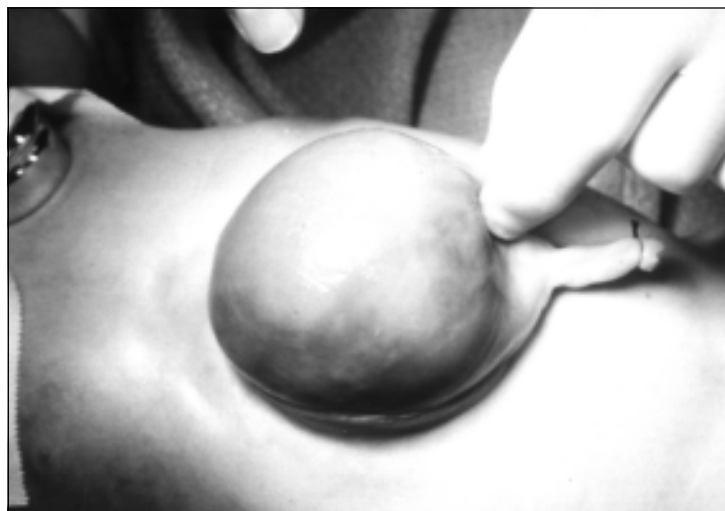

Fig. 78.1. Modest omphalocele with completely intact membrane and cord at inferior margin.

Syndromes associated with omphalocele include autosomal trisomies 13, 18, and 21 in up to 30%. Also associated is the Beckwith-Weideman syndrome consisting of macroglossia, hypoglycemia, and visceromegaly.

### *Gastroschisis*

At birth, gastroschisis (Fig. 78.2) is recognized by an isolated opening in the abdominal wall to the right (95%) of the umbilicus with free evisceration of abdominal contents. In utero exposure of bowel to amniotic fluid eventually causes thickening, shortening, and the development of a thick fibrous peel which seems accentuated with prolonged exposure and term deliveries. Associated defects are uncommon and relate mechanically to the abdominal wall defect. Evisceration of the bowel leads to malrotation. Constriction of the base of the herniated intestines may cause intestinal stenosis, atresia, and volvulus (usually ileal in location). Undescended testicles are also more common with this defect. Upon repair, intestinal edema, thickening, and the fibrous peel eventually resolve coinciding with resolution of a prolonged ileus that may last up to 4 weeks. Late appearance of necrotizing enterocolitis (NEC) has been reported in up to 17% of patients following standard repairs. Patients with gastroschisis are more likely to be born preterm or small for gestational age (SGA) compared to omphalocele patients who are usually term, large babies.

### **Treatment**

Prenatal diagnosis of an abdominal wall defect is not in itself an indication for a cesarean delivery. Prenatal management calls for an evaluation for associated anomalies including a complete fetal ultrasound and possible amniocentesis. For gastroschisis



Fig. 78.2. Gastroschisis without any signs of a membrane and demonstrating the inflammatory reaction and thickening of the bowel serosa that occurs on exposure to amniotic fluid.

patients, serial ultrasound examinations showing progressive dilatation and thickening of bowel has been correlated with poor intestinal function and is used in some centers as an indication for induction of labor.

Neonatal management begins with the preservation of eviscerated bowel or intact amnion with sterile moistened saline gauze dressings, transparent film wrap, or bowel bags. Intravenous fluids at 1.25-1.5 times maintenance and antibiotics are administered. Great care is taken to conserve body heat. A thorough examination for associated anomalies is performed including:

1. plain radiographs of the chest, spine and pelvis,
2. echocardiogram,
3. renal ultrasonography, and
4. chromosomal analysis.

### *Omphalocele*

Primary closure of the small to medium sized omphalocele is preferred. This includes excision of the sac, possible correction of the associated malrotation, and general inspection of the abdominal contents. Intraoperative alternatives to primary closure include prosthetic patch closure, simple closure of mobilized skin flaps, or placement of a silo for sequential tightening and staged closure. Giant omphaloceles or patients who are not suitable candidates for anesthesia may be treated with topical application of Betadine® ointment or silver sulfadiazine to the intact sac. This allows secondary eschar formation and eventual epidermal ingrowth. Residual abdominal wall hernias are then repaired at one year of age.

## *Gastroschisis*

Primary closure of gastroschisis usually begins with enlarging the abdominal wall defect to allow for the reduction of intestinal contents. The abdominal wall is gently stretched to enlarge the peritoneal cavity, and preoperative enemas may be helpful to decompress the colon. Severe matting of the bowel or peel formation may preclude an immediate repair of associated atresia or stenosis. These can be reduced and repaired in 6-8 weeks when the bowel injury/peel has resolved. In cases of volvulus and necrosis, nonviable bowel is resected. Bowel continuity is restored primarily or more rarely proximal enterostomies are performed as needed. Complete reduction of bowel contents under minimal pressure is preferable, but a prosthetic patch, skin flaps, or staged closure may be necessary. Parenteral nutrition is begun postoperatively and continued until adequate oral nutrition is attained. Careful postoperative fluid management, postoperative antibiotics, and adequate ventilatory support contribute to successful outcomes.

## **Outcomes**

Morbidity and mortality rates with omphalocele closure are closely tied to prematurity, large-sized defects, and major associated anomalies. Most modern series report survival rates from 71-93%. Children with gastroschisis often have a prolonged ileus, but once bowel function returns, these children thrive and ultimately do well since they have few associated anomalies. At present, survival rates are generally 90-95%.

Once children in both groups survive the neonatal surgery and achieve adequate levels of oral nutrition and growth, long-term survival depends almost exclusively on the presence of other anomalies and their associated morbidity rates.

## *Selected Readings*

1. Vermeij-Keers C, Hartwig NG, van der Werff JF. Embryonic development of the ventral body wall and its congenital malformations. *Sem Pediatr Surg* 1996; (5):82-9.
2. Dykes EH. Prenatal diagnosis and management of abdominal wall defects. *Sem Pediatr Surg* 1996; (5):90-4.
3. Snyder CL. Outcome analysis for gastroschisis. *J Pediatr Surg* 1999; (34):1253-6.
4. Rinehart BK, Terrone DA, Isler CM et al. Modern obstetric management and outcome of infants with gastroschisis. *Obstet Gynecol* 1999; (94):112-6.
5. Schuster SR. A new method for staged repair of large omphaloceles. *Surg Gynecol Obstet* 1967; (124):297-300.
6. Rowe MI et al. Abdominal wall defects. In: Rowe et al, eds. *Essentials of Pediatric Surgery*. St. Louis: Mosby 1995; 431-440.

# Anorectal Malformations

*P. Stephen Almond*

## Incidence

The incidence of imperforate anus is one in every 5,000 live births, with cloaca malformations accounting for 10%. Males (58%) are more commonly affected than females (42%).

## Etiology

In the third week of gestation, the embryo consists of an amniotic cavity and a larger yolk sac separated by a trilaminar disc consisting of ectoderm (amniotic side), mesoderm (middle), and endoderm (yolk sac side). The disc then begins a cranio-caudal folding process that tubularizes a portion of the endoderm into what will eventually become the hindgut. The hindgut joins the allantois and the mesonephric ducts to form the cloaca. At the end of the cloaca, endoderm of the cloaca is in direct contact with surface ectoderm creating the cloacal membrane. During development, this membrane moves posteriorly and inferiorly.

Cloacal division into rectum and urogenital tract is initiated by the caudal movement of tissue between the allantois anteriorly and the hindgut posteriorly. This cranio-caudal movement stops at the verumontanum. At seven weeks, cloacal division is completed by lateral ingrowth of mesenchyme, thereby completing the urogenital septum and forming the perineum. The perineum divides the cloacal membrane into the urogenital membrane anteriorly and the anal membrane posteriorly. Mesenchymal swellings then surround the anal membrane. The anal pit, a depression in the ectoderm at the anal membrane, develops in the eighth week and the membrane perforates in the ninth week.

Anorectal malformations occur when this process fails. The exact etiology of failure is currently unknown.

## Classification

Previously, infants with imperforate anus were classified based on the relationship of the rectal terminus to the levators. This was determined by inverting the infant and taking a transpelvic xray (invertogram). Rectal termini above the pubococcygeal line (a line drawn between the pubis and coccyx) are above the levators and designated high lesions. Termini between the pubococcygeal line and the lowest quarter of the ossified ischium (the "I" point) are translevator and designated intermediate lesions. Those below the "I" point traverse the levators and are designated low lesions.

More recently, a treatment-based classification system was proposed. In this system, infants are separated into two groups based on their need for a colostomy. Infants with a cutaneous fistula, anal stenosis, or anal membranes can undergo primary repair without protective colostomy. In contrast, those with rectourethral fistula, rectovesical fistula, anorectal agenesis without fistula, rectal atresia, vestibular fistula, vaginal fistula, or cloacal malformations require protective colostomy before primary repair.

### Clinical Presentation

Most infants with imperforate anus are referred because no anal opening is identified (Fig. 79.1) on the newborn screening exam or because of failure to pass meconium. Although most are healthy, full-term infants, associated congenital anomalies are common. These anomalies include vertebral anomalies, limb anomalies, heart defects, and Down's syndrome. The presence of any one of these mandates ruling out the others. The two most common cardiac anomalies associated with anorectal malformations are tetralogy of fallot and ventricular septal defects. Duodenal atresia and Hirschsprung's disease (2%) are occasionally identified in infants with anorectal malformations.

### Diagnosis

Imperforate anus is a clinical diagnosis. Inspect the perineum for meconium and/or a perineal fistula (Figs. 79.2 and 79.3). Determine gluteal and gluteal cleft development. Determine the presence or absence of an anal pit and the extent of sphincter development by eliciting an anal wink. This can be done by gently scratching the perianal skin. Preoperative tests are aimed at determining the presence of a fistula, the location of the rectal terminus, and if there are any associated lesions. To determine the presence and location of a cutaneous fistula, observe the newborn for 24-48 hours. Meconium on the perineum confirms a cutaneous fistula and a low lesion (Figs. 79.4 and 79.5). If there is no meconium, place a radiopaque marker on the perineum and obtain a prone, cross-table lateral xray of the pelvis. Air, acting as a contrast medium, will delineate the rectal terminus and differentiate a low vs. high lesion. To determine the relationship of the urinary tract to the rectum, strain the urine with diaper or gauze and obtain a urinalysis. Meconium in the urine documents a communication between the bowel and the urinary tract. A voiding cystourethrogram (VCUG) will document the fistula. Passage of a nasogastric tube (esophageal atresia), cardiac echo (cardiac anomaly), abdominal ultrasound (renal agenesis), plain films (vertebral anomalies), spine ultrasound and lumbar magnetic resonance imaging (tethered cord) will rule out associated anomalies. Female infants with a single perineal opening, or cloaca, need urgent evaluation of the urinary tract.

### Treatment

The infant is kept NPO, on peripheral hyperalimentation and antibiotics until colostomy or primary repair is performed. Infants with a cutaneous fistula, anal stenosis, or anal membrane undergo a minimal posterior sagittal anorectoplasty (PSARP) or a transposition anoplasty (Pott's anoplasty). Infants with a flat bottom, meconium in the urine, or other fistula (i.e., urethral, vaginal, vestibular) undergo

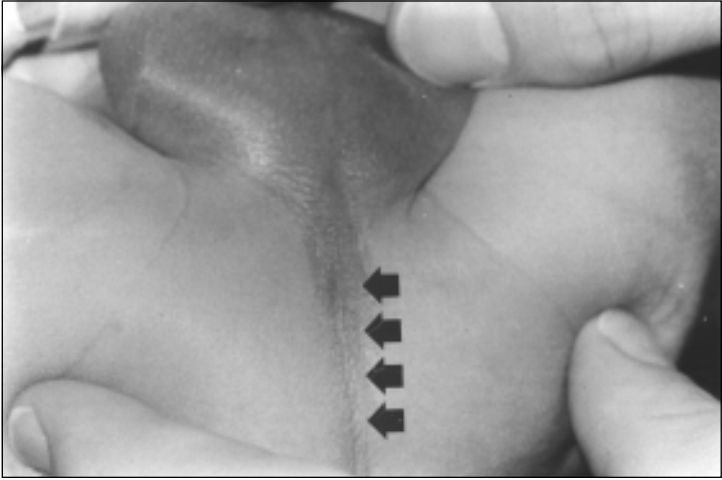
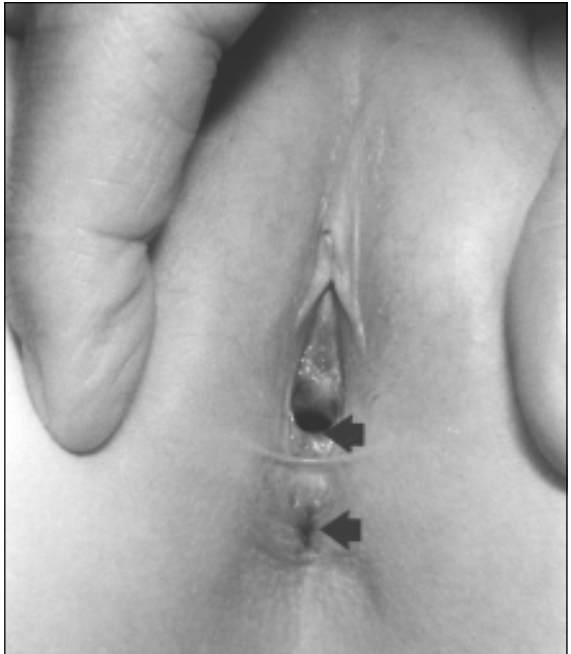

Fig. 79.1. High imperforate anus in a male. Median raphe is flat and without any signs of meconium extrusion

Fig. 79.2. Young female with anterior ectopic anus. Arrows mark the posterior edge of the vaginal opening and the anus. These two structures are too close, and the anal opening lies outside the anal dimple.



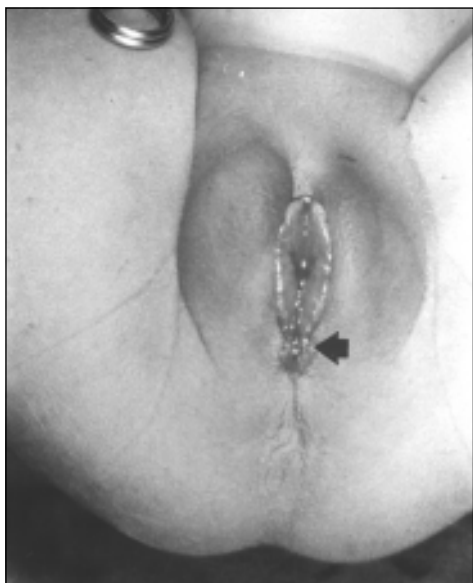

Fig. 79.3. Low imperforate anus in a female with fistula visible at the posterior fourchette (vestibular fistula).

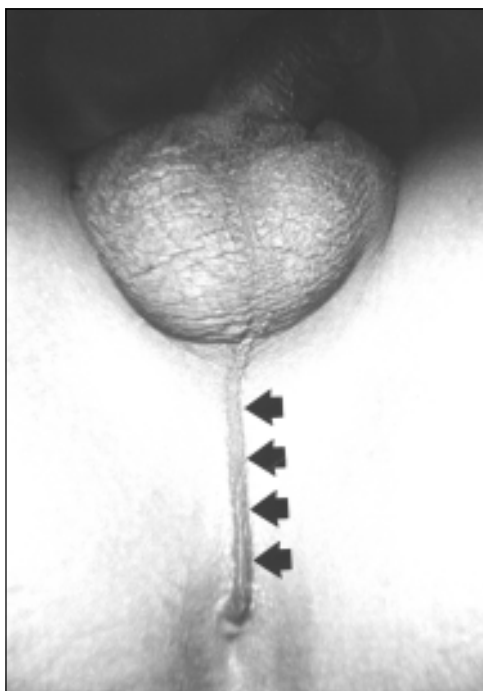
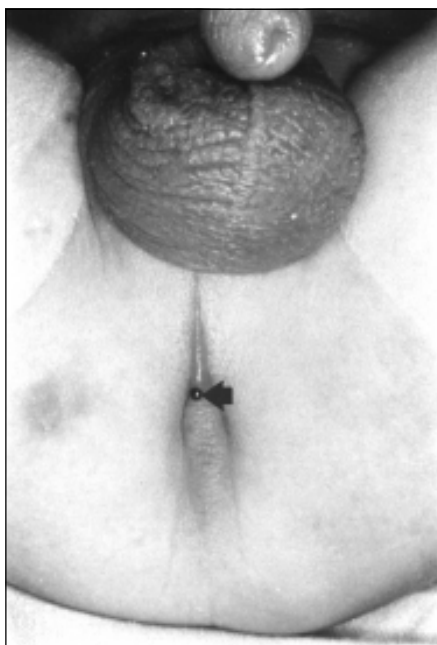


Fig. 79.4. Low imperforate anus in a male. Well developed raphe that will probably demonstrate fistula with meconium extrusion over first 1-2 days of life.

Fig. 79.5. Low imperforate anus in a male. "Bucket handle" shown at site of covered anus with small amount of meconium extruding (arrow).



colostomy. Females with a cloaca also undergo colostomy, and if necessary, vaginostomy and/or urinary diversion. Postoperatively, the mucous fistula is irrigated (to remove impacted meconium) and a distal colostogram is performed to show the distal rectum and fistula (Fig. 79.6). The child is then followed closely to insure weight gain and adequate colostomy function. If all goes well, a PSARP is performed between 2 and 12 months of age.

Throughout the operation, an electrical stimulator is used to determine the exact location of the external sphincter and insure that dissection stays in the midline. The muscle complex and levators are divided, the rectum is identified and opened, and the fistula is identified. Because there is no dissection plane between the urethra and rectum at the fistula, a small portion of the anterior wall of the rectum is left on the urethra, and the rectum is separated from the urethra superiorly. The fistula is closed; the rectum is mobilized and pulled down to the perianal skin. The perineal body is reconstructed anteriorly and the rectum is secured within the muscle complex fibers. The anoplasty is completed with interrupted absorbable suture.

The first morning following the reconstruction, the child is fed and converted to oral pain medication. The Foley catheter and IV antibiotics are continued for five days. The child is discharged after spontaneous voiding. At two weeks, the anus is sized with a Hagar dilator in the office and the mother/caregiver is instructed on home dilatations. The colostomy may be closed six weeks later.



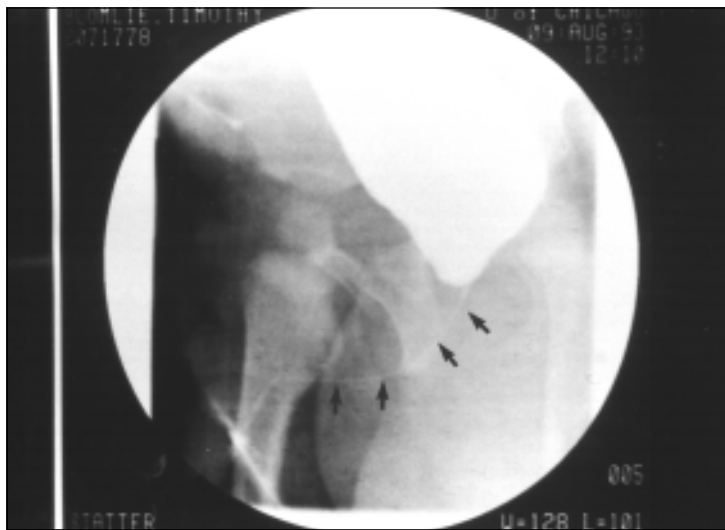


Fig. 79.6. High imperforate anus in a male undergoing colostogram. Arrows trace the path of the colourethral fistula.

### Outcomes

Results depend upon the level of the lesion and the sacrum. In general, infants with low lesions have an excellent outcome with constipation (40%), soiling (13%), and diarrhea (4%) accounting for the majority of complications. Infants with high lesions have a higher incidence of these complications: constipation (35%), soiling (54%), diarrhea (12%).

### Selected Readings

1. Pena A. Anorectal malformations. *Seminars in Pediatric Surgery* 1995; 4:35-47.
2. Pena A. Surgical management of anorectal malformations: A unified concept. *Pediatr Surg Int* 1988; 3:82-93.
3. Kiely EM, Pena A. Anorectal malformations. In: O'Neill Jr. JA et al, eds. *Pediatric Surgery*, 5th edition. St. Louis: Mosby, 1998; 1425-48.
4. Shaul DB, Harrison EA. Classification of anorectal malformations' initial approach, diagnostic tests, and colostomy. *Sem Pediatr Surg* 1997; 6:187-195.

# Urogenital Sinus, Cloaca, and Cloacal Exstrophy

*Robert M. Arensman*

## Definitions

These three rare congenital anomalies represent various stages of arrested development of abnormal embryogenesis. In infants with urogenital sinus, final development and separation of the urinary and genital structures fail to occur so that the urethra and vagina share a common external orifice. In cloaca, the arrested development produces a situation that has urethral, vaginal, and rectal openings all sharing a common single external orifice. The faulty embryogenesis in cloacal exstrophy compounds the problem by rupture onto the anterior abdominal wall. These children have a central exposed bowel field with 1-4 orifices (ileum, colon, appendix(ces)), divided hemibladder fields, an omphalocele, and imperforate anus.

## Embryogenesis

Complex development of two membranes (cloacal membrane and urorectal septum) creates the separation of the anterior urogenital structures from the posterior rectal structures. Arrested development of these processes appears to explain and create urogenital sinus and cloaca. However, some further problem arises to create cloacal exstrophy. The exact nature of this problem is currently unknown; and although there are two prominent theories, neither has much proof for support at this time.

## Incidence

All three conditions are rare, even in large children's medical centers. The incidence varies from 1:150,000 to 400,000 live births. At present only 20-30 yearly cases of cloacal exstrophy are expected in the United States. Male to female predominance has been recorded as high as 2.5:1.

## Associated Anomalies

These children have normal intelligence and grow well unless the rare problem of short bowel occurs. However, they all have a host of associated anomalies, especially in four areas: genitourinary, gastrointestinal, vertebral, and lower extremity. As many as 70-85% of these infants have anomalies remote from the basic defect. Most common are hydronephrosis or hydroureter, renal agenesis, pelvic kidney, duplications or crossed fused ectopia.

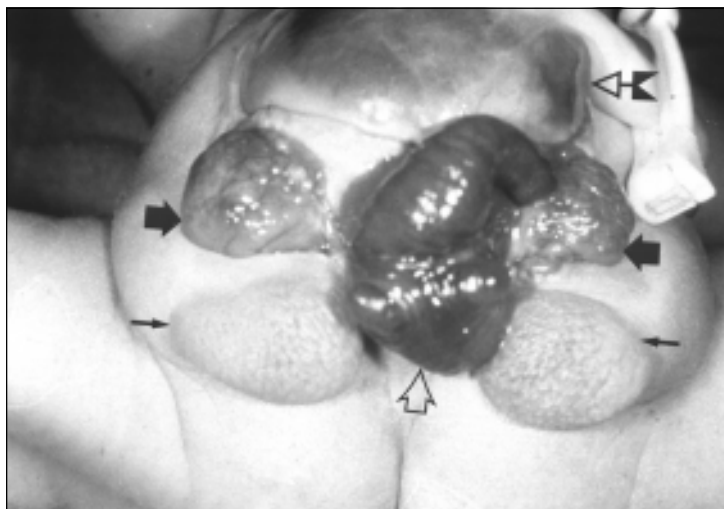


Fig. 80.1. Typical cloacal exstrophy with: 1) omphalocele (black and white arrow), 2) divided bladder (large solid arrows), 3) central bowel mucosa (large white arrow) with intussuscepted small bowel, and 4) labia (small black arrows).

The associated gastrointestinal anomalies consist of malrotation, atresia/stenosis, duplications, Meckel's diverticula, absent or double appendix, and rarely short bowel syndrome. Vertebral anomalies include myelodysplasia absent segments, and hemivertebrae. Central nervous system disorders other than myelodysplasia are rather rare. Finally, lower extremity malformations are present in up to 25% of these children and include such things as clubfeet, dislocated hips, or missing portions of a lower limb.

### Diagnosis

Most of these infants can be correctly diagnosed on physical examination alone. In females, failure to confirm three perineal orifices with proper anatomic relationships allows a very accurate preliminary diagnosis. Diagnostic studies are needed to document extent of urogenital and rectal fusion and the presence of associated anomalies. In most cases, ultrasonography is done initially to seek evidence for obstruction in the urinary system or vaginal atresia with hydrocolpos. This is followed by contrast injections via orifices. Skeletal radiographs are done, and the spine is imaged with ultrasound and/or magnetic resonance imaging (MRI) to evaluate for possible tethered cord.

### Treatment

The first phase of treatment depends on making an accurate diagnosis and assessing whether the infant is strong, has favorable anatomy and a lack of associated

anomalies. If these conditions are met, single stage repair may be undertaken in the neonatal period. If these conditions are not met, it is advisable to plan for a multi-stage repair perhaps extending over several years. In any event, there are reliable operations for each of the anomalies comprising these conditions. Most of the conditions can be corrected or greatly improved. In general, the principle of repair is to separate the various systems and repair them as well as possible. Continence in urinary or bowel function cannot be guaranteed but is frequently improved. If control is not satisfactory for the future, reasonable forms of diversion allow functionally acceptable results.

## Results

Survival and good neurological outcome are common for these children. Most long-term problems are associated with urinary and bowel function. Results are mixed with only about half of these children achieving satisfactory control through sphincter use. The rest are reconstructed with drainage procedures, pouches, or permanent ostomies that allow a functional status in society.

### *Selected Readings*

1. Spencer R. Exstrophia splanchnica (exstrophy of the cloaca). *Surgery* 1964; 57:751-766.
2. Hendren WH. Repair of cloacal anomalies: Current techniques. *J Pediatr Surg* 1986; 21:1159-76.
3. Hendren WH. Further experience in reconstructive surgery for cloacal anomalies. *J Pediatr Surg* 1982; 17:695-717.
4. Pena A, deVries PA. Posterior sagittal anorectoplasty: Important technical considerations and new applications. *J Pediatr Surg* 1982; 17:796-811.
5. Warner BW, Ziegler MM. Exstrophy of the cloaca. In: Ashcraft KW, Holder TM eds. *Pediatric Surgery*, 2<sup>nd</sup> Edition. Philadelphia: W.B. Saunders Company 1993; 393-401.

## **Section XII: Functional and Acquired Disorders of the Esophagus**

# Gastroesophageal Reflux

*Grant H. Geissler*

## Introduction and Incidence

Although all infants and children vomit occasionally, the term gastroesophageal reflux is reserved for more severe, prolonged or symptomatic emesis not related to anatomic obstruction or acute illnesses. Isolated gastroesophageal reflux occurs most frequently in the first 9-12 months of life but can arise anytime during childhood. Infantile gastroesophageal reflux frequently improves spontaneously around one year of age as

1. the lower esophageal sphincter (LES) tone improves,
2. the child adopts a more upright posture,
3. the child uses abdominal muscles as accessory muscles of respiration less, and
4. the child progresses to a general diet.

Specific diagnostic evaluations, medical and surgical treatments are usually reserved for patients with pathologic reflux, defined as reflux which causes injury to another organ system (i.e., esophagitis, pneumonia) or causes failure of the infant or child to thrive. Approximately 1 in 300-1000 children have excessive, passive reflux across an incompetent LES and require medical or surgical therapy.

## Embryology and Anatomy

The esophagus is composed of cervical, thoracic, and intra-abdominal segments and arises from the embryologic foregut. Its separation from the respiratory system and relation to the stomach and diaphragm is completed between the fourth to seventh week of fetal gestation. The esophagus travels through the esophageal hiatus in the diaphragm bounded laterally by the diaphragmatic crura. The esophagus enters the stomach forming an acute angle known as the angle of HIS.

The lower esophageal sphincter is a physiologic high pressure zone located in the intra-abdominal esophagus adjacent to the body of the stomach. LES dysfunction, widening of the angle of HIS, paraesophageal or sliding hiatal hernias, or decreased gastric mobility may all contribute to the development of pathologic gastroesophageal reflux. In addition, decreases in distal esophageal motility may impair clearance of refluxed gastric contents.

Children with neurological impairments are more commonly afflicted with pathologic gastroesophageal reflux.

## Clinical Presentation

Clinical symptoms of gastroesophageal reflux arise from prolonged exposure of esophageal squamous mucosa to gastric acid, aspiration of gastric contents into the airway, or growth impairment secondary to inability to hold down adequate nutrition. The younger patients tend to have more respiratory complications of pathologic gastroesophageal reflux, while older patients more commonly present with esophageal symptoms.

Respiratory symptoms may be difficult to attribute solely to reflux but include bronchospasm, laryngospasm, hoarseness, pneumonia, apnea, and choking spells. Reflux has been suspected as a contributing factor to sudden infant death syndrome (SIDS) or acute life threatening event (ALTE) apnea. Multichannel recording of esophageal pH, heart rate, respiratory rate, and EEG have linked drops in esophageal pH immediately preceding apneic events. Recurrent aspiration pneumonia may follow either an upper posterior or lower posterior lobe pattern, and bronchoscopy may disclose laryngeal edema and airway washings filled with lipid-laden macrophages. Coughing, choking, or wheezing symptoms may worsen at night when the child is recumbent, and gastric acid is not buffered by food. Poor sleep patterns, dental caries, and recurrent otitis media has been associated with severe gastroesophageal reflux in children.

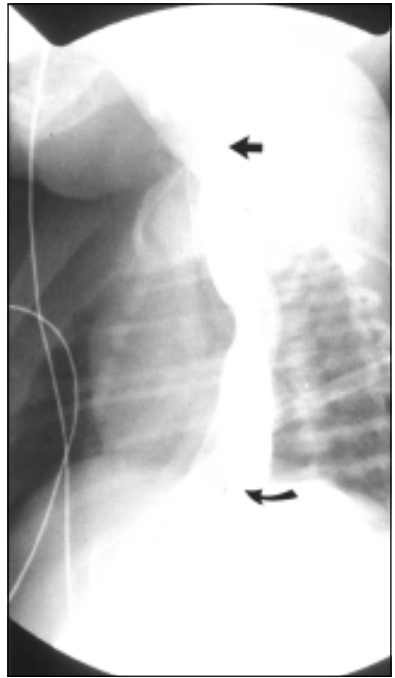
Esophageal symptoms arise from the prolonged contact of esophageal mucosa with gastric acid. Esophagitis may be manifest as irritability in infants and heartburn in older patients. Esophagitis may be mild and only discovered by esophageal biopsy or may progress to gross inflammation, ulceration, and eventual stricture formation. Columnar metaplasia is an adaptive response to repetitive esophageal irritation and is commonly known as Barrett's esophagitis. This metaplasia may predispose to adenocarcinoma of the esophagus, especially when evidence of dysplasia is present. Hematemesis, heme positive stools, and chronic iron deficiency anemia also arise from ongoing esophagitis. Sandifer's syndrome refers to voluntary arching of the back and neck to improve peristalsis and improve esophageal emptying. Children with neurological impairment, diffuse foregut dysmotility, or esophageal atresia may have esophagitis from motility disturbances which alter LES function and impair clearance of refluxed acid from the esophageal mucosa. Delayed gastric motility may also contribute to pathologic reflux, especially in patients with neurological impairment.

Nutrition lost from repetitive vomiting may be so profound and cause growth disturbances. Patients are particularly prone to vomit with coughing, exertion, crying, or after feeding. Since eating promotes reflux, some children with esophagitis and pain avoid eating voluntarily to reduce discomfort.

## Diagnostic Studies

Once pathologic gastroesophageal reflux is suspected, diagnostic evaluation usually begins with a barium upper GI examination. The value of this study is to explore anatomic problems (esophageal stricture, hiatal hernia), evaluate esophageal position, stomach size, and to exclude outflow obstructions such as duodenal malformations or malrotation. Since barium is not a physiologic medium and the test is of limited duration, the absence of demonstrable reflux does not exclude it and the study may be normal in up to 50% of the known refluxers. Esophageal pH monitoring

Fig. 81.1. Severe case of gastroesophageal reflux with wide open lower esophageal sphincter (curved arrow) and reflux to the thoracic inlet (short arrow).



is a more accurate study to document suspected gastroesophageal reflux. A pH probe is placed in the distal esophagus and continuous monitoring of esophageal pH over a 24 hour period is performed. The frequency of reflux episodes (esophageal pH  $\leq$  4) and specific duration of episodes is quantified.

Nuclear medicine scans may be useful in diagnostic and operative planning. Esophageal scintiscans are performed by placing a known quantity of radioisotope in the stomach. Serial scans quantitate the amount of isotope refluxed into the esophagus, thereby documenting gastroesophageal reflux. Gastric scintiscans employ similar isotopes, but the rate of gastric emptying is measured as the isotope travels distally out of the stomach. Significant delays in emptying may warrant additional prokinetic medication or a gastric drainage procedure.

Esophagoscopy is a final diagnostic that is used to evaluate patients with gastroesophageal reflux. Esophageal biopsies confirm esophagitis, quantitate degrees of severity, or detect presence of columnar metaplasia. Anatomic problems such as ulcers, strictures, or hiatal hernias can also be documented.

### Medical Therapy

Once a diagnosis of pathologic gastroesophageal reflux is secured, medical therapy is instituted. This includes dietary modification (i.e., formula changes, thickened feeds), adoption of an upright posture for eating and in the postprandial period, and avoidance of positions that increase intra-abdominal pressure. Administration of



antacids minimizes the inflammatory effect of gastric acid on esophageal or bronchial mucosa. Prokinetic medications (i.e., cisapride, metoclopramide) may improve esophageal peristalsis, increase gastroesophageal tone, improve gastric emptying, and have been helpful in controlling gastroesophageal reflux when combined with other medical modalities. A combination of these modalities controls reflux in up to 90-95% of children.

### **Surgical Therapy and Long-Term Results**

Surgical therapy is employed to control gastroesophageal reflux when medical therapy of appropriate dose and duration fails, or when severe life threatening events preclude a medical approach. The goal of surgical therapy is to restore the normal anatomic relationship of the gastroesophageal junction within the abdomen, repair hiatal hernias if present, recreate the angle of His, and improve gastric emptying if necessary.

Fundoplication procedures are the current operation of choice for surgical control of gastroesophageal reflux. Two approaches are commonly employed, the Nissen or Thal fundoplication. A large variety of other surgical repairs are rarely used in children.

A Nissen fundoplication involves a retroesophageal crural repair, followed by a 360° wrap of the gastric fundus around the esophagus. The fundus is sutured to itself and to the esophagus anteriorly. Care is taken to avoid vagal nerve trunks. A "loose" Nissen wrap is preferred. A Maloney dilator is placed within the esophagus to fully dilate it and prevent narrowing while the wrap is constructed. Nissen wraps control reflux in up to 92% of patients, but may require revision in 12% (i.e., slipping or loosening with recurrent reflux), and eventually in up to 30% of patients who are neurologically impaired.

A Thal fundoplication also begins with a crural repair, but then the gastroesophageal junction is mobilized and pulled downward into the stomach. The fundus is sutured to the esophagus and hiatus circumferentially. This approach may allow more patients to burp and vomit to some degree postoperatively, provides greater than 90% control of reflux symptoms, but may have a higher recurrence rate over time.

Reoperative surgery may be performed if reflux symptoms recur following previous successful fundoplication. Redo fundoplication rates range from 5-20% routinely and are higher in patients with neurologic impairment.

### ***Selected Readings***

1. Fonkalsrud EW, Ament ME, Berquist W. Surgical management of the gastroesophageal reflux syndrome in childhood. *Surgery* 1985; 97:42.
2. Ashcraft KW, Holder TM, Amoury RA. Treatment of gastroesophageal reflux in children by Thal fundoplication. *J Thorac Cardiovasc Surg* 1981; 82:706.
3. Pearl RH et al. Complications of gastroesophageal antireflux surgery in neurologically impaired versus neurologically normal children. *J Pediatr Surg* 1990; 25:1169.
4. Wheatley MJ et al. Redo fundoplication in infants and children with recurrent gastroesophageal reflux. *J Pediatr Surg* 1991; 26:758.
5. Boix-Ochoa J, Rowe MI. Gastroesophageal reflux. In: O'Neill Jr. JA ed. *Pediatric Surgery*, 5<sup>th</sup> Edition. St. Louis: Mosby 1998; 1007-1028.

# Achalasia

*David Bentrem*

## Incidence

Achalasia is a functional disorder in which the lower esophageal sphincter (LES) fails to relax with swallowing. The incidence of achalasia in children is one case per 10,000. Consequently, only 2-5% of all reported cases of achalasia occur in children. In contrast to adults, boys are more commonly affected than girls (1.6:1). Most major pediatric centers encounter less than one case per year.

## Etiology

The etiology of achalasia is poorly understood in either children or adults. Ganglion cell defects within the myenteric plexus of the lower two thirds of the esophagus and a lack of nitric oxide synthase activity in the lower esophagus, cardia and gastric fundus are both postulated. But neither theory is confirmed, and a direct cause/effect relationship has not been established.

Less commonly, secondary achalasia results from diseases of the vagal dorsal motor nuclei (i.e., polio, diabetic autonomic neuropathy, amyloidosis, sarcoidosis). In Chagas' disease, *Trypanosoma cruzi* destroys the myenteric plexus of the esophagus causing symptoms and clinical findings similar to achalasia.

## Pathophysiology

Normally, the LES remains tonically constricted (with an intraluminal pressure of about 30 mmHg) in order to prevent reflux of highly acidic gastric contents into the esophagus. With swallowing, "receptive relaxation" of the LES precedes the peristaltic wave. In achalasia the musculature of the lower esophagus remains spastically contracted, and the LES fails to relax as food approaches. Over time, the esophagus becomes tremendously dilated. Chronic inflammation and ulceration of the mucosa from stasis, causes severe pain, and puts the child at risk for rupture.

## Clinical Presentation

The onset of symptoms is usually before 15 years of age with a mean of 8-9 years. The primary symptoms are:

1. progressive dysphagia of first liquids and then solids,
2. vomiting, and
3. retrosternal pain.

As the disease progresses and the proximal esophagus becomes distended, children vomit retained food and liquid. The onset of symptoms is often insidious.

Because the disease is so rare, the diagnosis is frequently delayed, and the symptoms are attributed to psychological problems. Younger children fail to gain weight, and teenagers lose weight over a period of several months. Nocturnal regurgitation may result in recurrent pneumonias.

## Diagnosis

A dilated esophagus with an air-fluid level on plain chest radiograph is suspicious for achalasia. The same radiograph may also demonstrate signs of recurrent aspiration pneumonitis. A barium swallow outlines a dilated esophagus that narrows concentrically to a "beak" at the cardioesophageal junction. Fluoroscopy can demonstrate disordered and retrograde peristalsis in the dilated proximal esophagus.

Endoscopy is used to exclude a congenital cause for the abnormally dilated esophagus. Esophagoscopy demonstrates concentric narrowing of the distal esophagus, often without signs of esophagitis. The LES will relax to allow passage of the scope into the stomach, ruling out congenital stricture, cartilaginous remnants of the esophageal wall, or stenosis secondary to gastroesophageal reflux disease (GERD). Definitive diagnosis is made by esophageal manometry. Manometric studies confirm the three major abnormalities of achalasia:

1. aperistalsis,
2. incomplete relaxation of the LES with swallowing, and
3. increased resting tone of the LES.

Hyperperistalsis, disorganized peristalsis and retrograde peristalsis are occasionally observed.

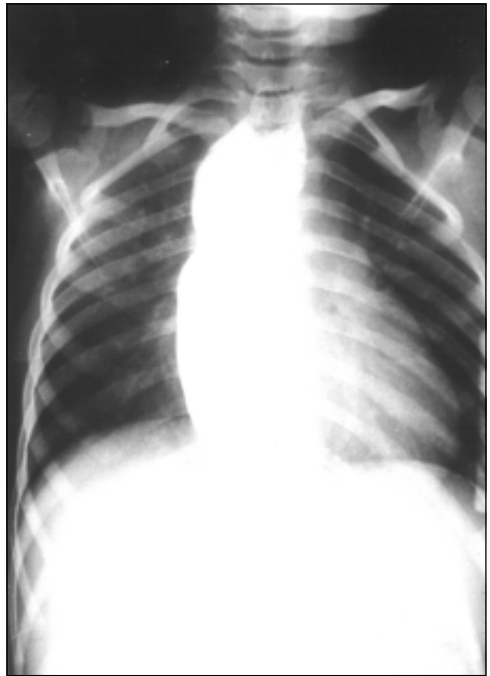
## Treatment

The goal of treatment is to relieve the functional obstruction. Pharmacologic treatment is based on relaxing smooth muscle. Isosorbide dinitrate and nifedipine have been used with some success in adolescents; however, side effects and transient responses have limited the use of drugs. Balloon dilatation is sometimes used as first line therapy in all ages. Dilatation offers temporary relief with improvement in 50%, but long term results have been unsatisfactory in children with recurrence rates as high as 25-30%. Repeated dilations creates increasing risk of esophageal perforation. Injection of botulin toxin into the LES has been tried in small series of adults and older children with good results, but requires repeated injections. Larger series are needed to confirm the initial success rate.

The basis of all surgical procedures is the cardiomyotomy described in 1914 by Heller. The Heller myotomy provides excellent long-term relief of achalasia but is complicated by gastroesophageal reflux in up to 6% of cases. Preoperative esophagoscopy is done to ensure complete evacuation of retained food. Then, the standard Heller operation is carried out through a left thoracotomy (7<sup>th</sup> intercostal space). Upper transabdominal, laparoscopic, and thoracoscopic approaches are all possible and increasingly reported. An antireflux procedure may be done with the Heller myotomy.

To perform the myotomy, the distal esophagus is mobilized, encircled with a tape, and freed at the esophageal hiatus, so that the gastroesophageal junction is adequately visualized. The muscle fibers are separated longitudinally down to the underlying mucosa. The myotomy incision extends from the middle/distal esophagus

Fig. 82.1. Massive esophageal dilation secondary to achalasia, spasticity of the lower esophagus that prevents successful swallowing.



down onto the stomach. A gastric flap (greater curvature) can be sutured over the esophageal mucosa or some form of antireflux procedure may be used to cover the myotomy. In an international survey of pediatric surgeons, an antireflux procedure was performed in 75% of patients with a transabdominal myotomy but in only 17% with a transthoracic myotomy.

Manometry done after the operation confirms dramatically decreased sphincter tone and improved esophageal motility in most patients. In children with achalasia, esophageal myotomy has a 95% overall success rate with relief of symptoms and weight gain.

### *Selected Readings*

1. Raffensperger JG ed. Achalasia. In: Swenson's Pediatric Surgery, 5<sup>th</sup> edition. New York: Appleton & Lange 1990.
2. Heller E. Extramuköse cardioplastik vein chronischen cardiospasmus mit dilation des oesophagus. Mitt Grenzgeb Med Chir 1913; 27:141-8.
3. Lelli JL, Drongowski RA, Coran AG. Efficacy of the transthoracic modified Heller myotomy in children with achalasia—a 21-year experience. J Pediatr Surg 1997; 32(2):338-41.

# Caustic Esophageal Injury and Perforation

*Christina L. Dial and Daniel A. Bambini*

## Incidence

Caustic ingestion results in approximately 5,000-15,000 esophageal injuries per year in the United States. Most caustic esophageal injuries (50-80%) occur in children and 39% occur in children under age 5. Caustic ingestions in the young children are considered "accidental," but ingestions in adolescents and young adults are often intentional (i.e., suicide attempt, "dare"). Boys are more frequently affected in children less than 5 years; whereas, girls are the more likely victims during adolescence.

## Etiology

The type and extent of injury resulting from ingestion of a caustic solution depends upon:

1. the type of agent,
2. its physical state (i.e., liquid, solid),
3. concentration,
4. the amount ingested, and
5. the duration of contact with the esophageal or gastric mucosa.

The most common substances implicated in corrosive burns of the esophagus are alkaline caustics, household bleaches, and acid or acid-like corrosives. Alkaline caustics containing sodium hydroxide, potassium hydroxide, or sodium bicarbonate are found in household lyes (granular or liquid), drain cleaners, and washing soda. Dishwashing detergent and household cleaners frequently contain sodium metasilicate and ammonia. Acids (i.e., sulfuric, oxalic, hydrochloric) are found in batteries, paint thinners, and other solvents. Hair dye solutions often contain potassium permanganate which also causes injury to the esophagus.

Alkalines, including dishwashing detergents, household bleaches, and laundry detergents, are the most frequently ingested caustic agents. Most cause only limited injury to the esophageal mucosa without extensive necrosis or subsequent sequelae. Strong alkaline products (i.e., drain cleaners) containing lye are odorless, tasteless, and can lodge in the oropharynx or upper esophagus causing severe damage, necrosis, or perforation. If the alkaline solution is a viscous liquid, the oropharynx may be spared but the damage may extend from the mid-esophagus distally to the esophagogastric junction.

Strong acids frequently have a bitter taste, emit a strong odor, and burn on contact, which often results in rapid expulsion after ingestion. When swallowed, acids

usually causes significant damage to the stomach and variable mucosal damage to the esophagus. The duodenum and proximal small bowel are relatively well-protected by the pylorus.

### **Classification and Pathophysiology**

Injury to the mucosal surfaces occurs within seconds of the insult. Caustic injuries to the esophagus are classified similarly to thermal burn injuries of the skin (Table 83.1). The nature of the injury differs between acid and alkali ingestion. Alkali ingestion causes liquefaction necrosis with destruction of the epithelium, submucosa and sometimes the muscularis. Even though an eschar forms and neutralization occurs, continued destruction of the deeper layers is still possible following alkali ingestion. Following acid ingestion injuries, coagulation necrosis occurs and a hard eschar is formed. This may limit the damage to the mucosa.

Caustic ingestion injuries evolve through three phases:

1. the acute phase,
2. the subacute phase, and
3. the cicatrization phase.

The acute phase (0-4 days) is characterized by the presence of inflammation, edema, thrombosis, eschar formation, and necrosis. The subacute phase or reparative phase occurs between 5 and 14 days following the injury. During this phase necrotic tissue is sloughed, fibroblasts are deposited, and neovascularization begins. The esophageal wall is weakest during the subacute phase and prone to perforation. The cicatrization phase occurs between 3 and 6 weeks following injury. Fibrous tissue replaces the submucosa and muscularis forming dense scar that results in strictures, obliteration, or shortening of the esophagus.

### **Clinical Presentation**

The clinical presentation of children following caustic ingestion is highly variable. Signs and symptoms include drooling, burning pain in the mouth and lips, odynophagia, dysphagia, hoarseness, stridor, and aphasia. Esophageal perforation is often associated with symptoms of severe retrosternal, back, or upper abdominal pain. Fever, tachycardia, and hypotension are signs of severe esophageal injury and often indicate massive ingestions. Physical signs of caustic ingestion include ulceration or discoloration of the oropharyngeal mucosa, cervical crepitation, hematemesis, and peritonitis. A lack of external physical findings does not exclude the possibility of caustic ingestion.

### **Treatment**

The first priority of initial management is always airway protection and control. Vascular access, fluid resuscitation, and identification of the caustic agent are also important aspects of early treatment. Nasogastric intubation is avoided and gastric lavage is contraindicated to prevent propagation of injury beyond the pylorus or iatrogenic perforation. Plain chest and abdominal x-ray examinations are indicated to evaluate for mediastinal or free intraperitoneal air indicating perforation.

Once respiratory and hemodynamic stability are achieved, the severity of the injury is determined. Fiberoptic endoscopic examination of the entire airway and esophagus is the preferred method to determine the extent of injury. Esophagoscopy

is performed within 24-48 hours of ingestion to the upper limit of any full-thickness injury encountered. Endoscopic classification of caustic esophageal injuries is given in Table 83.1.

Once the grade of injury is determined (Table 83.1), the suggested management is as follows:

### **Grade I**

Children with grade I injuries are admitted for observation and intravenous fluid administration. A clear liquid diet is started at 36-48 hours and advanced as tolerated to a general diet. A contrast esophagram is performed 2-3 weeks following injury in any child with residual symptoms or dysphagia.

### **Grade II/III**

Children with grade II or III injuries are denied oral intake for several days (sometimes weeks). Parenteral nutrition, either peripheral or central, is mandatory to provide adequate nutritional support. Intensive care unit observation is necessary to monitor for signs of worsening or more complicated injury (i.e., esophageal perforation, gastric perforation, tracheoesophageal fistula, mediastinitis). Severe grade III injuries with esophageal perforation mandate surgical intervention. Oral intake is withheld until patients can tolerate swallowing their saliva. A liquid diet is started initially and advanced to a general diet as tolerated. A barium esophagram is performed at 2-4 weeks following injury to identify early stricture formation.

The use of steroids (i.e., prednisolone, dexamethasone) and antibiotics in initial management of caustic esophageal injuries is controversial. Steroids inhibit the inflammatory process and may reduce granulation and stricture formation. Unfortunately, steroids are also immunosuppressive and may contribute to infectious complications and morbidity. Antibiotics may reduce bacterial overgrowth that occurs in Grade II/III injuries.

Other forms of therapy include esophageal stenting, dilatation, and early enteral feeding by jejunostomy, gastrostomy or nasogastric tube feedings. A nasogastric tube may function to keep the esophageal lumen patent. H<sub>2</sub> blockers, proton pump inhibitors and antacids are frequently used, but their benefits have not been proven.

Immediate surgical intervention is indicated in those patients with uncontrollable hemorrhage or perforation (i.e., mediastinal air, intraperitoneal air, or peritonitis). Esophageal resection can be performed via either thoracotomy or laparotomy (i.e., transhiatal). After resection, gastrostomy or jejunostomy tube is placed and the proximal esophagus is diverted as a cervical esophagostomy. Reconstruction of the alimentary tract is delayed for at least 2-3 months or until all acute problems are resolved. The mortality associated with esophageal perforation following caustic ingestion is 20-25%.

### **Outcomes**

The most common complication of caustic ingestion is stricture formation. Although rare in Grade I injuries, strictures occur in 20-30% of Grade II injuries and 90-95% of Grade III injuries. Although several treatments have been employed to prevent stricture formation (i.e., steroids, bougienage, esophageal stents, etc.), none has been highly successful. Once a stricture has developed, dilatation becomes

**Table 83.1. Endoscopic classification of esophageal injuries**

Classification	Depth of Mucosal Involvement
Grade I	Superficial mucosal hyperemia, edema, and sloughing
Grade II	Transmural involvement with exudates, ulceration, and muscle involvement and pseudomembrane formation
Grade III	Eschar formation, obliteration of lumen, and deep ulceration Erosion through the esophagus into the periesophageal tissue, mediastinum, pleural or peritoneal cavities

necessary and is usually started at 6-8 weeks after injury. Weekly dilatation is continued until the stricture softens and a bouginage dilator 2-3 times the diameter of the esophagus can be easily passed i.e., 32-36 FR in toddlers, 38-44 FR in children 5-10 years old and 46-54 FR in children more than 10 years old. The risk of esophageal perforation with dilatation is relatively low but this is the most common complication. When the interval between dilatations fails to increase or actually decreases, long-term failure is probable. These children are candidates for surgical reconstruction such as colonic or jejunal substitution, reversed gastric tubes, or gastric pull-up procedures.

Caustic ingestion is associated with an increased risk of esophageal carcinoma. The middle portion of the esophagus is most often affected, and the tumors are usually squamous cell in origin. The incidence of esophageal carcinoma in patients after caustic ingestion is estimated to be 500-1,000 times greater than the incidence in the general population. The latency period between initial injury and development of esophageal carcinoma varies from 10-50 years. Lifelong follow-up and screening endoscopy is recommended.

### *Selected Readings*

1. Andreoni B, Farina ML, Biffi R et al. Esophageal perforation and caustic injury: Emergency management of caustic ingestion. *Dis Esoph* 1997; 10:95-100.
2. Lovejoy FH Jr. Corrosive injury of the esophagus in children. *NEJM* 1990; 323:668-9.
3. Christensen HBT. Epidemiology and prevention of caustic ingestion. *Acta Paediatr* 1994; 83:212.
4. Raffensperger JG. Caustic esophageal burns. In: Raffensperger JG ed. *Swensen's Pediatric Surgery*. Appleton-Lange 1991; 827-832.
5. Anderson KD, Rouse TM, Randolph JG. A controlled trial of corticosteroids in children with corrosive injury of the esophagus. *NEJM* 1990; 323:637.
6. Gaudreault P et al. Predictability of esophageal injury from signs and symptoms: A study of caustic ingestion in 378 Children. *Pediatrics* 1983; 71:767-770.



## **Section XIII: Gastrointestinal Diseases of the Older Child**

# Appendicitis

*Steve Szczerba*

## Incidence

Acute appendicitis is the most common surgical emergency in children and adolescents. Overall there are about 250,000 cases of appendicitis in the United States annually, and the majority occur in children 6-10 years of age. Appendicitis affects males more often than females (M:F ratio 3:2) and the lifetime risk for each group is 8.6% and 6.7%, respectively. Caucasians are affected more commonly than other racial groups. Acute appendicitis occurs more frequently during the summer months.

## Etiology

Appendicitis is caused by obstruction of the appendiceal lumen that leads to vascular congestion, ischemic necrosis, and subsequent infection. The most common cause of the obstruction is a fecalith or inspissated fecal matter. Fecaliths are identifiable in about 20% of children with appendicitis. Other causes of appendiceal obstruction include:

1. lymphoid follicle hyperplasia,
2. carcinoid or other tumors,
3. foreign bodies (i.e., pins, seeds, etc.), and
4. rarely parasites.

## Clinical Presentation

Appendicitis can affect any age group. Although exceptionally rare in neonates and infants, acute appendicitis does occasionally present at that young age, and diagnosis may be extremely difficult and delayed. In slightly older children, the presenting clinical signs and symptoms are quite variable in pattern and order of appearance. Pain is usually the first symptom. It frequently begins as a dull, vague periumbilical pain but with time may localize to the right lower abdomen. Patients typically report a gradual increase in pain intensity as the disease process progresses. Anatomical variability in the location of the appendix (i.e., retrocecal, pelvic) is common and can alter the pain symptoms accordingly. In children with a retrocecal or pelvic appendix, pain may start in the right lower quadrant without any early periumbilical pain. Flank pain, back pain, and referred testicular pain are also common symptoms in children with retrocecal or pelvic appendicitis. If the inflamed appendix is in proximity to the ureter or bladder, symptoms may include urinary frequency, pain with micturition, or discomfort from urinary retention and bladder distension.

Anorexia, nausea and emesis usually develop within a few hours of pain onset. Emesis is usually mild. Diarrhea may occur secondary to inflammation and irritation of the terminal ileum or cecum. Severe gastrointestinal (GI) symptoms that develop prior to the onset of pain usually indicate a diagnosis other than acute appendicitis. However, mild GI complaints such as indigestion or change in bowel habits occasionally precede pain symptoms in children with appendicitis.

Typically, patients with uncomplicated appendicitis have low-grade fever. Temperatures above 38.6°C suggest perforation. Children with appendicitis avoid movement and tend to lie still in bed. Frequently, these children lie quietly on their sides or with their knees flexed. Children with appendicitis sometimes walk with a limp favoring the right leg.

The signs of appendicitis elicited by physical exam are often very subtle. Hyperesthesia of the skin can be elicited by gently touching the skin of the patient with a stethoscope. Bowel sounds, although an unreliable predictor, are often decreased or absent.

The abdominal tenderness associated with acute appendicitis varies with the time-course of the disease and the anatomic location of the appendix. During the initial stages, tenderness can be mild and only vaguely localized in the lower abdomen. When the parietal peritoneum becomes irritated over the site of the appendix, localized tenderness can be elicited. "McBurney's point", an area one-third the distance from the anterior superior iliac spine to the umbilicus, is the most common site of maximal tenderness in appendicitis that has progressed beyond 12-24 hours. Retrocecal appendicitis may cause tenderness midway between the 12th rib and the posterior superior iliac spine. Pelvic appendicitis produces rectal tenderness. In children with acute appendicitis and malrotation, tenderness occurs well away from the usual location in the right lower quadrant. If the disease process has progressed beyond 24-36 hours, perforation may cause an abrupt but temporary decrease in pain symptoms and tenderness as the intraluminal pressure of the distended, inflamed appendix is released.

Peritonitis is manifest as muscle wall rigidity, guarding, and rebound tenderness. "Rovsings' sign" (palpation of left lower quadrant producing right lower quadrant pain) is a reliable indicator of acute appendicitis in children. The "psoas sign" (retrocecal appendicitis) and the "obturator sign" (pelvic appendicitis) are difficult to elicit in smaller children. Rectal exam may reveal a palpable, tender extrinsic mass or abscess.

Acute appendicitis can mimic just about any intra-abdominal process. The differential of acute appendicitis is extensive and includes gastroenteritis, Crohn's disease, mesenteric adenitis (i.e., *Campylobacter*, viruses, *Yersinia*, etc.), pancreatitis, peptic ulcer disease, cholelithiasis, cholecystitis, Meckel's diverticulitis, constipation, intussusception, and many other conditions. Systemic disorders that are in the differential of acute abdominal pain and appendicitis include porphyria, sickle cell crisis, Henoch-Schonlein purpura, hemolytic uremic syndrome, diabetic ketoacidosis, measles, Lupus erythematosus, and parasitic infections. In females, ectopic pregnancy, ovarian torsion, ovarian cysts, and pelvic inflammatory disease must also be considered. Urinary tract disease (i.e., renal stones, pyelonephritis, cystitis) can also mimic acute appendicitis. Pneumonia, particularly of the right lower lobe, is a frequent nonabdominal source of lower abdominal pain in children that must be

considered. In children less than 3 years old, gastroenteritis and ileocolic intussusception are the two most common conditions included in the differential diagnosis.

Acute appendicitis is associated with several other conditions. Patients with enterocolitis (*Yersinia*, *Salmonella*, *Shigella*, etc.) or parasitic infections (*Entamoeba*, *Strongyloides*, *Enterobius*, *Schistosoma*, *Ascaris*) can develop appendicitis secondary to both local or generalized lymphoid hyperplasia and obstruction of the appendiceal lumen. Viral infections with measles, chicken pox, or cytomegalovirus (CMV) have been linked with appendicitis.

Children with cystic fibrosis have a higher incidence of acute appendicitis due to abnormal mucous that becomes inspissated and obstructs the lumen of the appendix. Hirschsprung's disease should be considered in any neonate that presents with appendicitis.

## Diagnosis

The principal means of diagnosis is history and physical examination. Serial examinations by the same examiner are perhaps the most accurate diagnostic tool. Leukocyte count (WBC) above 10,000 is observed in greater than 90% of children with acute appendicitis. A left shift is usual but not an absolute finding. Urinalysis is helpful to differentiate pyelonephritis or renal calculus from appendicitis, however, mild hematuria and pyuria can be seen when the inflamed appendix is near the ureter.

Plain film radiography has limited value in children suspected of having appendicitis. A radiopaque fecalith can be seen in only 5% of patients with acute appendicitis. The more subtle plain film findings are:

1. sentinel loop in the right lower quadrant,
2. lumbar scoliosis concave to the right lower quadrant,
3. mass effect from a pelvic abscess,
4. loss of the psoas shadow, and
5. loss of the preperitoneal fat stripe.

A chest radiograph is obtained to evaluate children with history "atypical" for appendicitis and suspected of having a pneumonia.

Barium enema is not usually performed in children suspected of having acute appendicitis but is frequently chosen to evaluate for intussusception. Barium enema signs of appendicitis include:

1. incomplete filling of the appendix,
2. wall irregularities of terminal ileum or cecum, and
3. mass effect on the terminal ileum or cecum.

Ultrasonography has about 85% sensitivity and greater than 90% specificity in the diagnosis of acute appendicitis. The main sonographic criterion for diagnosis is demonstration of a noncompressible appendix larger than 7 mm in diameter. Identification of an appendicolith or periappendiceal fluid is also helpful. As with other radiographic studies, the value of ultrasound may be to exclude other diagnoses, particularly in female patients. Computed tomography (CT) is a reliable test for acute appendicitis but is reserved for situations when the diagnosis is unclear. Reported sensitivity and specificity are approximately 95-98%. In severely obese patients and patients presenting late and suspected of having abscesses, CT may be the diagnostic test of choice.

## Pathology/Pathophysiology

Appendicitis begins with obstruction of the appendiceal lumen. The obstructed appendix continues to secrete mucus causing the appendix to distend. Distension activates visceral nerve pain fibers that cause pain symptoms referred to the periumbilical area (T-10 dermatome). As the intraluminal pressure increases, lymphatic drainage is impaired causing further edema and intramural pressure within the appendix. As the pressure continues to rise, venous outflow is compromised which leads to decreased arterial perfusion and ischemic necrosis. Tissue infarction, gangrene with bacterial infection, and perforation follow if the condition remains untreated. Pain localizes to the right lower quadrant when surrounding inflammation irritates the parietal peritoneum activating somatic pain fibers. After perforation, localized abscess or diffuse peritonitis can occur. Diffuse peritonitis is common in young children and infants whose omentum is proportionately smaller and less able to contain an advancing suppurative process.

## Treatment

For most patients, immediate surgical intervention is not considered mandatory. The patient with appendicitis is resuscitated with intravenous fluids, started on broad-spectrum IV antibiotics, and kept NPO. Although spontaneous resolution can occur, appendectomy is still the treatment of choice for all patients suspected of having acute appendicitis. Complication rates and perforation rates are the same for patients undergoing surgery within 6 hours of admission as those undergoing surgery between 6-16 hours after admission. All patients with appendicitis and generalized peritonitis require expedient resuscitation and urgent exploration.

For children presenting late (i.e., several days or weeks) with well-localized peri-appendiceal abscess or phlegmon, prolonged IV antibiotic therapy (2-3 weeks) and CT-guided percutaneous abscess drainage is often a better therapeutic option. Interval appendectomy is usually performed 4-6 weeks later but may not be totally necessary.

At surgery, the abdomen is explored via a transverse or oblique right lower quadrant incision. The peritoneal cavity is entered and the appendix is delivered into the wound if possible. The appendix is assessed for signs of inflammation, gangrene, and/or perforation. Cultures are frequently obtained but are of questionable value. Appendectomy is all that is needed in cases of acute appendicitis whether perforated, nonperforated, or gangrenous. In rare cases, when the cecal wall is involved in a gangrenous, inflammatory process, limited ileocecal resection with primary anastomosis may be necessary. For gross contamination, the abdomen and pelvis are irrigated with saline solution. The wound closure is standard and in children the skin incision is almost always closed regardless of the pathologic findings.

If a normal appendix is found at laparotomy (5-15% of cases), the abdomen is systematically inspected for evidence of inflammatory bowel disease, a Meckel's diverticulum, mesenteric adenitis, peptic ulcer disease, and other pathology. In females, the ovaries should be identified and inspected. If Crohn's disease is encountered, the appendix should be removed unless the disease process grossly involves the base of the appendix.

Postoperative care includes continued broad-spectrum antibiotic therapy. Ampicillin, gentamycin, and clindamycin or metronidazole, are the traditional "gold standard" antibiotics for treatment of children with acute appendicitis. Antibiotic therapy must provide activity against the common pathogens associated with appendicitis: *E. coli*, *Bacteroides*, *Enterococcus*, and *Klebsiella*. Alternative antibiotics, such as ampicillin/sulbactam, and others, can be considered and are probably equally effective. A switch to oral antibiotics is sometimes made when the patient is afebrile and tolerating a diet. For perforated or gangrenous appendicitis, a 5-day course is the usual recommended therapy but many surgeons stop postoperative antibiotics when the recovering patient is afebrile with a normal WBC (including differential). For children with nonperforated appendicitis, postoperative antibiotics are usually continued for only 24 hours.

## Outcomes

Complication rates after appendectomy vary with the severity of the appendicitis. Wound infection, overall observed in 5-10% of patients, is the most common complication. Abscess formation and bowel obstruction occur in less than 5% and usually affect those with perforated appendicitis. Surgical morbidity from perforation is approximately 10% and includes wound infection, wound dehiscence, abscess, and bowel obstruction. Other complications such as tubal infertility, abscess formation secondary to retained fecalith or partial appendectomy, and suppurative pylephlebitis are also uncommonly reported after complicated cases of acute appendicitis.

## Selected Readings

1. Anderson R et al. Indications for operation is suspected appendicitis and incidence of perforation. *Br Med J* 1994; 308:107.
2. Bennion RS, Thomson JE. Early appendectomy for perforated appendicitis in children should not be abandoned. *Surg Gynecol Obstet* 1987; 165:95.
3. Brender JD et al. Childhood appendicitis: factors associated with perforation. *Pediatrics* 1985; 76:301.
4. Sarfati MR et al. Impact of adjunctive testing on the diagnosis and clinical course of patients with acute appendicitis. *Am J Surg* 1993; 166:660.
5. Stringel G. Appendicitis in children: A systematic approach for a low incidence of complications. *Am J Surg* 1987; 154:631.
6. Anderson KD, Parry RL. Appendicitis. In: O'Neill Jr. JA et al, eds. *Pediatric Surgery*, 5th Edition. St. Louis: Mosby-Year Book 1998; 1369-1380.
7. Rao PM et al. Effect of computerized tomography of the appendix on the treatment of patients and use of hospital resources. *N Engl J Med* 1998; 338:141.

# Adhesive Intestinal Obstruction

*Todd R. Vogel*

## **Incidence**

The incidence of postoperative adhesive obstruction after laparotomy is about 2%. The procedures which have highest risk for adhesive McBurney's point in pediatric patients are:

1. subtotal colectomy,
2. resection of symptomatic Meckel's diverticulum,
3. Ladd's procedure, and
4. nephrectomy.

## **Etiology**

The causes of postoperative McBurney's point include adhesions, intussusception, hernia, and tumor. Adhesions are fibrous bands of tissue that form between loops of bowel or between the bowel and the abdominal wall after intraabdominal inflammation. Obstruction occurs when the bowel is "caught" within one of these fibrous bands in a kinked or twisted position, twists around an adhesive band, or herniates between a band and another fixed structure within the abdomen.

## **Clinical Presentation**

Children with a mechanical obstruction present with cramping abdominal pain, distension, and vomiting. For prolonged McBurney's points the vomitus becomes bilious or even feculent. Inspection of the abdomen may reveal obvious dilated loops of bowel and distension. If observed early in the clinical course, the patient's vital signs are within the normal range and the abdomen is not tender. In contrast, children with compromised bowel or a prolonged obstruction, present with abdominal pain, vomiting, fever, tachycardia, decreased blood pressure, abdominal tenderness, and leukocytosis.

## **Diagnosis**

The differential diagnosis is ileus versus mechanical obstruction. Nonsurgical, inflammatory and metabolic conditions that may result in ileus must be considered. Blood is drawn and sent for Hbg, WBC and differential, amylase (pancreatitis), liver function tests (hepatitis) and bilirubin (biliary tract disease). Urinalysis (urinary tract infection, nephritis, stones), blood cultures (systemic infection), and stool cultures (colitis, rotavirus) may also be indicated. Upright posteroanterior and lateral chest xrays are obtained to exclude pneumonia or the presence of free intraperitoneal air. Flat and upright abdominal films are also obtained. In a child with a

complete bowel obstruction, abdominal films will show dilated loops of small bowel with multiple air fluid levels and little or no air in the rectum and/or distal to the obstructing lesion. Ultrasound is occasionally useful to rule out a postoperative intussusception.

### **Treatment**

Nonoperative management includes resuscitation with isotonic saline solutions, nasogastric decompression, correction of electrolyte abnormalities, IV antibiotics, and serial examinations. Within 24 hours, children with ileus and simple mechanical obstruction will improve as indicated by a return of bowel function, a normalization of vital signs and a normal WBC. Indications for operation include obstipation for 24 hours, continued abdominal pain with fever and tachycardia, decreased blood pressure, increasing abdominal tenderness, and leukocytosis despite adequate resuscitation and medical treatment.

The abdomen is opened through a previous incision, if present, and midline, if not. The cecum is identified and the collapsed ileum is followed proximally until dilated bowel and the point of obstruction is identified. The offending adhesive bands are disrupted and the abdomen is closed. Laparoscopic lysis of adhesions is another option and may allow a shorter postoperative recovery and hospital stay.

Postoperatively, nasogastric decompression and intravenous fluids are continued until return of bowel function and the volume of gastric aspirate decreases.

### ***Selected Readings***

1. Akgur FM et al. Adhesive small bowel obstruction in children: The place and predictors of success for conservative treatment. *J Pediatric Surg* 1991; 26(1):37-41.
2. Raffensperger J ed. *Swenson's Pediatric Surgery*. Norwalk: Appleton & Lange 1990; 855-857.
3. Filston HC. Other causes of McBurney's point. In: O'Neill, Jr. JA et al, eds. *Pediatric Surgery*, 5th Edition. St. Louis: Mosby 1998; 1215-1218.



# Gallbladder Disease in Childhood

*Fawn C. Lewis*

## Incidence

Gallbladder disease is uncommon in infants and children and is generally classified as congenital or acquired. Considering all children with gallbladder problems, congenital anomalies are identifiable in 14%. Thirty percent have neonatal cholestasis syndromes and 40% have calculous disease. The few remaining childhood problems are rare and include biliary obstruction from fibrosing pancreatitis, sclerosing cholangitis, or other lesions such as metastatic tumor. The most common congenital anomalies of the gallbladder are:

1. agenesis,
2. duplication,
3. ectopic location,
4. bilobate or multiseptated gallbladder, and
5. stenosis of the cystic duct.

Primary gallbladder tumors are usually benign adenomas but may have malignant potential. Gallbladder carcinoma is extremely rare in children.

The overall prevalence of cholelithiasis in neonates and young children is approximately 0.15-0.22%. This percentage increases in older children and teenagers. The genders are affected equally until adolescence, when cholelithiasis is more common in females. Native Americans, especially Pima Indians, have a much greater risk of cholelithiasis—with a prevalence approaching 100% by age 40 in the females of some tribes. Gallstones are more common in Caucasian children than children of African-American descent. Children with hemoglobinopathies or hemolytic diseases are at a great risk for cholelithiasis. Gallstones are identifiable in 12-40% of teenage children with sickle cell disease. Biliary sludge (without stones) is detectable in another 10-16%. Although biliary sludge progresses to cholelithiasis in 66-100% of children with sickle cell disease, resolution may occur in up to 20%. Approximately 14% of children with sickle cell disease undergo cholecystectomy during childhood.

## Etiology

### *Congenital Anomalies*

There are no specific causative factors associated with congenital anomalies of the gallbladder. Annular pancreas has been rarely associated with agenesis of the gallbladder.

### ***Polyposis***

Metachromatic leukodystrophy (ML) has been associated with gallbladder polyposis in children (3 cases reported in the literature). Polyposis may precede the diagnosis of ML by 6 months.

### ***Lithogenesis***

There are two general types of gallstones: cholesterol and pigment stones. Formation of cholesterol gallstones depends upon the relative concentrations of cholesterol, lecithin, and bile salts. Three factors are said to be necessary for stone formation:

1. increased cholesterol saturation of the bile,
2. bile stasis, and
3. the presence of nucleating factors as a nidus of stone formation.

Black pigment stones are usually formed in a setting of hemolysis, ileal resection, or total parenteral nutrition (TPN). Pigment stones are more prevalent in Asians.

### ***Acalculous Cholecystitis***

Several factors may predispose patients to develop acalculous cholecystitis including:

1. dehydration,
2. adynamic ileus,
3. gallbladder stasis,
4. total parenteral nutrition,
5. hemolysis, and
6. massive transfusions.

These conditions are frequently encountered in children with severe critical illness (i.e., multisystem trauma, burns, pneumonia, sepsis, severe infection).

Several factors associated with gallbladder disease in children are listed in Table 86.1.

### **Clinical Presentation**

The typical presentation of any gallbladder malady involves right upper abdominal pain, nausea, and emesis. If infection is present, fever, leukocytosis, or Murphy's sign (an inspiratory pause due to patient discomfort when the examiner holds mild pressure in the right upper quadrant) may be present. If obstruction to bile flow occurs, jaundice or acholic stools are seen. It is critically important to identify the etiology of the jaundice in order to provide proper treatment. If stones are present, surgery will correct the problem. However, more serious causes of jaundice (i.e., biliary atresia, choledochal cyst) must be excluded. Neonates and younger infants frequently have an associated clinical condition (i.e., prolonged TPN, prematurity, cystic fibrosis (CF), prolonged fasting) that may contribute to cholestasis and jaundice.

### **Diagnosis**

In addition to physical exam, laboratory evaluation of the patient's leukocyte count, electrolytes, serum glucose, liver function tests (AST, ALT, alkaline phosphatase, bilirubin, and albumin), and amylase help formulate the differential diagnosis for any patient with abdominal pain and emesis. If the child is jaundiced, serum albumin level, prothrombin time (PT), and partial thromboplastin time (PTT)

**Table 86.1. Factors associated with cholelithiasis or cholecystitis**

<b>Drugs/Treatments</b>	<b>Association</b>
Exchange Transfusion	Stones
Furosemide	Stones, Sludge
Phototherapy	Stones, Sludge
Morphine	Stasis
Ceftriaxone	Pseudolithiasis
Chemotherapy for Wilms' tumor, Neuroblastoma, Hodgkin's Disease, Non-Hodgkin's Lymphoma	Stones
<b>Diseases/Conditions</b>	<b>Association</b>
Obesity	Stones
Sickle Cell Disease	Stones, Sludge
Polycythemia	Stones, Sludge
Hereditary Spherocytosis	Stones, Sludge
Kawasaki's Disease	Hydrops
Byler's Disease (progressive familial intrahepatic cholestasis)	Hydrops
Hepatitis A	Edema, Wall Thickening
Epstein-Barr Virus	Hydrops, Sludge
Ileal Resection	Stones
Short-Gut Syndrome	Stones
Cystic Fibrosis	Stones
Infection	Sludge then Stones
Dehydration	Stones, Sludge
Leptospirosis	Stones, Sludge

are checked to assess nutritional status, hepatic synthetic function, and the possible surgical risk of hemorrhage.

Transabdominal ultrasonography is both sensitive and specific to identify dilation of the intra- or extra-hepatic biliary tree, gallbladder distension, and occasionally the pancreatic duct. Gallbladder wall thickness or edema, pericholecystic fluid, cholelithiasis, biliary sludge, or polyps are easily identified with this rapid, noninvasive test.

As in adults, evidence of dilation of the common bile duct or intrahepatic biliary system necessitates further evaluation of the biliary tree. Depending on the size of the child, endoscopic retrograde cholangiopancreatography (ERCP) or percutaneous transhepatic cholangiography (PTCA) are used to study the biliary system.

If there is no evidence of cholelithiasis or biliary dilation, nuclear studies are infrequently used to assess the function of the biliary tract. Cholescintigraphy is a nuclear medicine scan in which a technetium-99 labeled isotope is injected intravenously and concentrated and excreted in the bile. Visualization of the gallbladder usually rules out cholecystitis; excretion into the duodenum rules out complete common bile duct obstruction. Cholescintigraphy may yield false positive results in:

1. fasting patients,
2. patients on TPN, and
3. patients with acalculous cholecystitis.

Gallbladder contractility and emptying can be assessed by cholescintigraphy with simultaneous injection of cholecystokinin (CCK). A gallbladder ejection fraction of less than 35% has been reported to be associated with dyskinesia or stasis.

Delay in diagnosis is not uncommon, particularly in patients with cystic fibrosis (CF), and average delays of 8 months are common. Consequently, a high level of suspicion for gallbladder disease is necessary when CF patients present with abdominal pain.

In the neonate, acalculous cholecystitis with a gangrenous gallbladder can mimic necrotizing enterocolitis. If initial medical therapy is unsuccessful, this diagnosis should be considered and exploration may be necessary.

### Treatment

Treatment of incidentally found gallstones or sludge is expectant. Follow-up ultrasound to evaluate for disease progression is indicated if symptoms occur. In the case of children with sickle-cell disease, biliary sludge is followed regularly with ultrasound. Identification of cholelithiasis should lead to prophylactic elective cholecystectomy especially if the child has abdominal complaints that suggest cholecystitis or abdominal crises that can be confused with recurrent bouts of gallbladder inflammation. Elective cholecystectomy is performed in children with sickle cell disease and symptomatic biliary sludge. Preoperative preparation of the sickle-cell patient consists of suppressive blood transfusions (10 ml/kg 2-3 times over 2-3 weeks) to decrease the percentage of circulating Hb-S to less than 30% and to suppress bone marrow production of Hb-S. During surgery, care is taken to avoid hypothermia, hypovolemia, or acidosis since these problems can initiate a sickle crisis. In an emergent setting, preoperative transfusion to a hemoglobin of 12 and very careful management to minimize hypovolemia, hypothermia, and acidosis are critically important.

A child undergoing splenectomy due to a hemolytic disease, should also undergo prophylactic cholecystectomy if there is cholelithiasis by ultrasound.

The preferred treatment of uncomplicated biliary colic today is laparoscopic cholecystectomy. There is no standard age or size limit for this procedure, but the experience of the surgeon directs appropriate choice of "open" or "minimally invasive" technique (see Section XVI). The absolute and relative contraindications to laparoscopic cholecystectomy in children are similar to those in adults. Absolute contraindications include inability to safely perform the dissection or clearly identify the anatomy. Relative contraindications include multiple previous surgeries, bleeding disorders, and previous right upper quadrant surgery.

### Outcomes

Most children undergoing laparoscopic cholecystectomy are discharged within 24 hours; overall morbidity is 1-2%, and mortality is extremely rare. Sickle cell patients are typically hospitalized longer, especially for pain management. Morbidity from laparoscopic cholecystectomy in children with sickle cell disease is reported to be around 6%; pain crises and pulmonary infections are the leading postoperative

problems. The mortality rate associated with cholecystectomy in children with sickle cell disease is about 2-4%.

### *Selected Readings*

1. Frexes M, Neblett WW 3rd, Holcomb GW Jr. Spectrum of Biliary Disease in Childhood. *South Med J* 1986; 79(11):1342-9.
2. Emond JC, Whittington PF. Selective surgical management of progressive familial intrahepatic cholestasis (Byler's disease). *J Pediatr Surg* 1995; 30(12):1635-41.
3. Holcomb GW 3<sup>rd</sup>. Laparoscopic cholecystectomy. *Semin Pediatr Surg* 1993; 2(3):159-67.
4. Ware RE, Filston HC. Surgical management of children with hemoglobinopathies. *Surg Clin North Am* 1992; 72(6):1223-36.
5. Moir CR, Donohue JH, van Heerden JA. Laparoscopic cholecystectomy in children: Initial experience and recommendations. *J Pediatr Surg* 1992; 27(8):1066-70.
6. Newman KD, Marmon LM, Attorri R et al. Laparoscopic cholecystectomy in pediatric patients. *J Pediatr Surg* 1991; 26(10):1145-7.
7. Rowe MI, O'Neill JA Jr., Grosfeld JL et al, eds. *Essentials of Pediatric Surgery*. St. Louis: Mosby-Year Book Inc. 1995; 656-62.

# Superior Mesenteric Artery (SMA) Syndrome

*Todd R. Vogel*

## **Incidence**

SMA syndrome is a rare cause of small bowel obstruction in the pediatric population.

## **Etiology**

The duodenum passes between the aorta and the SMA at the level of the third thoracic vertebra. The SMA arises at the level of the first lumbar vertebra at an angle of 45-60°. Compromise of this angle secondary to weight loss and resorption of retroperitoneal fat may lead to extrinsic compression of the duodenum. Symptoms present when the third portion of the duodenum is intermittently compressed by the overlying superior mesenteric artery (usually at an angle of 15° or less). Anatomic features include a short aortomesenteric distance together with sagittal parallelism between the aorta and the SMA. Predisposing factors include a rapid weight loss, prolonged supine positioning, and use of spinal orthosis. Spinal orthosis or body casts are associated with hyperextension of the spine allowing for SMA compression. Familial clustering of SMA syndrome and genetic predisposition have been suggested.

## **Clinical Presentation**

Most patients present with a history of weight loss from dieting or illness, a history of minimal weight loss but with rapid vertical growth, or a history of immobilization. Nausea, intermittent bilious vomiting are the principal symptoms. On examination, the patients are usually thin and the abdominal examination is unremarkable.

## **Diagnosis**

The differential diagnosis includes ileus, malrotation, and anorexia nervosa. Abdominal films are usually unrevealing. Upper GI study demonstrates a dilated proximal duodenum with minimal or no passage of contrast past the vertebral column. Turning the patient prone or on the left side results in passage of contrast into a decompressed bowel. The gold standard for diagnosis is a lateral aortogram with concomitant ingestion of a barium meal.

## Treatment

Conservative treatment with an oral diet of frequent, small volume, high calorie liquids results in weight gain and complete recovery in most patients. Positioning the patient in the left lateral position may allow for passage of intestinal contents. Alternatively, continuous nasojejunal feedings may be used until the retroperitoneal fat has been restored. If enteral feedings are unsuccessful, hyperalimentation is indicated. If weight gain is not established in 5-7 days, surgical intervention should be considered.

Surgical options include:

1. mobilization of the duodenum from underneath the SMA and placing it to the right of the spine or
2. duodenojejunostomy.

## Selected Readings

1. Burrington JD. Superior Mesenteric Artery Syndrome. In Raffensperger, JG ed. Swenson's Pediatric Surgery, 5th Edition. Norwalk: Appleton & Lange 1990; 867-870.
2. Burrington JD. Superior Mesenteric Artery Syndrome in Children. *Am J Dis Child* 1976; 130:1367.
3. Ylinen P et al. Superior Mesenteric Artery Syndrome. A follow-up study of 16 operated patients. *J Clin Gastroenterol* 1989; 11(4):386-391.

# Inflammatory Bowel Disease

*Christopher Mascio and Daniel A. Bambini*

Pediatric inflammatory bowel disease (IBD) is somewhat different from adult IBD since it is typically associated with a more severe clinical course, concurrent emotional problems, growth and pubertal delay, and increased risk of colon cancer from long-standing disease. IBD includes both ulcerative colitis and Crohn's disease. Although considered distinct entities, clinical differentiation between the two is not always clear-cut. Clinical presentation, radiographic evaluation, and pathologic findings are all given careful consideration to achieve an accurate diagnosis.

## **Incidence and Etiology**

The incidence of pediatric IBD is estimated to be between 3-10 per 100,000 children per year. Males and females are affected equally and approximately 25% of patients have a family history of IBD. Both ulcerative colitis (UC) and Crohn's disease occur more frequently in the Jewish population than other ethnic groups. IBD is uncommon in Asian and African-American children; it affects white children 4-5 times more frequently than black children.

The exact cause of IBD is currently unknown but a multifactorial etiology is likely. Children with ulcerative colitis often have a characteristic genotype (HLA-W27) suggesting genetic factors predispose to the development of this disease. One theory suggests UC develops as an immunologic response to an unidentified colonic antigen. The proposed antigen may be of bacterial, viral, or autologous origin.

Conditions associated with the development of Crohn's disease are allergic hypersensitivity, vasculitis, and autoimmune disease. Genetic or environmental factors (i.e., infection, smoking, second hand smoke inhalation) may also contribute to the pathogenesis of Crohn's disease. Pathologic specimens from patients with Crohn's disease frequently have lymphangiectasis and mesenteric adenopathy suggesting that obstructive lymphangitis plays a causal role.

## **Ulcerative Colitis**

### *Clinical Presentation*

Most children with ulcerative colitis develop symptoms between the ages of 10-20 years. Only 4% of these patients develop symptoms before the age of 10 years. The most common presenting symptoms are diarrhea and rectal bleeding. The typical scenario is a episode of diarrhea followed by the appearance of bloody mucus or pus



in the child's stools. Other symptoms and signs include tenesmus, crampy abdominal pain, anorexia, weight loss, growth retardation, and anemia (67%). Although the onset of symptoms is usually insidious, 15% of children present with acute fulminant colitis (i.e., severe abdominal pain, profuse bloody diarrhea, fever, sepsis) requiring aggressive medical (and sometimes surgical) therapy. Of these children, 5% develop toxic megacolon. Extracolonic manifestations of UC include sclerosing cholangitis, fatty liver, arthralgias (25%), arthritis, uveitis (< 2%), osteoporosis, erythema nodosum, pyoderma gangrenosum, nephrolithiasis (8%), and aphthous stomatitis.

### *Diagnosis*

Because ulcerative colitis usually affects the rectum (95%), flexible sigmoidoscopy or colonoscopy is the best initial diagnostic study. Endoscopic findings of UC include mucosal friability, pseudopolyps, and ulcers. Biopsies are obtained to confirm the diagnosis. Barium enema (BE) is an effective means to evaluate the entire colon but occasionally worsens or precipitates an episode of acute colitis. BE findings that suggest a diagnosis of ulcerative colitis include ulcerations, pseudopolyps, mucosal "thumbprinting," loss of haustra, and a shortened, narrowed, rigid-appearing colon. The BE exam may be entirely normal in the early stages of ulcerative colitis.

Recently, serological assays have been developed which help distinguish types of inflammatory bowel disease in children (Table 88.1). Assays for perinuclear antineutrophil cytoplasmic antibodies (pANCA) are positive in children with UC with over 90% specificity. While some patients with Crohn's disease have a positive assay for pANCA, their clinical presentations often resemble that of ulcerative colitis. Children with UC remain positive for pANCA even after resection.

### *Pathology/Pathophysiology*

Ulcerative colitis usually develops first at the rectum and progresses proximally. It affects only the large intestine, and 95% of patients have rectal involvement. The severest cases involve the entire colon (pancolitis), but the greatest amount of inflammation and pathologic changes are always within the rectosigmoid colon. Chronic inflammation and ulceration of the mucosa and submucosa lead to the formation of pseudopolyps (Fig. 88.1). Crypt abscesses are the most distinguishing microscopic feature of ulcerative colitis.

The risk of colon carcinoma in children with UC is approximately 2-4% after 10 years of active disease. The risk increases by 15-20% in each subsequent decade. If colonic mucosal biopsies demonstrate dysplasia, the risk of carcinoma is very high.

### *Treatment and Outcomes*

Primary medical therapy includes systemically and locally administered corticosteroids, sulfasalazine, and oral metronidazole. The use of other immunosuppressive agents (i.e., azathioprine, cyclosporin) is controversial. The child's nutritional status is assessed and supplemental multivitamins and/or iron are administered as necessary. During acute flare-ups, hospitalization with bowel rest, intravenous fluids, parenteral nutrition, and intravenous steroids are often required to control symptoms.

**Table 88.1. Serological assays for the diagnosis of pediatric inflammatory bowel disease**

Assay	Ulcerative colitis	Crohn's disease
Perinuclear antineutrophil cytoplasmic antibodies (pANCA)	↑↑↑	↑
Anti- <i>Saccharomyces cerevisiae</i> antibodies (ASCA)	—	↑↑↑

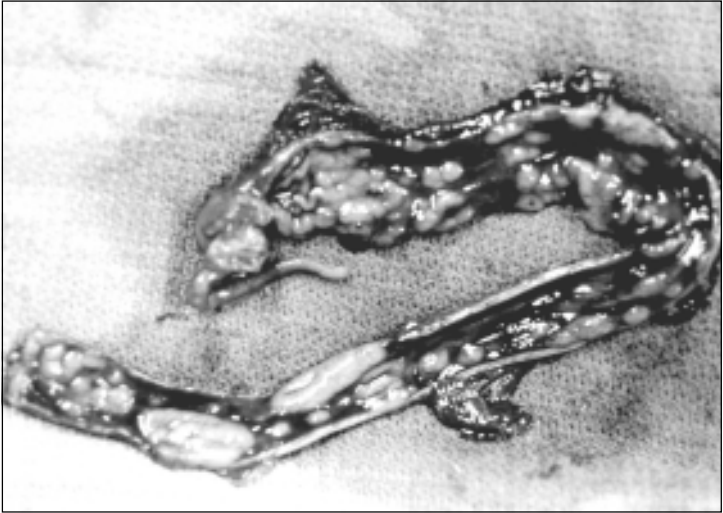


Fig. 88.1. Total colectomy specimen showing extensive ulcerative colitis and loss of large sections of colonic mucosa and pseudopolyps.

Indications for elective surgical intervention include chronicity, anemia, growth retardation, failure to thrive, and an unacceptable quality of life. Emergent surgical therapy is occasionally required in cases with severe hemorrhage, perforation, or toxic megacolon that fails to respond promptly to medical therapy. Total proctocolectomy provides a cure since ulcerative colitis affects only the colon and rectum. Reconstructive options include:

1. permanent ileostomy,
2. endorectal ileal pullthrough (i.e., straight ileoanal, J-pouch, S-pouch, etc.), and
3. continent ileal reservoir (i.e., Koch pouch).

A diverting ileostomy is used to protect the reconstruction and reduce the risk of pelvic infection. Ileostomy closure is generally performed at 3-4 months following proctocolectomy.

Complications following proctocolectomy and pull-through procedures in children with UC include chronic reservoir inflammation (pouchitis), anastomotic stricture, diarrhea, increased stool frequency and urgency. Most children experience 3-6 bowel movements per day. Long-term, less than 5% experience daytime soiling, although 15% will have occasional nocturnal soiling.

## Crohn's Disease

### *Clinical Presentation*

Although Crohn's disease usually affect young adults, 15-20% of patients develop symptoms before age 15 years. The most common presenting signs and symptoms of Crohn's disease in children are:

1. anorexia with weight loss (90%),
2. abdominal pain (70%),
3. diarrhea (67%),
4. anemia, and
5. fever.

Extraintestinal manifestations of Crohn's disease include conjunctivitis, growth retardation, arthritis, nephrolithiasis, cholelithiasis, and digital clubbing.

Although Crohn's disease can affect any portion of the gastrointestinal tract, ileocolitis is the most common form. Isolated colonic involvement occurs in 30-35%, while isolated small bowel disease only occurs in 10% of children.

### *Diagnosis*

A complete radiographic evaluation includes all portions of the gastrointestinal tract. Contrast studies (i.e., upper gastrointestinal series with small bowel follow through, barium enema) provide the most information. Radiographic features of Crohn's disease include thickened mucosal folds, linear ulcerations, "cobblestoning" of the mucosa, intestinal fistulas, sinus tracts, and strictures. In children suspected of having an intra-abdominal abscess, computed tomography (CT) is useful. Tissue samples are obtained by upper and/or lower endoscopy to confirm the diagnosis.

Laboratory findings consistent with Crohn's disease include anemia, elevated erythrocyte sedimentation rate (ESR), prolonged prothrombin time, and hypoalbuminemia. Stool cultures are generally negative for pathologic organisms. Serological assays for anti-*Saccharomyces cerevisiae* antibodies (ASCA) are elevated and highly disease specific to Crohn's disease. Titers for ASCA decrease toward normal levels following resection.

### *Pathology/Pathophysiology*

In contrast to ulcerative colitis, Crohn's disease is a transmural inflammatory process. The intestinal wall is thickened with areas of submucosal edema, fibrosis, and granuloma formation. The granulomas affect all bowel layers, contain multinucleated giant cells, and are present in about 60% of children with the disease. Skip areas of intestinal involvement separated by normal segments of bowel are a distinguishing feature of Crohn's disease. Transmural bowel wall inflammation commonly leads to fistula formation to the skin, urinary bladder, vagina, and other portions of small and/or large bowel. Mucosal ulcers produce the characteristic "cobblestone" appearance.

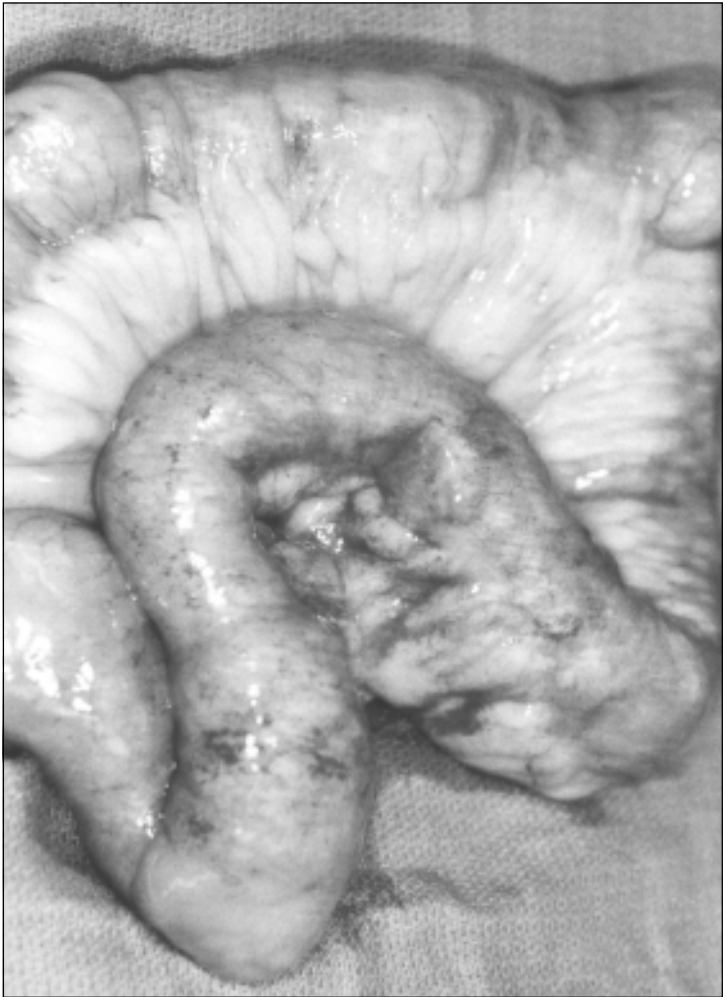


Fig. 88.2. Intraoperative demonstration of inflamed, thickened terminal ileum with thickened mesentery and “fat creep” onto bowel.

### *Treatment*

Initial medical treatment includes dietary modification (i.e., high calorie, high protein), administration of azulfidine (sulfasalazine). More severe cases may require the use of 5-aminosalicylic acid compounds, prednisone, cyclosporin, azathioprine, or methotrexate either alone or in combination. Metronidazole also helps relieve and control symptoms. Hospitalization is required for severe symptoms or contin-

ued malnutrition despite outpatient therapies. Total parenteral nutrition, bowel rest, and electrolyte repletion are sometimes required.

Surgery is noncurative for Crohn's disease but may impart clinical improvement and/or remission. In addition, resection allows reduction or even discontinuation of some medications for variable periods of time. The usual indications for operation include three complications: fistula, abscess, and obstruction. Failure to thrive is a less common indication for surgical therapy. The benefit of surgical intervention is carefully weighed against the high risk of recurrence after each operation. The overall surgical goal is to preserve bowel length. Bowel-preserving techniques include:

1. repairing multiple strictures with enteroplasties,
2. avoiding segmental resection whenever possible, and
3. taking small margins of normal bowel when resection and anastomosis is required.

Despite periods of remission, the incidence of recurrence is as high as 70% at one year, even with complete resection of all grossly involved bowel. The incidence of reoperation increases as these children are followed throughout life.

### *Selected Readings*

1. Pettei MJ, Davidson M. Extra-gastrointestinal manifestations of inflammatory bowel disease. *J Pediatr Gastroenterol Nutr* 1985; 4:689.
2. Castile RG et al. Crohn's disease in children: assessment of the progression of disease, growth, and prognosis. *J Pediatr Surg* 1980; 15:462.
3. Coran AG, Klein MD, Sarahan TM. The surgical management of terminal ileal and right colon Crohn's disease in children. *J Pediatr Surg* 1983; 18:592.
4. Dehn TCB et al. Ten-year experience of strictureplasty for obstructive Crohn's disease. *Br J Surg* 1989; 76:339.
5. Coran A. A personal experience with 100 consecutive total colectomies and straight ileoanal endorectal pull-throughs for benign disease of the colon and rectum in children and adults. *Ann Surg* 1990; 212:242.
6. Fokalsrud EW, Loar N. long-term results after colectomy and endorectal ileal pullthrough procedure in children. *Ann Surg* 1992; 215:57.
7. Ruummele FM, Targan SR, Levy G et al. Diagnostic accuracy of serological assays in pediatric inflammatory bowel disease. *Gastroenterology* 1998; 115:822.

## Disorders of the Pancreas

*Todd R. Vogel*

The most common pancreatic disorders encountered in infants and children are:

1. pancreatitis,
2. congenital anatomic lesions,
3. carcinoma, and
4. hypoglycemia.

The first three of these entities are discussed in this section. Hypoglycemia is discussed in Chapter 99.

### **Pancreatic Embryology and Anatomy**

The pancreas develops in the 4th week of gestation and begins as two buds, dorsal and ventral, from the endoderm of the duodenum. The growing dorsal portion of the developing pancreas spans across the hepatic diverticulum while the ventral portion lies below moving more distal. The dorsal and ventral portions fuse in week ten. The distal portion will create the duct of Wirsung while the proximal portion may obliterate or form the duct of Santorini. 10% of the population will have a double collecting system in the pancreas. Fetal insulin production begins in the fifth gestational month and the exocrine function is present at birth.

The pancreas is a retroperitoneal organ located at the vertebral L1-L2 level. The head of the pancreas lies to the right of the vertebral column and, along with the uncinate process, is intimately adherent to the duodenum. The body of the pancreas lies anterior to the superior mesenteric artery and vein, and the portal vein. The arterial supply of the pancreas is derived from the gastroduodenal artery, superior mesenteric artery, and the splenic artery. The head of the pancreas receives arterial blood via the four pancreaticoduodenal arteries (i.e., anterior superior, anterior inferior, posterior superior, and posterior inferior). Venous drainage is via the splenic and portal vein.

### **Acute Pancreatitis**

#### *Incidence*

Acute pancreatitis is an uncommon disease in children but has higher morbidity and mortality than in adults.

### *Etiology*

The vast majority of cases of pancreatitis in children are from blunt abdominal injury. In the pediatric population, nearly 40% of cases of traumatic pancreatitis are attributable to bicycle-related injury. After trauma, the most common causes of pancreatitis in children are drug therapy (corticosteroids, azathioprine, thiazides, furosemide, tetracyclines, and valproic acid), viral infection (Epstein-Barr, Coxsackie, enterovirus, and mumps), and bacterial infection. Cystic fibrosis, biliary disease, vasculitic diseases (systemic lupus, Henoch-Schonlein purpura), and type I and V hyperlipidemias are also associated with acute pancreatitis in the pediatric population.

### *Clinical Presentation*

Children present with vague abdominal pain which is exacerbated by eating. The classic symptom of pain radiating to the back is rarely observed in the pediatric population. Nausea and vomiting may be present. Rarely, patients may present with a small bowel obstruction or young women may present with salpingitis secondary to pancreatitis.

### *Diagnosis*

Serum amylase, trypsinogen, and lipase levels are useful to establish the diagnosis of acute pancreatitis. An elevated serum amylase is the usual biochemical abnormality associated with acute pancreatitis. Because amylase production occurs from other nonpancreatic sources (i.e., salivary gland), elevated serum amylase is relatively nonspecific. Calculation of the amylase clearance may be helpful and is normally less than 5%. Trypsinogen and lipase are produced almost exclusively by the pancreas; elevated serum levels are more specific for pancreatitis.

Computed tomography (CT) is the best radiographic study to image the pancreas in cases of severe or complicated pancreatitis. Abdominal CT is often obtained as part of the trauma evaluation. Ultrasound is sometimes useful, but often only provides limited visualization of the pancreas due to its retroperitoneal location and interposed bowel gas which further limits the study. Endoscopic retrograde cholangiopancreatography (ERCP) is an invasive test that can accurately delineate pancreatic ductal anatomy. ERCP causes pancreatitis in 5-10% of cases and is generally avoided during the early phases of acute pancreatitis.

### *Treatment*

Medical management is the mainstay of treatment for pancreatitis. Volume resuscitation is essential to counter retroperitoneal third space fluid losses. Nasogastric decompression is recommended to avoid gastric distention and patients are initially maintained NPO with nasogastric decompression. Pain management is essential. Meperidine is preferred because it does not cause sphincter of Oddi contraction like morphine does. Hyper-alimentation may be necessary if the course of pancreatitis is prolonged. Enteral feeding distal to the ligament of Treitz via duodenal feeding tube is the preferred method of providing nutrition in refractory cases. The majority of cases of pancreatitis are self-limited and resolve spontaneously with supportive therapy.

In severe cases (i.e., necrotizing pancreatitis, infected pancreatic necrosis), surgical intervention may be necessary for irrigation and/or debridement of the pancreas. The mortality rate in this scenario approaches 15%.

## **Chronic Relapsing Pancreatitis**

### *Incidence*

Chronic relapsing pancreatitis in children is rare.

### *Etiology*

Chronic relapsing pancreatitis is usually associated with a hereditary disease such as hyperlipidemia types I and V, aminoaciduria, or hyperparathyroidism. It has also been described in association with familial pancreatitis, congenital anomalies, and posttraumatic pancreatitis. The disease process causes changes in the pancreatic parenchyma including calcification, nodularity, and fibrosis.

### *Clinical Presentation*

Children most commonly present with intractable abdominal pain. Some may have pancreatic exocrine insufficiency. Endocrine insufficiency is exceedingly rare, but can develop.

### *Diagnosis*

The diagnosis is suggested by a history of recurrent episodes of acute pancreatitis. ERCP is recommended to determine ductal anatomy and identify abnormalities and/or strictures. ERCP is mandatory before any operative procedure can be considered.

### *Treatment*

Surgical therapy may be indicated in cases of severe unremitting pain or if ductal strictures are present that cannot be managed endoscopically (i.e., stent, dilatation, etc). Surgical treatment has also been suggested as a possible means to prevent the progression of exocrine and endocrine insufficiency. Surgical therapy is guided by the findings of the ERCP. Options include internal drainage (i.e., Roux-en-Y, lateral pancreaticojejunostomy (Puestow procedure) and/or pancreatic resection.

## **Pancreatic Cysts**

### *Etiology and Classification*

Pancreatic cysts are broadly classified based on etiology. These are simply categorized as:

1. congenital,
2. retention,
3. pseudocysts,
4. neoplastic, or
5. parasitic.



### ***Congenital Pancreatic Cysts***

Congenital cysts of the pancreas are a rare finding in children. The cysts may be unilocular or multilocular and are most commonly found in the body or tail of the pancreas. These cysts are lined with true epithelium and most commonly contain nonenzymatic fluid. The majority of these lesions are asymptomatic unless they are large. Symptomatic cysts are excised.

### ***Retention Cysts***

Pancreatic retention cysts occasionally occur in children and are associated with chronic obstruction of the pancreatic ductal system. These cysts are filled with enzyme containing fluid. Surgical treatment is by excision or internal drainage.

### ***Pseudocysts***

Approximately 90% of pseudocysts occur secondary to trauma. This condition is more common in males (nearly 3:1). Patients present with symptoms (most common to least) of vomiting, abdominal pain, abdominal mass, fever, and anorexia. Pseudocysts are usually located in the lesser sac and the cyst wall consists of granulation tissue. If the cyst communicates with the pancreatic ductal system, high amylase levels are measurable with the cyst fluid. Useful diagnostic tests include serum amylase, ultrasound, and CT. Surgical treatment is indicated for large, persistent, or infected/symptomatic cysts. The surgical options include external drainage, cystgastrostomy, cystjejunostomy, or excision. Surgical therapy is associated with low mortality, minimal morbidity, and low recurrence.

## **Congenital Pancreatic Abnormalities**

### ***Annular Pancreas***

Annular pancreas is a rare congenital anomaly that occurs due to abnormal rotation of the pancreatic ventral bud. It is the most common of the congenital pancreatic abnormalities. The annular pancreas usually completely encircles the second portion of the duodenum. This anomaly is associated with Down's syndrome, abnormalities of rotation, duodenal atresia (see Chapter 59), and biliary atresia. Seventy percent of children with this lesion are symptomatic and will present with high intestinal obstruction. The emesis is most often bilious but can be nonbilious as well. Surgical therapy (see Chapter 59) consists of bypass anastomosis: duodenoduodenostomy or duodenojejunostomy. Division of the pancreatic tissue is not recommended due to the high association of fistula formation. Gastrojejunostomy is not recommended due to associated growth problems and the risk of marginal ulcers.

### ***Pancreatic Divisum***

Pancreatic divisum is a congenital anomaly in which the dorsal and ventral pancreatic tissue fail to fuse in utero. Pancreatic divisum is identifiable in 10-15% of the population. This condition is usually asymptomatic, however there may be an increased incidence of pancreatitis due to the inability of the accessory duct to adequately drain the pancreatic tissue. Diagnosis is made exclusively with ERCP. Treatment, if necessary, is by endoscopic or surgical sphincterotomy of the accessory ampulla.

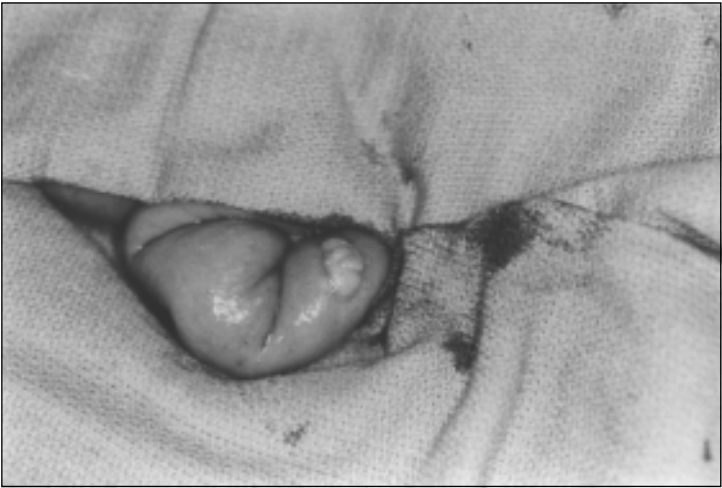


Fig. 89.1. Small, antimesenteric remnant of aberrant tissue that proved to be a pancreatic rest.

### *Ectopic Pancreas*

Ectopic pancreatic tissue (Fig. 89.1) is frequently identified in the duodenum, colon, pylorus, appendix, or a Meckel's diverticulum. Ectopic pancreas can cause local inflammation and bleeding and is noted in approximately 3% of postmortem examinations.

### **Pancreatic Neoplasms**

Neoplasms are an extremely rare surgical problem in infants and children. Only about 70 cases have been reported in the literature. Neoplasms may be cystic or solid masses. Solid masses are more likely to be malignant. The most common malignant tumors are:

1. adenocarcinoma,
2. islet cell carcinoma,
3. undifferentiated carcinoma, and
4. ductal cell carcinoma.

Tumors may be endocrinologically active or silent. Patients present with various clinical symptoms including abdominal pain, hypoglycemia, abdominal mass, and jaundice. The treatment is surgical excision with encouraging long term survival.

Of the endocrinologically active tumors, insulinoma is the most common. Insulinoma is a benign tumor usually seen in children greater than 4 years of age. Patients usually present with Whipple's triad. Gastrinoma is the second most common of the endocrinologically active tumors. Gastrinoma is associated with hypergastrinemia and peptic ulcer disease. The majority of gastrinomas are malignant.

***Selected Readings***

1. Ghishan et al. Chronic relapsing pancreatitis in children. *J Pediatrics* 1983; 102(4):514-518.
2. Jaksic T et al. A 20 year review of pediatric pancreatic tumors. *J Pediatr Surg* 1992; 27(10):1315-1317.
3. Petersen C et al. Surgical therapy and follow up of pancreatitis in children. *J Pediatr Gastroent* 1997; 25(2).
4. Raffensperger JG. Pancreatitis. In: Raffensperger JG ed. *Swenson's Pediatric Surgery*, 5th edition. Norwalk: Appleton & Lange 1990; 891-894.
5. Roberts I. Disorders of the Pancreas in Children, *Gastroenter Clinics Nor Am* 1990; 19:No. 4.

## **Section XIV: Endocrine Disorders**

# Pheochromocytoma

*Richard Fox*

## **Incidence**

Pheochromocytoma is an uncommon neoplasm of childhood. It presents with symptoms of catecholamine excess that can be cured with prompt diagnosis and treatment. In the general population, pheochromocytoma may occur in 1 per 50,000. Of the patients with nonessential hypertension, 0.1-0.2% of adults and 1% of children have pheochromocytomas. Ten percent of reported tumors occur in childhood of which 90% occur sporadically. A strong familial relationship is demonstrated by the high concordance rates among both children and adults, 5-10% and 2.5% respectively. Four percent of tumors are associated with various neurocutaneous syndromes, including Von Recklinghausen's neurofibromatosis, Sturge Weber, Von Hippel Lindau and the MEN (multiple endocrine neoplasia) IIa and MEN IIb syndromes. Bilateral tumors are present in 70% of children which is nearly 10 fold greater than the bilaterality rate observed in adults. Bilateral tumors occur most frequently in children afflicted with familial tumor syndromes (i.e., MEN). Bilaterality is less prominent in those with nonsyndromatic familial tumors. The right adrenal gland is affected twice as frequently as the left. Hormonal influences may play a role in the development of pheochromocytoma. Males are affected more often than the females during the preadolescent years while the opposite occurs after the onset of puberty.

## **Clinical Presentation**

Pheochromocytoma typically presents in children between the ages of age 8-14 years. In contrast to adults, who generally present with paroxysms of hypertension, children often demonstrate repeated sustained episodes of elevated blood pressure. Symptoms often present acutely without prodrome in children. Common complaints include headache, sweating and nausea. Others note polydipsia or polyuria, visual disturbances and seizures, or even weight loss despite a voracious appetite. Rarely, other children complain of vague somatic or bony pains, often signifying the presence of metastatic disease. In any event, symptoms that remain unrecognized may result in congestive heart failure, hypertensive retinitis, encephalopathy and ultimately death.

Physical exam often demonstrates elevated blood pressure, tachycardia, flushing and diaphoresis. Occasionally, extremity exam evaluation reveals puffy, cyanotic, mottled hands.

Nearly every organ system is included in the differential diagnosis. Diabetes mellitus, hyperthyroidism, Conn's or Cushing's disease, and adrenogenital syndrome are the major endocrinopathies to be considered. These conditions all result from excess tumor steroid production. Bilateral femoral pulses are assessed to exclude the diagnosis of coarctation of the aorta. Renal artery stenosis and renal parenchymal diseases, including pyelonephritis, glomerulonephritis, and neoplasm, are all potentially suspect. Cerebrovascular disease, psychiatric conditions, and lead poisoning also mimic the findings observed in patients with pheochromocytoma. Finally, in children who demonstrate paroxysms of hypertension, familial dysautonomia (Riley-Day syndrome) is a consideration.

## Diagnosis

Urinalysis is the most sensitive diagnostic test. Urinary free catecholamines, vanillamandelic acid (VMA) and metanephrines (MN) are measured. Classically, a twenty-four hour urine collection is preferred, however, an overnight sample suffices. Finally, new and improved radiographic studies (i.e., MIBG (metaiodobenzylguanidine) scan) facilitate tumor localization prior to laparotomy.

Metanephrines are by far the most reliably measured breakdown product. A false negative rate of 4% is acceptable. VMA analysis carries a false positive rate of nearly 25%. This is secondary to variation in daily creatinine clearance or ingestion of raw fruit, coffee or tea, that alter its value. However, VMA level often correlates directly with tumor size which is a definite prognostic advantage. In patients with elevated homovanillic acid (HMA) levels, a diagnosis of either neuroblastoma or rarely, a pure dopamine secreting tumor, is suspected.

Radiographic modalities available include ultrasound, computed tomography (CT) scan, magnetic resonance imaging (MRI), and MIBG nuclear scan. Tests that have fallen out of favor include selected venous sampling and arteriography, as well as provocative testing utilizing histamine or phentolamine. These tests all carry significant risk for morbidity and mortality from potential precipitation of catecholamine crisis. Furthermore, the current radiographic studies are far superior in safety, simplicity and diagnostic accuracy.

Ultrasound is a highly sensitive diagnostic tool in skilled hands. Some institutions boast a 100% accuracy rate with this modality. Success is entirely operator dependent based heavily upon the operator's level of expertise.

CT scan detects 95% of tumors. Missed tumors include very small lesions (1-1.5cm), extra-adrenal lesions, adrenal hyperplasia, and residual or recurrent tumors. Similarly, MRI is also excellent in diagnosis of pheochromocytoma. Its advantage over CT is in superior adrenal imaging with adjustment of T1 and T2 weighted images.

MIBG scanning excels in detection of extra-adrenal tumors that CT or MRI fails to detect. MIBG may also play a significant role in detection of bony metastasis with accuracy that complements bone scanning. MIBG inhibits catecholamine uptake by chromaffin cells and subsequently blocks adrenergic neurons. It is stored in vesicles as a norepinephrine analogue. Its uptake is proportionate to the number of secretory granules in adrenal or tumor cells. MIBG's main drawback is the relative inability to distinguish normal adrenal gland from tumor, especially in children with MEN

who have hyperplastic adrenal glands. False negative results occur in the presence of medications that interfere with vesicular uptake of norepinephrine. Examples include oral decongestants, antipsychotics, tricyclic antidepressants, calcium channel blockers, cocaine, and some beta blockers.

### **Pathology/Pathophysiology**

Pheochromocytoma is named after the predominant cell from which it derives, the pheochromocyte (black cell). Catecholamines are stored in intracellular vesicles that when oxidized by dichromate fixative, result in a characteristic black appearance (the chromaffin reaction). Tumors are yellow-brown in color and often appear well circumscribed (Fig. 90.1). Tumors average 3-6 cm in diameter and usually weigh less than 50 grams. Histologically, cells line up in discrete rows or nests called "zellballen," meaning balls of cells.

The sympathetic chain develops from totipotential neural crest cells that emigrate from the cervical aorta caudally along all major aortic branches toward the pelvis. These precursor cells form the major paraganglia and adrenal medulla. Accordingly, extra-adrenal tumors are located in these areas. Vasoactive amines are secreted by these cells causing the characteristic symptoms of pheochromocytoma.

Seventy percent of tumors are located within the adrenal medulla, whereas up to 30% are found in an extra-adrenal location. Ninety-five percent of all tumors are located below the diaphragm. The most common site of extra-adrenal tumor is within the bladder. In these cases, hematuria is often an initial presenting symptom. Other sites include the "organ of Zuckercandl" (i.e., paraganglionic tissue at the aortic bifurcation), renal hilum, chest or mediastinum, carotid body, and prostate. Rarely, tumor is noted in both intra- and extra-adrenal locations. If tumors are identified in places not commonly inhabited by chromaffin tissue, a careful evaluation for metastatic disease is indicated. Unlike most tumors, histology fails to distinguish benign from malignant lesions. Clinical behavior alone makes this determination. In children, 3-6% of tumors are malignant compared to 10% of those in adult patients.

Tumors arising from adrenal medulla secrete both epinephrine and norepinephrine. Extra-adrenal tumors primarily secrete norepinephrine because they lack the enzyme phenylethanolamine-N-methyltransferase. Incidentally, dopamine is found in many tumors. However, it is rarely secreted, nor is it responsible for symptoms. Excess catecholamine activates both alpha and beta receptors. Specifically, norepinephrine activates alpha receptors. Epinephrine, on the other hand, stimulates both alpha and beta receptors resulting in diastolic hypertension from peripheral vasoconstriction. Reflex bradycardia is occasionally observed.

### **Treatment**

Treatment of pheochromocytoma is primarily surgical. Paramount for a successful outcome is adequate preoperative blood pressure control and fluid management. The goal of therapy is to optimize patients hemodynamically in an effort to avoid intraoperative cardiovascular crisis. Adequate alpha blockade (and sometimes beta blockade) for 1-2 weeks is often necessary to reduce blood pressure. Beta blockade is added when children:

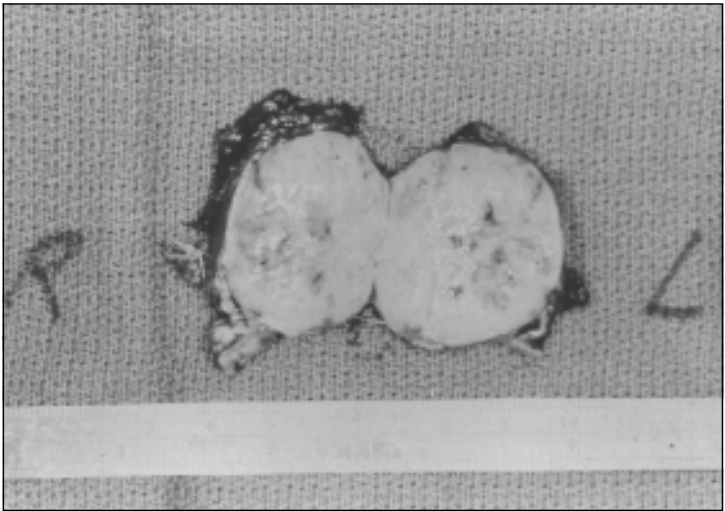


Fig. 90.1. Pathological specimen of a well-circumscribed, suprenal gland tumor that was cytologically a pheochromocytoma.

1. demonstrate signs or symptoms of cardiac arrhythmia,
2. experience tachycardia greater than 140 beats per minute, or
3. have pure epinephrine secreting tumors.

Alpha blockade is always given prior to beta blockade to avoid potential catecholamine-induced cardiomyopathy from either a direct toxic effect to the myocardium or from ischemic changes from intense, unopposed vasoconstriction. Of note, beta blockade may interfere with analysis of urinary metanephrines. If blood pressure is not critically elevated, phenoxybenzamine is administered orally and titrated to normotension over a period of 1-2 weeks. This medication works slowly. If critically elevated blood pressures are present, rapid intravenous correction with phentolamine (regitine) or nitroprusside is recommended. Predictors of a favorable surgical outcome are the ability to successfully normalize blood pressure and/or relieve symptoms with medical management. An even more sensitive indicator is the normalization of urinary metanephrines.

Preoperatively, nutritional supplementation is often necessary to replenish energy stores lost to hypermetabolism. A hypermetabolic state is the direct result of catecholamine excess. In general, patients with elevated basal metabolic rates perform and recover poorly overall.

Prior to induction of general anesthesia, appropriate volume resuscitation is crucial. On average, approximately 15% of the circulating volume may need replacement. This is due to chronic catecholamine-induced vasoconstriction with subsequent loss of plasma and red blood cell mass. This is especially important prior to induction of general anesthesia where global vasodilation may precipitate cardiovascular crisis from hypovolemia.



Two phases of general anesthesia are encountered. First is the hypertension phase. This includes all events prior to vascular control and excision of tumor and results from catecholamine surge. After tumor excision, circulating catecholamine level may precipitously drop. This begins the second phase, the hypotension phase. In addition to blood pressure changes, blood sugars must also be cautiously monitored as hypoglycemia ensues. Medications must be immediately available to treat any of the above conditions as they arise. Useful medications include sodium nitroprusside, phentolamine and diazoxide. Anti-arrhythmics, such as lidocaine, magnesium sulfate or bretyllium, should also be readily available.

Since 95% of tumors are intra-abdominal, a subcostal or transverse upper abdominal incision is traditionally employed. In certain circumstances (i.e., obese children), a flank approach might facilitate resection. Furthermore, in cases with tumors less than 10 centimeters, a laparoscopic approach is a consideration. Regardless of method used, the critical step in tumor resection is careful and rapid venous control of the tumor. Resection includes the involved adrenal gland unless an extra-adrenal tumor is the problem. Most intraoperative bleeding is encountered on the right side resulting from injury to the shorter, right adrenal vein. Prior to closure, a careful exploration of the contralateral adrenal gland, periaortic areas, mesentery, and retroperitoneum, is performed to identify either synchronous or metastatic disease. A few surgeons advocate a contralateral adrenal biopsy.

## Outcomes

Children with benign tumors who undergo resection do remarkably well. Surgical mortality is less than 5%. Recurrence does unfortunately occur and usually does so within 5 years of initial resection. Patients with MEN II are at highest risk for recurrence. Accordingly, many surgeons advocate routine bilateral adrenalectomy in syndromatic patients on initial exploration. However, others find this approach excessively radical and propose that partial contralateral adrenalectomy or even routine observation suffice. This eliminates the need for longterm steroid replacement. If blood pressure does not normalize within 2 weeks postoperatively, a search for a second primary tumor or metastasis is required. Metastases occur in tissues where chromaffin cells are otherwise absent; lymph nodes, liver, lung and bone. In patients with metastatic disease, combined modality chemotherapy or MIBG therapy are options. Radiation therapy is also considered. Few studies are available regarding long-term outcomes and treatment results in pediatric patients with malignant pheochromocytoma.

## Selected Readings

1. Doski JJ, Robertson FM, Cheu HW. Endocrine tumors. In: Andrassy RJ ed. *Pediatric Surgical Oncology*. Philadelphia: W.B. Saunders Company 365-403.
2. Caty MG, Coran AG, Geagen M et al. Current diagnosis and treatment of pheochromocytoma in children. *Arch Surg* 1990; 125:978.
3. Ein SH, Weitzman S, Thorner P et al. Pediatric malignant pheochromocytoma. *J Pediatr Surg* 1994; 29:1197.
4. Turner MC, Lieberman E, DeQuattro V. The perioperative management of pheochromocytoma in children. *Clin Pediatr* 1992; 10:1248.

# Hyperparathyroidism

*P. Stephen Almond*

## Incidence

Hyperparathyroidism is uncommon in the pediatric population.

## Etiology

In the fourth week of gestation, the rostral end of the fetus is characterized by six branchial arches, each with its own artery, nerve, and mesenchymal core. Externally, these arches are separated by clefts (branchial clefts) and internally by pouches (branchial pouches). The third and fourth branchial pouches each develop a dorsal and ventral wing. In the fifth week, the dorsal wing of each differentiates into parathyroid tissue while the ventral wings differentiate into thymus (third branchial pouch) and the ultimobranchial body (fourth branchial pouch). Due to its connection with the thymus, the parathyroid tissue of the third branchial pouch is pulled below that of the fourth to become the inferior parathyroid glands. The parathyroid tissue of the fourth pouch becomes the superior parathyroid.

Parathyroid hormone is an 84 amino acid, polypeptide chain secreted by the parathyroid glands in response to low serum calcium. The hormone is cleaved into a biologically active amino-terminal fragment and an inactive, but easily measured, carboxyl-terminal fragment. The active fragment binds to receptors on bone and renal tubule cells, stimulating adenylate-cyclase and the generation of cyclic AMP (cAMP). Within bone cells, an increase in intracellular cAMP causes resorption of bone with release of calcium and phosphate. Within the renal tubule, increased intracellular cAMP in response to PTH causes calcium resorption, phosphaturia, and magnesium resorption. In addition, PTH increases intestinal absorption of calcium by stimulating the conversion of 25-hydroxycholecalciferol vitamin D to the more potent, 1,25-dihydroxycholecalciferol vitamin D.

Hyperparathyroidism is either hereditary or sporadic and may result from hyperplasia, adenoma, or malignancy. Neonatal hyperparathyroidism is rare, autosomal recessive in some cases, and due to four gland hyperplasia. Familial hyperparathyroidism is more common, autosomal dominant or autosomal recessive in some cases, and due to chief-cell hyperplasia. Parathyroid adenoma is the most common cause of hyperparathyroidism in children. Only two cases of parathyroid cancer have been reported in children.

## Clinical Presentation

The hyperparathyroid state affects the nervous, genitourinary, gastrointestinal, and musculoskeletal systems. Therefore, the presenting symptoms are often vague, nonspecific, and difficult to substantiate. In neonatal hyperparathyroidism, the newborn presents with failure to thrive, dehydration, respiratory distress, and poor feeding. On examination, the infant may appear lethargic, underweight, and have decreased muscular tone. The vast majority of older children with hyperparathyroidism are sporadic cases. These children present with bone pain, weakness, vague gastrointestinal symptoms, nephrocalcinosis, and nephrolithiasis. Frequently, the physical examination is unremarkable.

Children with familial hyperparathyroidism [MEN type I (pituitary adenoma, hyperparathyroidism, and pancreatic neoplasm), MEN type IIA (medullary carcinoma of the thyroid, hyperparathyroidism, and pheochromocytoma), and familial hypocalciuric hypercalcemia] are usually identified during screening of previously diagnosed family members. Nevertheless, history and physical examination should be aimed at identifying familial cases.

## Diagnosis

The diagnosis of hyperparathyroidism is based on elevated serum calcium ( $> 11$  mg/dl) and PTH levels. In  $> 90\%$ , the serum calcium to phosphorus ratio is  $> 33$ . Serum creatinine and BUN are measured to assess volume status and renal function. A 24-hour urine collection for calcium is sent to rule out familial hypocalciuric hypercalcemia. A urine calcium level  $< 100$  mg/24 hours is suggestive of this diagnosis.

## Pathology/Pathophysiology

Hyperparathyroidism is due to hyperplasia, adenoma, or malignancy. Adenoma is the most common cause in children. Chief cell hyperplasia is the cause in neonatal hyperparathyroidism and familial hyperparathyroidism. Malignancy is extremely rare.

## Treatment

Once the diagnosis of primary hyperparathyroidism is established, surgical exploration of the neck is indicated. Preoperatively, the serum calcium should be lowered into the normal range with saline infusion and Lasix. If this is unsuccessful, mithromycin may be used.

At operation, the skin and platysma are divided transversely along a curvilinear line 1 cm above the clavicles and extending between the sternomastoid muscles. The strap muscles are separated in the midline and retracted laterally. The thyroid gland is inspected, palpated, and mobilized by dividing the middle thyroid veins and the superior thyroid arteries. The lobes of the thyroid are rotated medially and all four glands are visualized and biopsied. If all four glands are not identified, consideration should be given to:

1. exploring the carotid sheath,
2. exploring the retroesophageal space,

3. exploring the thymus, and
4. performing thyroid lobectomy on the affected side. Sternotomy is generally not performed at the first operation.

The amount of parathyroid tissue to be removed depends on the preoperative diagnosis and the appearance of the glands at operation. Neonatal hyperparathyroidism and MEN I are associated with chief cell hyperplasia and therefore, require either total parathyroidectomy with autotransplantation of one gland or three and one-half gland resection. Due to an increased risk of Hypoparathyroidism, children with MEN IIA should have only enlarged glands removed. MEN IIB patients do not require parathyroidectomy. Single adenomas should be removed after confirming three other normal glands. Meticulous hemostasis is obtained prior to wound closure.

## Outcomes

Complications of parathyroidectomy include:

1. damage to the recurrent laryngeal nerve (< 1%),
2. persistent or recurrent hyperparathyroidism (< 5%),
3. Hypoparathyroidism, and
4. hematoma (rare).

Recurrent laryngeal nerve injury may be secondary to transection, ligation, or blunt trauma to the nerve. Although immediate repair is the treatment of choice for a transected nerve, delayed repair, anastomosis to the vagus nerve, burying the nerve in the posterior cricoarytenoid muscle have been described. Injury to the nerve causes the affected vocal cord to assume a more medial position and can be identified with laryngoscopy at the end of the procedure. Reversible injuries to the nerve usually resolve within ten weeks.

Persistent hyperparathyroidism means that the patient remains hypercalcemic postoperatively. This is usually due to misdiagnosis or retained hyperplastic or adenomatous tissue. In recurrent hyperparathyroidism, the patient has a period of normocalcemia followed by a return of hypercalcemia. This may be seen with parathyroid cancer, familial hyperparathyroidism, and familial hypocalciuric hypercalcemia. In the later two cases, the pathology is chief cell hyperplasia. At operation, however, only enlarged glands are removed under the erroneous assumption that they are adenomas.

Hypoparathyroidism may be permanent or transient. Clinical signs of hypocalcemia include circumoral numbness and tingling, peripheral paresthesias, hyperactive tendon reflexes, positive Chvostek's and Trousseau's signs, muscle cramps, tetany, and prolonged Q-T interval. Symptomatic patients are placed on a cardiac monitor and treated with IV calcium gluconate infusion and Calcitrol (1,25 dihydroxycholecalciferol vitamin D). As symptoms resolve and the calcium is corrected, calcium supplementation is converted to oral calcium carbonate (i.e., Caltrate, TUMS) and Calcitrol.

A neck hematoma may present as life-threatening, respiratory distress. In this scenario, the wound should be opened at bedside followed by immediate exploration in the operating room.

### *Selected Readings*

1. Allo M, Thompson NW, Nishiyama R. Primary hyperparathyroidism in children, adolescents, and young adults. *World J Surg* 1982; 6:771.
2. Thompson NW, Carpenter LC, Kessler DL. Hereditary neonatal hyperparathyroidism. *Arch Surg* 1978; 113:102.
3. Harman CR, van Heerden JA, Farley DR et al. Sporadic primary hyperparathyroidism in young patients: a separate disease entity? *Arch Surg* 1999; 134:651.

# Neonatal Hypoglycemia

*Daniel A. Bambini*

## **Incidence**

Although hypoglycemia in the newborn period is relatively common, hyperinsulinism only accounts for about 1% of cases of hypoglycemia in neonates. Nonetheless, neonatal hyperinsulinism is the most common cause of persistent hypoglycemia in the newborn, identifiable in about 50% of this group.

## **Etiology**

Hypoglycemia in the newborn can result from hyperinsulinism, inborn errors of hepatic metabolism, hormonal deficiencies and a variety of other causes. The most common causes of neonatal hypoglycemia are listed in Table 92.1. In the neonate or infant under 1 year of age, the most common cause of hyperinsulinism is nesidioblastosis. Beyond one year, pancreatic adenoma is more common.

## **Pathology/Pathophysiology**

### *Nesidioblastosis*

All cells of the pancreas are believed to arise from primordial duct cells. Nesidioblastosis refers to the process by which islet cells bud from the pancreatic ducts and is a normal part of fetal pancreatic development. The hyperinsulinism of early infancy has often been attributed to the persistence of “nesidioblasts” within the pancreas, either focal or diffuse, beyond the fetal period. Because nesidioblasts are often identifiable in normal newborns as well, the pathophysiological problem is now believed to be secondary to abnormal mechanisms of insulin storage and release. The pathologic findings in pancreatic specimens taken from these infants are often completely normal but sometimes demonstrate:

1. focal nesidioblastosis,
2. diffuse nesidioblastosis,
3. islet cell hypertrophy,
4. nuclear hypertrophy,
5. cellular dysplasia, or
6. adenomatosis.

The pathologic findings do not correlate well with the clinical severity of disease.

**Table 92.1. Causes of neonatal hypoglycemia**

Cause	Transient	Hyperinsulinism	Persistent or Recurrent
Birth asphyxia	+		
Starvation	+		
Sepsis and/or hypothermia	+		
Congenital heart disease	+		
Low birth weight	+		
Interruption of venous infusion	+		
Excess exogenous insulin	+	+	
Infant of diabetic mother	+	+	
Erythroblastosis fetalis	+	+	
Beckwith-Wiedemann Syndrome	+	+	
Insulinoma		+	+
"Nesidioblastosis"		+	+
Leucine-sensitive hypoglycemia		+	+
Adrenal disease/cortisol deficiency *			+
Growth hormone deficiency			+
Hypopituitarism *			+
Inborn error of hepatic metabolism*			+

\* associated with decreased glucose production

### *Islet Cell Adenoma*

Insulin-secreting islet cell adenomas generally occur in older children (> 3-4 years) not infants. Seventy-five percent of adenomas arise in the body and tail of the pancreas. Approximately 15% of these tumors are multicentric. Malignant insulinomas are extremely rare in children. Grossly, the tumors appear "pink", are usually well-encapsulated (pseudocapsule), and are sometimes found in association with nesidioblastosis.

### **Clinical Presentation**

Hypoglycemia in the newborn is associated with nonspecific, often subtle, clinical findings. It should be expected or anticipated in neonates that are premature or small for gestational age. Infants born to diabetic mothers are at risk for hypoglycemia and often have transient hyperinsulinism (due to high glucose levels in utero). These babies are frequently large for gestational age.

The presenting symptoms and/or signs of neonatal hypoglycemia include apnea, cyanosis, limpness, irritability, tremors, seizures, coma, lethargy and hypothermia. In older children, hypoglycemia may commonly present as nervousness, fatigue, or seizures. As expected, symptoms are relieved by eating. Physical findings are usually unremarkable, except in infants with other associated conditions. Most infants have a high birth weight and hepatomegaly (from excess glycogen storage). The differential diagnosis of neonatal hypoglycemia is vast. Broadly speaking, hypoglycemia usually arises from hyperinsulinism, endocrine disorders, or inborn errors of hepatic metabolism.

The Beckwith-Wiedeman syndrome is highly associated with hypoglycemia. Features of this syndrome include macroglossia, gigantism, omphalocele. Some of these infants may have nesidioblastosis but the hypoglycemia usually resolves with medical therapy.

### Diagnosis

The diagnostic work-up may be fairly urgent to avoid cerebral damage and mental retardation associated with inadequately treated neonatal hypoglycemia. Endocrinologic and metabolic evaluation is indicated for hypoglycemia that:

1. lasts greater than one week after birth,
2. is refractory to glucose infusion, or
3. is acquired after discharge from the nursery.

The diagnostic work-up should include simultaneous measurements of serum glucose and assay for serum insulin level. A normal or elevated insulin level in the setting of hypoglycemia indicates hyperinsulinism.

The normal expected values for serum glucose in neonates is age-dependent. Term infants less than 24 hours old should have serum glucose levels exceeding 35 mg/dl. Beyond 24 hours, the serum glucose should remain above 45 mg/dl. Early after birth (< 72 hrs) premature/LBW infants should have serum glucose levels greater than 25 mg/dl. Hypoglycemia, during the first three days of life, is defined as a serum glucose less than 30 mg/dl in full term neonates or less than 20 mg/dl in low birth weight infants. Beyond 72 hours of age, hypoglycemia is defined as a serum glucose less than 40mg/dl.

The principle diagnostic criteria for hyperinsulinism are:

1. serum insulin > 10 mU/ml with simultaneous serum glucose < 50 mg/dl, and
2. glucose requirement to maintain serum glucose above 35 mg/dl exceeding 10 mg/kg/min.

Other indicators of hyperinsulinism are low serum concentrations of free fatty acids and ketones and a glycemic response to parenterally administered glucagon. Plasma or urinary C peptide levels are elevated.

### Treatment

Prompt identification and treatment of hypoglycemia is essential to prevent permanent central nervous system damage. Initial medical therapy includes providing intravenous glucose at concentrations of 15-20% dextrose at a rate sufficient to maintain normoglycemia. Sometimes infusions of 10-25 mg glucose/kg/min are required to maintain normoglycemia. Central venous catheterization is required.



Frequent feeds can provide additional glucose. Refractory hypoglycemia may be treated by several pharmacologic agents including diazoxide, octreotide, and glucagon. Other agents that have been used are mesoxalyl urea, corticosteroids and alpha-adrenergic agents. Medical therapy controls hypoglycemia in about 50-75% of patients. Neonates that cannot maintain a fast despite optimal medical management should be considered for surgery.

Surgical therapy reduces insulin secretion by resecting pancreatic mass containing the beta cells. It is unusual to find any macroscopically visible lesion (i.e., adenoma) within the pancreas at the time of laparotomy. The amount of pancreatic tissue that should be resected is a controversial point. Subtotal (75%) pancreatectomy results in a treatment failure rate of at least 50%. A spleen-sparing 95% pancreatectomy is recommended by many but occasionally this results in postoperative endocrine insufficiency. In the 95% resection, the pancreatic head, body and uncinata process are resected leaving only the rim of pancreatic tissue on the common bile duct and duodenum.

## Outcomes

Postoperative complications include:

1. persistent or recurrent hypoglycemia,
2. mental retardation,
3. diabetes mellitus.

Hyperglycemia after 95% resection is usually only transient but late diabetes mellitus has been reported in some patients as they enter adolescence. In patients having 75% resections, almost 30% may require an additional resection to control hypoglycemia. A 95% pancreatectomy does not absolutely prevent hypoglycemia as 5% of these patients may eventually require a second resection of pancreas which hypertrophies. Another 10% may require diazoxide to control hypoglycemia, while 7-8% may need long-term insulin to control hyperglycemia. The mortality rate for 95% pancreatectomy is around 2.5%.

## Selected Readings

1. Shilyansky J, Cutz E, Filler RM. Endogenous hyperinsulinism: Diagnosis, management, and long-term follow-up. *Sem Pediatr Surg* 1997; 6(3):115-120.
2. Spitz L, Bhargava RK, Grant DB et al. Surgical treatment of hyperinsulinemic hypoglycemia in infancy and childhood. *Arch Dis Child* 1992; 67:201-105.
3. Jaffe R, Hashida Y, Yunis EJ. Pancreatic pathology in hyperinsulinemic hypoglycemia of infancy. *Nature Med* 2:2344-2347.
4. Leibowitz G, Glaser B, Higazi AA et al. Hyperinsulinemic hypoglycemia of infancy (nesidioblastosis) in clinical remission: High incidence of diabetes mellitus and persistent beta-cell dysfunction at long-term follow-up. *J Clin Endocrinol Metab* 1995; 80:386-392.

## Intersex

*Daniel A. Bambini*

Sex assignment at birth is usually a straight forward anatomical decision. Confusion may occur if an anomaly of genital development occurs. Disorders of intersex occur when the phenotypic sex of an infant or child is discordant with his/her gonadal, genotypic, or hormonal sex.

### Incidence

Intersex anomalies are exceedingly rare; a precise overall incidence is not known. Approximately 4-6 of every 10,000 births have some form of genital ambiguity. In the United States and Western Europe, female pseudohermaphroditism is the most common intersex disorder. Congenital adrenal hyperplasia, the most common cause of female pseudohermaphroditism, occurs between 1 in 5,000-15,000 live births. Testicular feminization syndrome, a form of male pseudohermaphroditism, occurs between 1 in 20,000-64,000 live male births. True hermaphroditism is the rarest of these disorders; less than 500 cases have been reported in the world literature this century.

### Development of the Gonads and Genitalia

Normal gonadal development is a complex and precise series of events. The undifferentiated gonad is bipotential and the Y chromosome is essential for development of the testes. The SRY gene produces a protein that initiates development of the gonad into the testes. Presence of the SRY gene at fertilization may be the primary determinant of gonadal sex. Two X chromosomes are required for ovarian differentiation. During the fifth week of gestation, germ cells with XX or XY chromosomes migrate from the yolk sac to the retroperitoneum to form germinal epithelium at the anteromedial urogenital ridge. Gonadal induction begins at the sixth week with growth of these germ cells into the underlying mesenchyme. During the seventh week of gestation, sex cords and seminiferous tubules in males. Sertoli cells begin to produce Mullerian inhibiting substance (MIS), during the eighth week of gestation. In females, primary follicles develop but usually not until the 9th-10th week of gestation. Female development occurs in the absence of ovaries or gonads. Male development only occurs if testosterone (androgen) is present.

By the sixth week of gestation there are two pairs of genital ducts in the embryo whether male or female. The Wolfian (mesonephric) ducts are located posteromedial to the urogenital ridge and drain the mesonephric kidney. Under the influence

of testosterone (Leydig cell), Wolfian ducts develop into the male genital ducts including the vas deferens, seminal vesicles, and epididymis. The Mullerian ducts arise anterolateral to the urogenital ridge. Mullerian ducts give rise to the uterus, fallopian tubes, and vagina in the female. In males, MIS (Sertoli cell) prevents development of the Mullerian structures that regress and disappear. Testosterone, produced by the Leydig cells, stimulates Wolfian duct development and formation of the vas deferens, seminal vesicles, and epididymis. In females, MIS is absent and the Mullerian ducts develop into the uterus, fallopian tubes, and vagina.

Development of the external genitalia normally occurs during the 9th through 12th weeks of gestation. The genital tubercle and labioscrotal folds are identifiable in the 4th week of gestation. In the absence of testosterone, the genital tubercle will develop into the female clitoris and the labioscrotal folds become the labia minora and majora. Development of male external genitalia requires reduction of testosterone to dihydroxytestosterone (DHT) by 5-reductase. Under the influence of DHT, the genital tubercle enlarges to form the penis, the labioscrotal folds fuse in the midline to form the scrotum, and the urogenital sinus closes.

### Classification and Etiology

The four major categories of intersex anomalies are:

1. male pseudohermaphroditism,
2. female pseudohermaphroditism,
3. true hermaphroditism, and
4. mixed gonadal dysgenesis. Multiple etiologies have been identified for each.

Male pseudohermaphroditism results from incomplete masculinization or complete feminization in a genetic male (XY karyotype). Etiologies include:

1. inadequate biosynthesis of testosterone by the Leydig cell,
2. inability to convert testosterone to dihydroxytestosterone, or
3. absent/impaired binding of testosterone to the androgen receptor.

Enzymatic defects in 20-22 desmolase, 3-hydroxysteroid dehydrogenase, 17-hydroxylase, 17-20 desmolase, or 17-ketosteroid reductase can cause testosterone deficiency. Adrenal insufficiency is also common in first three. Testicular feminization is an X-linked recessive syndrome that results from a defect in androgen receptor function. Although external genitalia are normal and female, MIS function is also normal, and there are no internal Mullerian structures present. Another variant of male pseudohermaphroditism is the retained Mullerian duct syndrome. In this syndrome, MIS production is defiant or the receptor for MIS is abnormal, yet testosterone metabolism and function is normal. In males so affected, the testes will be undescended and Mullerian structures will persist (i.e., uterus, fallopian tubes, vagina).

Female pseudohermaphroditism is definable as abnormal masculinization in a genetic female (XX karyotype). Female pseudohermaphroditism is usually caused by exposure to endogenous or exogenous androgens in utero. Masculinization is often severe. The most common cause is congenital adrenal hyperplasia (CAH) as a result of an enzymatic deficiency in the biosynthesis of corticosteroid. The enzymatic deficiency responsible for 95% of cases CAH is 21-hydroxylase deficiency. Salt wasting occurs in 75% of those with 21-hydroxylase deficiency secondary to

mineralcorticoid insufficiency. Deficiencies of 11-hydroxylase or 3-hydroxysteroid dehydrogenase can also cause CAH and female pseudohermaphroditism.

True hermaphroditism usually occurs in individuals with a 46XX karyotype, yet rare individuals with 46XY or mosaic karyotypes have been reported. Many 46XX hermaphrodites have detectable HY antigen suggesting translocation of the short arm of the Y chromosome containing a retained SRY segment. The 46 XX/46XY mosaics are considered chimeras resulting from fusion of two fertilized ova and usually have an ovary on one side with a testes on the contralateral side. In these cases, the internal ducts are consistent with their ipsilateral gonad. The majority of true hermaphrodites have an ovotestis. The testicular tissue of either the unilateral testis or ovotestis may be dysgenetic. True hermaphroditism is defined by the presence of both ovarian and testicular tissue.

Mixed gonadal dysgenesis results from inadequate induction and formation of the gonad. Most commonly, these individuals have sex chromosomal mosaicism (45X/46XY) and a dysgenetic testis on one side with a streak gonad on the other. Other individuals in this group may have unilateral gonadal agenesis or bilateral streak gonads. About 40% of this group have a pure 46XY karyotype. Presence of a Y chromosome increases the risk of tumor formation

### Clinical Presentation

Intersex anomalies are generally apparent at birth in the delivery room or on initial physical examination because of genital ambiguity. Accurate gender assignment may initially be impossible. Occasionally, genital ambiguity is overlooked in the neonate, and these children with intersex anomalies may present at adolescence. Any male with bilateral inguinal hernias and hypospadias is considered to potentially have an intersex disorder until proven otherwise.

Evaluation of the intersex infant should include elucidation of history of maternal exposure to drugs including alcohol, androgens and progesterone. Maternal ingestion of hydantoin-based drugs or phenobarbital may effect cytochrome p450 enzymes essential for fetal steroid synthesis and metabolism. A thorough physical examination is essential. The genitalia should be inspected for:

1. gonadal symmetry,
2. scrotal position relative to the penis,
3. darkened genital or areolar coloration,
4. roflation of the labioscrotal folds,
5. size and degree of chordee of the phallus,
6. position of the urethral meatus
7. dehydration consistent with salt wasting.

Physical findings that suggest an intersex problem include:

1. clitoromegaly,
2. penoscrotal or perineoscrotal hypospadias with bilateral cryptorchidism,
3. penoscrotal or perineoscrotal hypospadias with a unilateral palpable gonad, and
4. micropenis without palpable gonads.

Dysmorphic features (i.e., shield chest, wide spaced nipples, web neck, etc.) suggest an underlying chromosomal abnormality. Rectal exam/bimanual exam to assess for a midline positioned uterus is required.

## Diagnosis

Preliminary diagnosis of intersex disorders can be made with 90% accuracy using two criteria:

1. presence/absence of gonadal symmetry,
2. presence/absence of Barr body or chromatin mass on the buccal smear (Table 93.1).

Evaluation of intersex infant begins with a careful physical examination of gonadal symmetry. Gonadal symmetry refers to the relative position of one gonad to the other above/below the external inguinal ring. The majority of intersex anomalies are able to be classified relatively quickly with reasonable accuracy.

Laboratory testing that is indicated in the evaluation of intersex infants includes the buccal smear with Y fluorescence to identify Barr body/chromatin mass (i.e., second X chromosome). Additional blood specimens should be obtained to measure electrolytes (Na, K, glucose) and serum levels of gonadotropins LH and FSH, dihydrotestosterone (DHT), testosterone, 17-hydroxyprogesterone, 17-hydroxypregnenolone, androstendione, and dehydroepiandrosterone (DHEA), 11-deoxycortisol. Assay for MIS should also be performed. Measurement of testosterone levels in response to human chorionic gonadotropin (hCG) stimulation is particularly useful to determine the presence of testicular tissue and distinguish between hypogonadism or end-organ unresponsiveness. Blood should be sent for leukocyte culture to obtain karyotype.

Radiologic studies may be useful to define urogenital anatomy and confirm results from other studies. A genitogram may demonstrate the anatomy of internal ducts. Magnetic resonance imaging is preferred to ultrasound or computed tomography to further delineate internal anatomy because of its superior soft-tissue contrast resolution.

Surgical evaluation of the intersex infant may also include cystoscopy, laparoscopy, and gonadal biopsy. In cases with a persistent urogenital sinus, cystoscopy can help determine whether the vagina enters the urogenital sinus proximal or distal to the external urethral sphincter. Gonadal biopsy is usually necessary to complete the diagnostic work-up, except in those with congenital adrenal hyperplasia in which the diagnosis can be obtained from serum markers. Gonadal biopsy should be performed in a longitudinal orientation. Both gonads are biopsied in cases of gonadal asymmetry. Tissue should be studied to determine androgen receptor levels. Tissue culture may provide fibroblasts which can be used to determine 5-reductase levels.

## Treatment

Infants and children with intersex disorders should be treated as psychosocial emergencies. Expedient evaluation and treatment is indicated. After the initial diagnostic evaluation is completed, sex assignment is determined and surgical reconstruction is planned. Sex assignment is based upon many factors including:

1. anatomy,
2. diagnosis,
3. fertility potential,
4. age at time of diagnosis,
5. gonadal sex,

**Table 93.1. Classification and characterization of the common intersex abnormalities**

Category of Intersex	Gonadal Symmetry	Barr Body	Karyotype	Comment
Female Pseudohermaphroditism	Symmetric	Present	46 XX	CAH, excessive androgen present
Male Pseudohermaphroditism	Symmetric	Absent	46 XY	inadequate masculinization
True Hermaphroditism	Asymmetric	Present	46 XX, mosaics	testicular and ovarian tissue coexist
Mixed Gonadal Dysgenesis	Asymmetric	Absent	45 X,46 XY or 46 XY	abnormal gonads

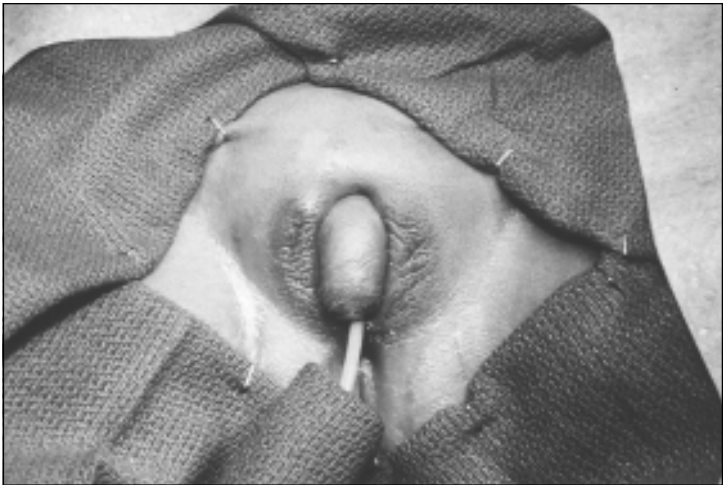

Fig. 93.1. Marked clitoromegaly (virilization) in an infant female with congenital adrenal hyperplasia.

6. genetic sex,
7. parental desires.

Anatomic potential is possibly the most important determinant of sex assignment. The majority of patients with intersex anomalies will be raised as female. All female pseudohermaphrodites with CAH are potentially fertile and should be raised as females if recognized early. All male pseudohermaphrodites with testicular feminization and most of those with partial androgen insensitivity syndrome should be raised as females. Male pseudohermaphrodites with 5-reductase deficiency have

normal testes capable of inducing significant masculinization at puberty. These individuals should be raised as males if recognized early.

Once the decision of sex assignment had been made, external anatomy can be either feminized or masculinized and discordant hormone production can be stopped. Early surgical and hormonal therapy are important to developing concordant gender identity. The goal of genitoplasty is to create external genitalia that are, as near possible, normal in appearance and function. Feminizing genitoplasty is performed in the neonatal period as soon as gender assignment has been determined; masculinizing genitoplasty is usually delayed until 1-2 years of age. Several surgical procedures are available to assist these patients including:

1. reduction clitoroplasty,
2. labioscrotal reduction,
3. low vaginoplasty,
4. flap vaginoplasty or vaginal pull through,
5. perineal reconstruction,
6. hypospadias repair,
7. descent of intraabdominal gonad,
8. removal of retained gonad.

In patients given male sex assignment, discordant ductal structures should be removed.

Decisions regarding management of the gonads requires consideration of potential for concordant or discordant hormone production/effects, and the risk of developing subsequent malignancy. The presence of a Y chromosome or HY antigen dramatically increases the risk of tumor formation. Patients with mixed gonadal dysgenesis have a 30-50% risk of developing gonadoblastoma; the risk is highest at and beyond puberty. Wilms' tumors occur in about 8% of patients with male pseudohermaphroditism. All streak gonads and testicular tissue that cannot be brought in to the scrotum should be removed. Streak gonads are at high risk for developing seminoma and dysgerminoma.

Hormonal and steroid replacement therapy must be monitored carefully to attain normal secondary sex characteristics and to achieve pubertal growth.

## Outcomes

For patients with CAH, immediate diagnosis with correct medical, surgical, and psychosocial treatment may lead to nearly normal sexual function. There is only limited information available about the psychosexual development of karyotypic females raised as males or karyotypic females raised as male. Masculinization or feminization of the brain is thought to occur very early in development. As adults, sexual orientation may not remain consistent with sex assignment, particularly when virilized neonates are assigned and raised as females.

## Selected Readings

1. Hughes IA. Intersex. In: Freeman NV et al, eds. *Surgery of the newborn*. New York: Churchill Livingstone 1994; 781-789.
2. Donahoe PK, Schnitzer JJ. Evaluation of the infant who has ambiguous genitalia, the principles of operative management. *Semin Pediatr Surg* 1996; 5:1.
3. Donahoe PK, Schnitzer JJ. Ambiguous genitalia in the newborn. In: O'Neill JA et al, eds. *Pediatric Surgery*, 5th edition. St. Louis: Mosby 1998; 1797-1817.

**Section XV: Miscellaneous Pediatric  
Surgical Topics**



# Short Bowel Syndrome

*Fawn C. Lewis and Daniel A. Bambini*

Short bowel syndrome (SBS) is a clinical condition in which the surface area of the small bowel is inadequate for the absorption of sufficient nutrients. It most commonly occurs as a result of massive small bowel resection. While preservation of the ileocecal valve may allow a larger resection without developing clinical features of small bowel syndrome, SBS has occurred following resections of as little as 40% of the small intestine, but most cases occur when more than 50% of the patient's total bowel length has been lost.

## Incidence and Etiology

The true incidence of SBS is unknown. The main conditions that result in SBS in infants and young children include:

1. atresia (32%),
2. volvulus (29%),
3. necrotizing enterocolitis (19%), gastroschisis (12%), and other conditions requiring massive bowel resection (7%). In older children, the primary causes of SBS are midgut volvulus and Crohn's Disease.

## Pathophysiology

Because intestinal mucosal function is site specific, resection of different segments leads to an array of different problems. Jejunal mucosa secretes cholecystokinin (CCK) and secretin; its brush border is rich in carbohydrate digesting enzymes. The jejunum absorbs calcium, magnesium, and iron. The ileum absorbs carbohydrates, proteins, water, and electrolytes and is the primary absorption site of bile acids (i.e., enterohepatic circulation), vitamin B12, and fat-soluble vitamins (i.e., A, D, E, and K). The major functions of the colon are to absorb water and sodium. The colon excretes potassium and bicarbonate. As a result, combined resection of small bowel and colon leads to greater water loss, dehydration, hypokalemia, hypomagnesemia, and hyponatremia similar to that observed in patients with end jejunostomies. The major consequences of small bowel resection are listed in Table 94.1.

Following small bowel resection, nutrients within the gut lumen stimulate trophic hormone production (Table 94.2), stimulate release of trophic pancreatic and biliary secretions, and provide a direct source of nutrients to the enterocytes. As the number of enterocytes increases, villous hypertrophy occurs and the small bowel

**Table 94.1. Consequences of massive small intestinal resection**

Dehydration proportional to length resected-especially if colon is resected
Nutrient Malabsorption: fat soluble vitamin deficiency (A, D, E, K), starch, disaccharides, iron, folate, B12, Zinc
Fat malabsorption: steatorrhea, impaired absorption of Calcium, Magnesium, and Zinc
Electrolyte loss: Sodium, Potassium, Calcium, Magnesium, Zinc
Bile Acid Malabsorption
Bacterial overgrowth of remaining small bowel, especially with ileocecal resection.
Gastric Acid Hypersecretion, usually not seen unless there is a > 66% resection
D-Lactic Acidosis caused by bacterial fermentation of lactose to lactate
Nephrolithiasis
Cholelithiasis
TPN complications: both hepatic and catheter-related

**Table 94.2. Stimulants for reactive intestinal hypertrophy**

Glutamine	Preferred fuel for small bowel mucosal cells
Butyrate	Preferred fuel for colonic mucosa
Hormones and stimulants	enteroglucagon, bombesin, epidermal growth factor, glucocorticoids, prostaglandin E2, ornithine decarboxylase

dilates and lengthens. This compensatory response does not occur if nutrients are not present in the gut lumen.

In general, the loss of a portion of the jejunum is better tolerated than a similar loss of ileum although the ileum responds with more villous hyperplasia than does the jejunum. The permeability of intracellular tight junctions in the ileum is less, allowing for an increased ability to concentrate luminal contents. In addition, the ileum and ascending colon are much better at absorbing sodium chloride against a gradient than are the other segments of bowel. However, resection of the ileum leads to decreased reabsorption of bile salts and loss of the ileocecal valve allows bacterial overgrowth within the small intestine.

### Clinical Presentation

The possibility of SBS is considered whenever an infant or child has undergone a major intestinal resection. The first clinical indicator of SBS is frequently diarrhea. Electrolyte instability commonly follows, as do fatty acid and vitamin deficiencies, weight loss and growth retardation. The diagnosis is mostly clinical.

As a general guideline, the total small bowel length in an individual is approximately equal to 3-5 times the height of the individual. When estimating bowel length following resections performed on premature or low birth weight infants, the gestational age is considered because the intestine lengthens significantly over the last 17 weeks of gestation (Fig. 94.1). In theory, it is possible for the intestine in a 30-week premature infant to double in length by the time the infant reaches 40 weeks of gestational age.

### **Initial Treatment**

Nutrients are required in the intestinal lumen to decrease mucosal atrophy and stimulate reactive hyperplasia. The amino acid glutamine is directly used by the enterocytes so its introduction enterally helps preserve mucosal mass. Serum levels of Vitamins A, D, E, and K are measured and supplemented as necessary. Bacterial overgrowth is treated by periodic courses of oral antibiotics (i.e., metronidazole, vancomycin, trimethoprim/sulfamethoxazole, or ciprofloxacin). Encephalopathy and lactic acidosis are caused by elevated serum levels of D-Lactate and also respond to oral antibiotic therapy.

Intravenous nutrition is required to supplement calories while the intestinal mucosa hypertrophies and adapts. Enteral feeds are introduced and advanced slowly and methodically to deliver maximally tolerated enteral calories and protein. Tight control of osmolality, volume, and composition is maintained. Peptides are the major protein source and glucose polymers are well tolerated as the initial carbohydrate source. Long chain triglycerides and short chain fatty acids are added gradually and are also trophic to the mucosa. Medium chain triglycerides (MCTs) are directly absorbed and do not require lipase or bile acids for absorption. Unfortunately, MCTs are not trophic for the gut. Later, fiber (pectin) is gradually added as are Vitamins B12, E, D, and A.

Additional therapies include histamine-2 ( $H_2$ ) receptor antagonists to control gastric acid hypersecretion, somatostatin to reduce pancreatic and biliary secretions, loperamide to slow gut motility, and cholestyramine to decrease diarrhea from bile salt malabsorption. Cholestyramine does not improve steatorrhea, or diarrhea that results from fat malabsorption. Growth hormone (GH) may also play a role in hypertrophy and GH supplementation is being evaluated as an aid to recovery. The goal of therapy is to improve bowel recovery and function so that the intestine is eventually capable of absorbing required nutrients and the patient is no longer dependent on parenteral nutrition

### **Late Treatment**

After optimal medical therapy for 2-3 years, the intestine adapts to its full potential. If nutrient malabsorption remains, multiple surgical options are available but most have had limited success. The Bianchi procedure is perhaps the most successful method used to increase intestinal length. In this procedure, the vessels supplying each side of the bowel are separated into two leaves right at the mesenteric border. The bowel is divided longitudinally into two halves, each supplied by one set of the mesenteric vessels. The two segments of bowel are reconstructed as tubes

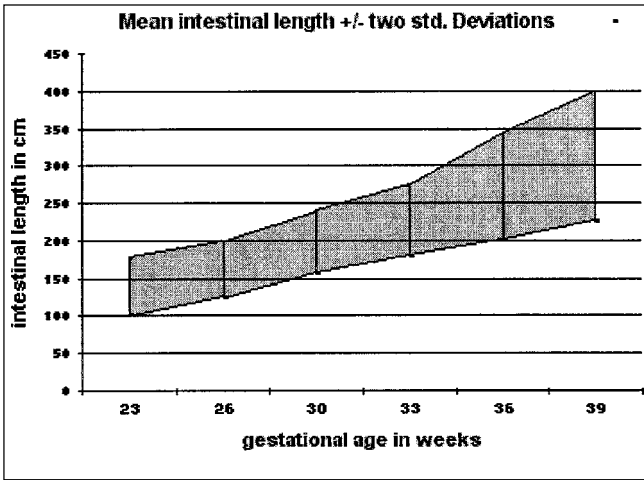


Fig. 94.1. Intestinal length by gestational age.

and then anastomosed end-to-end, effectively doubling the length of the intestine. Although this procedure has gained both successes and supporters, enthusiasm for it has waned in the era of small bowel transplantation. Yet, small bowel transplantation continues to have high mortality and morbidity. Overall, the results of pediatric small bowel transplantation are improving with recent advances in antirejection therapy.

## Outcomes

An overall survival of 82% is reported for patients with SBS. Of these, 62% adapt to survive on enteral nutrition alone. Patients surviving and adapting with an ileocecal valve are reported to have an average of 18.5 cm of small intestine (range 10-35 cm). Patients surviving and adapting without an ileocecal valve in place are reported to have an average of 19.4 cm of small intestine (range 10-25 cm). The ability to achieve adaptation may be independent of the presence of the ileocecal valve.

## Selected Readings

1. Bianchi A. Intestinal loop lengthening—a technique for increasing small intestinal length. *J Pediatr Surg* 1980; 15:145-151.
2. Touloukian RJ, Smith GJ. Normal intestinal length in preterm infants. *J Pediatr Surg* 1983; 18:720-723.
3. Grosfeld JL, Rescorla FJ, West KW. Short bowel syndrome in infancy and childhood: analysis of survival in 60 patients. *Am J Surg* 1988; 151:41-46.
4. Collins JB, Georgeson KE, Vicente Y. Short bowel syndrome. *Sem Pediatr Surg* 1995; 4:60-72.

# Conjoined Twins

*Robert M. Arensman*

## Incidence

Twinning is reasonably rare and conjoined twinning is extremely rare. The exact incidence is not completely known. Based on various demographic reports, occurrence varies from 1: 25,000 to 1: 200,000 births, but the latter figure more accurately reflects live born conjoined twins since there is a high rate of stillbirth (>60%). Interestingly, about 75% of conjoined twins are female.

## Etiology

The stimulus to incomplete twinning is not known, but these twins appear to be monozygotic, monchorionic twins who fail to make complete separation in the blastula stage of embryonic development (12-16 days after fertilization). Very rarely, conjoined twins may result from fusion of separate embryos. In the few documented cases, one of the fused embryos appears to be a parasitic appendage on the other.

## Classification

Conjoined twins are classified based on the site of union. The descriptive names are derivations of the Greek work "pagos" which means "that which is fixed."

Many variations on these standard types exist, including the variation known as "two headed monster," a particularly unfortunate group with two heads and upper spines that quickly fuse into one body with two arms, two legs and a common lower spine. Generally each head controls half of the body so each twin controls only one arm and leg.

These general types can be further described to indicate number of limbs. One often sees words such as tripus (three legs) or tetrapus (four legs) appended to the major descriptor; hence a description such as "ischiopagus tetrapus" describes a pair of conjoined twins joined at the pelvis with a combined total of 4 lower extremities.

## Clinical Presentation

The condition is apparent at birth. Simple inspection confirms the diagnosis and generally allows for broad classification. Diagnostic studies are chosen to identify and document the exact type and number of anomalies. This process allows final classification and formulation of a plan for surgical separation if possible.

**Table 1. Classification of conjoined twins**

Type	Site of Union	Relative Incidence
Thoracopagus	Chest	40%
Omphalopagus	Abdomen	30%
Pyopagus	Sacrum	20%
Ischiopagus	Pelvis	5%
Craniopagus	Head	2%

### Diagnosis

Ultrasonographic studies document number of hearts, union of hearts, intracardiac anomalies, genitourinary anomalies, and gynecologic anomalies. Computed tomography and contrast studies are extensively used to locate organs, study spinal and cranial unions, and sort out gastrointestinal anatomy. Portions of the gastrointestinal tract are often combined or shared by both twins.

Preoperative evaluation and documentation to the greatest extent possible allows good surgical planning. It also allows realistic counseling with parents regarding chance for survival, life-long disabilities, and quality of life.

### Treatment

In the past, surgical separation has usually been attempted with the hope of improving quality of life. However, surgical separation results in 30-40% mortality of one or both twins. If the surgical separation becomes emergent, mortality increases to 70%. At present, longer periods of observation and evaluation are common, and in some cases families have rejected surgery when risk of surgery is high or sacrifice of one twin is certain. Survival in the conjoined state is possible with normal life expectancy. Furthermore, thoracopagus twins with a conjoined heart(s) have never been separated successfully (i.e., no single survivors).

### Outcomes

With careful preoperative evaluation and conscientious intraoperative and perioperative care, up to 60% of conjoined twins can be successfully separated and approximately 60% of these separated twins will survive and have reasonably successful lives. The survival group includes many children who have life-long ostomies for urinary or gastrointestinal diversion, have artificial extremities, and require repetitive surgeries to correct ongoing cosmetic or functional defects. Nevertheless, this situation is far from hopeless. Each set of conjoined twins should be carefully studied and evaluated to provide the best long-term care available.

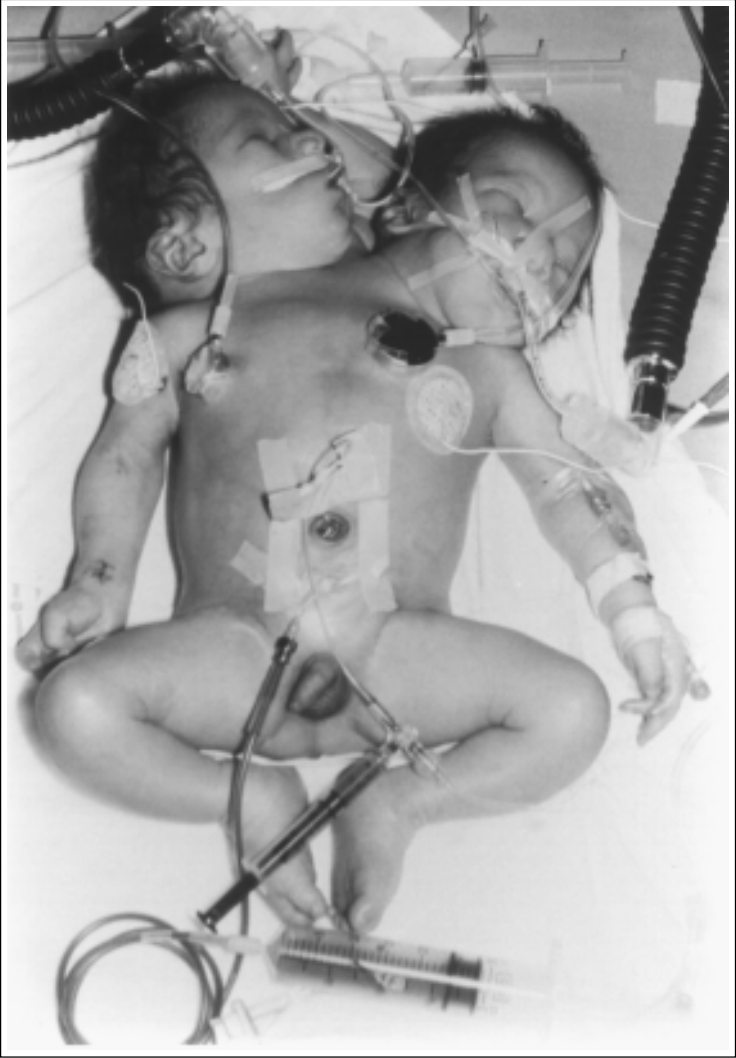

Fig. 95.1. Conjoined twins with complete union below the high thoracic level. These twins share a single conjoined heart and have fusion of the spine posteriorly. Separation of this type of union is currently not feasible.

*Selected Readings*

1. Hoyle RM: Surgical Separation of Conjoined Twins. *Surg Gyn Obst* 170: 549-562, 1990.
2. Wilcox DT, Quinn FM, Spitz L et al. Urological problems in conjoined twins. *Brit J Uro* 81(6): 905-910, 1998.
3. Cywes S, Millar AJ, Rode H et al. Conjoined twins—the Cape Town experience. *Ped Surg Int* 12(4): 234-248, 1997.
4. Spencer R. Conjoined twins: theoretical embryologic basis. *Teratology* 45(6): 591-602, 1992 (25 references).



# Minimally Invasive Pediatric Surgery

*Harry T. Papaconstantinou and Dai H. Chung*

In the early 1970s, pediatric surgeons first used peritoneoscopy and thoracoscopy. Subsequently, the recent development of improved monitors, telescopes, and miniaturization of instruments has created explosive growth in the use of laparoscopic procedures in infants and children. The reported advantages of the laparoscopic technique are better operative exposure, faster patient recovery, and shorter hospital stay; however, the disadvantages include lack of tactile sensation, inconclusive long-term results, and increased operative time.

## Indications

Commonly performed laparoscopic pediatric procedures include diagnostic laparoscopy for abdominal pain or trauma, appendectomy, cholecystectomy, pyloromyotomy, fundoplication, gastrostomy, splenectomy, evaluation for contralateral inguinal hernia, localization of nonpalpable testis, pull-through for Hirschsprung's disease, and thoracoscopic lung biopsy or decortication for empyema. Other procedures that are less frequently performed by laparoscopy include Ladd's procedure, Meckel's diverticulectomy, resection of foregut duplications, staging for cancer, and ligation of patent ductus arteriosus. In reality, the only absolute contraindications to laparoscopy are those that would mitigate against any surgical procedure, such as coagulopathy and hemodynamic instability.

## Equipment

The development of instruments designed specifically for pediatric patients has been the most significant progress in pediatric endoscopic surgery over the past several years. Reusable 3-mm trocars are economical and associated with decreased postoperative pain; however, frequent trafficking of instruments may lead to unintentional dislodgement. The trocars can be secured to the abdominal wall using a 1cm sleeve of an 18 Fr. rubber catheter over the shaft of the trocar, which is then sutured to the skin. Larger 5-mm expandable trocars (Innerdyne®) are very useful in maintaining a tight seal with the surrounding tissue and can accommodate larger instruments such as harmonic scalpel or retractors.

The Hopkins rod lens telescopes come in a variety of sizes, lengths, and lens angles. The 0° scopes provide the least amount of disorientation and are easy to use for simple procedures. The 30° scopes are more useful for advanced laparoscopic procedures and in some situations provide better exposure of the viscera. The most commonly used scope size is 5mm, but smaller diameter (1.2-4 mm) scopes with

excellent lighting and optics are available for smaller patients. Three-chip cameras produce superior images and advances in digital cameras will continue to improve the image quality of the operative fields.

Instruments with smaller diameters (1.7-3 mm), as well as shorter shafts, are available in various styles of tips and handles. Advances in product technology have created miniaturization of instruments without the sacrifice of feel and durability. Sutures also come in a variety of size and shape: ski-needles are easy to pass through the trocars and to manipulate by retaining some of the mechanical advantages of curved needles. Development of the harmonic scalpel and endoscopic ultrasound has also contributed significantly to recent progress in laparoscopy. The harmonic scalpel, which is now available in 5 mm size, can coagulate vessels up to a few millimeters in diameter and allows easier and safer dissection of vascular tissues. Diagnostic endoscopic ultrasound is useful in defining vascular anatomy and identifying lesions in the parenchyma of solid organs. It may occasionally be useful in laparoscopic staging cancer.

### General Considerations

General patient preparation for operations do not change because of the use of minimally invasive surgical techniques. Operating room personnel, as well as the patient's family, are prepared for potential conversion of any laparoscopic procedure to an open case. The primary surgeon stands facing the patient with the operative area in line with the video monitor. A Foley catheter is placed only for anticipated lengthy procedures, otherwise the bladder is emptied by the Crede' maneuver. The stomach is decompressed by orogastric suction. Prophylactic antibiotics are considered to prevent trocar site infection, and fascial defects resulting from 5-mm or larger trocars are closed with sutures to prevent incisional hernias.

Two important considerations in pediatric laparoscopy are:

1. abdominal cavities are smaller in size and
2. the abdominal wall is much more elastic and thinner.

It is easier to injure abdominal viscera during trocar placement in pediatric patients; therefore, some authors favor open technique for trocar placement. However, with diligence and a careful approach, trocars can be placed safely using closed technique, even in the smallest infants. The umbilicus is an ideal initial trocar site for telescopes. Especially in infants, the normal small fascial defects at the umbilicus can be easily enlarged to enter the peritoneal cavity for subsequent insufflation without the need for Veress needle placement. All trocars are placed under direct visualization. Large instruments are maneuvered under visual guidance as they can easily injure viscera.

General anesthetics are used in pediatric patients undergoing minimally invasive surgery. Caudal blocks and infiltration of long-acting local anesthetics at the trocar sites are helpful in providing postoperative analgesia. Absorption of CO<sub>2</sub> and an increase in abdominal pressure due to insufflation may present physiologic challenges. Visceral absorption of CO<sub>2</sub> may lead to hypercapnia requiring an increase in minute ventilation, particularly in infants with chronic lung disease such as bronchopulmonary dysplasia. Abdominal insufflation results in increased intra-abdominal pressure that may cause a decrease in lung compliance and tidal volume. Venous return to the heart is sometimes decreased compromising cardiovascular function.

Older children can tolerate 14 mmHg insufflation pressures, while smaller infants require pressure ranging from 8-12 mmHg.

### **Appendectomy**

Many centers now routinely use laparoscopic appendectomy. The benefits of less postoperative pain and faster return to full activity are reported but unproven. Laparoscopic appendectomy is particularly beneficial in cases of obese patients as well as teenage girls with abdominal pain in whom the diagnosis of appendicitis is questionable. Laparoscopy allows thorough examination of the entire peritoneal cavity to search for pathology when a normal appendix is encountered.

The operating surgeon stands on the patient's left and the umbilical trocar is initially placed for the telescope. Two additional trocars are placed, one in the left lower quadrant and the other in a midline suprapubic location. Trendelenburg position is used to gravity-retract the small bowel from the right lower quadrant for better exposure of the cecum and pelvis. The mesoappendix is divided using cautery or hemoclips depending on vessel size. The appendix is ligated using a pretied endoloop. Alternatively, an endostapler can divide the appendix and mesoappendix simultaneously. The specimen is most easily delivered through the umbilical 10-mm port. This route may reduce the incidence of wound infection. Occasionally, if the thickened inflamed appendix cannot be removed through the trocar, an endoscopic retrieval bag is used. In cases of ruptured appendicitis, the fecalith is sought and removed if possible and irrigation of the abdominal cavity considered. Although the subcutaneous wound infection rate is much lower with laparoscopic approach, the incidence of postoperative abscess is similar to open cases.

### **Fundoplication and Gastrostomy**

Laparoscopic fundoplication is now a common technique for antireflux procedures. The indications and diagnostic work-up for laparoscopic fundoplications are the same as those for open procedures. Occasionally, a preoperative enema is necessary to ensure the colon is decompressed. A distended transverse colon, especially in small infants, can limit the operative exposure making the procedure more difficult. The bladder is decompressed by the Credé maneuver and an esophageal dilator is placed. The patient is placed at the foot end of the table, with the lower extremities taped in a cross-legged position or, in the case of older children (weight > 20 kg), supported in stirrups. The patient is placed in reverse Trendelenburg with the left side raised slightly, providing gravity retraction of the viscera away from the upper abdomen.

Generally, five trocars are used, and in small infants, they should be placed lower in the abdomen to create a longer working space and thus allow better maneuverability. Use of a 30° or 45° angle scope is important to facilitate adequate operative exposure. First, dissection is completed to create proper intra-abdominal esophageal length. The short gastric vessels are divided with cautery, hemoclips, or harmonic scalpel depending on vessel size. A complete 360° wrap (Nissen) is the most common fundoplication performed by laparoscopy, but partial fundoplications (Toupet and Thal) can also be performed. The decision algorithm for which type of wrap to create should be the same as in open cases.

Gastrostomy is placed in indicated patients. A site on the anterior stomach is grasped and pulled up. Two U-stitches are placed through the abdominal wall to suspend the anterior wall of the stomach. Using the Seldinger technique, a needle is introduced through the abdominal and anterior stomach wall. After placing a guide wire, graduated dilators (8 to 20 Fr.) are used to enlarge the tract, and a MicKey® gastrostomy button is placed. Postoperatively, the gastrostomy tube is placed to gravity drainage overnight and then small amounts of enteral feeding are started the next day. The feeding volume is then gradually increased to target over 2-3 days. Patients are discharged from hospital by postoperative day 2.

## Splenectomy

The harmonic scalpel and endoscopic stapling devices have facilitated the development of laparoscopic splenectomy. The major indications for laparoscopic splenectomy are hematologic disorders such as hereditary spherocytosis and idiopathic thrombocytopenic purpura. Other conditions that occasionally require splenectomy include sickle cell disease,  $\beta$ -thalassemia and Hodgkin's disease. All patients receive preoperative vaccinations against Pneumococcus, *H. influenzae*, and Meningococcus.

Proper patient positioning is instrumental to this operation, and most surgeons prefer the lateral approach. The left side is elevated approximately 45° with a bean bag or gel roll. For trocar placement, the table is tilted to the patient's left side, and for splenectomy, the table is tilted to the right so that the patient is in near lateral decubitus position. The scope is placed through the umbilical trocar, and three additional ports are usually necessary. First, the splenocolic and gastrosplenic ligaments are divided with cautery, and then a careful search is made for accessory spleen. The reported incidence of missed accessory spleen is variable but similar to open cases, ranging up to 20%. The short gastric vessels are divided using cautery or a harmonic scalpel. Maintaining phrenic attachments at the superior pole allow easier maneuvering of the spleen during hilar dissection. Then, using the stapling device via a 12-mm port, the hilar vessels are carefully divided to avoid injury to the tail of the pancreas. An endobag is introduced directly through the largest trocar fascial defect, and the spleen is guided into the bag. Placing the spleen into the bag can at times be the most difficult part of the operation, especially in small patients. The neck of the sac is exteriorized and the spleen is fractured with morcellator, surgical clamps or surgeon's finger. Operating time has consistently been longer for laparoscopic approach, but it has been shown to be a safe alternative to open splenectomy.

## Pyloromyotomy

Despite some enthusiasm for less postoperative ileus and improved cosmesis, the benefits of laparoscopic pyloromyotomy remain unknown. A single trocar is placed at the umbilicus for insufflation and 3-mm telescope. Two stab wounds are created with 11-scalpel blade for 3-mm instruments without the need for trocars. Left-hand grasper exposes the pylorus, and then the pyloromyotomy incision is made with a retractile arthrotomy knife. A pyloric spreader is used to perform the myotomy until the two sides of the split pyloric tumor move independently. Careful inspection for absence of mucosal injury is confirmed, and then the umbilical fascia is closed. Postoperative feedings can be started within 2-4 hours. Reported series demonstrate

an average operating time of 25 minutes with 3% perforation and 0.8% inadequate myotomy rates.

### **Contralateral Inguinal Exploration**

Routine contralateral inguinal exploration at the time of symptomatic hernia repair for infants is the standard practice based on the high incidence of contralateral patent processus vaginalis (4-65%). However, the potential complications of injury to the vas deferens (1.6%) and testicular atrophy (2%) exist, even in the hands of experienced pediatric surgeons. Although there are numerous diagnostic methods (e.g., ultrasound evaluation of the inguinal canal or simple insufflation of the abdominal cavity) for determining the presence of contralateral inguinal hernia, laparoscopic inspection is the most simple and reliable method.

The symptomatic hernia sac is dissected to the level of the internal ring, and a 3-mm trocar is introduced into the peritoneal cavity. After insufflation, a 70° telescope is placed to inspect the patency of the contralateral processus vaginalis. Modification of this technique by insufflating the abdomen via the hernia sac on the symptomatic side and then placing 1.2-mm scope through a 14-gauge angiocatheter in line with the contralateral internal inguinal ring has resulted in more accurate assessment of patent processus vaginalis. Once the presence of a contralateral hernia is determined, it is repaired in standard fashion by high ligation of the sac. Recently, several authors have even performed transperitoneal laparoscopic hernia repairs.

Several reported series show no surgical complications related to laparoscopy with false negative rate of less than 1%. Authors consistently emphasize that the laparoscopic contralateral exploration is the most accurate means to determine the patency of processus vaginalis.

### **Nonpalpable Testis**

When a testis is not palpable on thorough inguinal exam after induction of general anesthesia, diagnostic laparoscopy is performed via a small umbilical trocar. If testicular vessels are atrophic and end blindly before the internal inguinal opening, the procedure is stopped due to absence or nonviable testis. However, if normal appearing vessels pass into the inguinal canal or a testis is seen at the orifice, inguinal exploration and orchidopexy is indicated. In cases where the testis is primarily located in the abdominal area, the testicular vessels are not of sufficient length to allow primary orchidopexy. The two-stage Fowler-Stephens approach is the most popular technique used for intra-abdominal testis. Ligation of the testicular vessels is performed laparoscopically, and then followed by inguinal exploration and orchidopexy months later when collateral vascularity of the testis is achieved. Many authors report an excellent outcome without significant complications using this technique. The average operating time is less than 10 minutes. Recently, some authors have advocated single-stage laparoscopic orchidopexy with promising initial results.

### **Pull-Through for Hirschsprung's Disease**

Traditionally, Hirschsprung's disease has been surgically treated in two or three stages; leveling colostomy followed by a colonic pull-through with either simultaneous or subsequent colostomy closure. One-stage pull-through has also been advocated for infants with satisfactory results. In addition, laparoscopy-assisted single-stage

colonic endorectal pull-through for Hirschsprung's disease has recently been performed at many centers with an excellent outcome. The enthusiasm for the laparoscopic approach stems from a hope for decreased morbidity along with equivalent functional results compared to open cases. Infants do not require diverting colostomy, and they may have an opportunity to achieve normal fecal control at an earlier age.

All patients undergo the same diagnostic work-up for Hirschsprung's disease as in open operation. Patients with severe enterocolitis are generally excluded for the laparoscopic approach since these children seem to benefit from a period of diversion and colon rest prior to reconstruction. Frequent preoperative rectal irrigation with saline is helpful to decompress the colon. Infants are positioned transversely on the operating table and are prepped entirely below the nipple line. The initial trocar is placed just below the liver margin for a small angled scope (3-5 mm). Two working ports of 3 or 5 mm are placed in the left upper and right lower quadrants. An additional suprapubic trocar is used in some patients for retraction. The transition zone is identified grossly and seromuscular biopsy is obtained with scissors to confirm the presence of ganglionic cells. Mesenteric dissection is accomplished with cautery in small infants, but requires hemoclips or harmonic scalpel in older children with larger vessels. Preservation of the marginal artery is vital to this portion of the operation. The aganglionic segment of distal colon is dissected circumferentially. Perineal endorectal dissection is started at 1-2 cm above the dentate line after placing several traction sutures to evert the anus and rectum. The submucosal plane is developed with cautery and dissection is continued proximally using blunt and sharp dissection until the colorectum turns inside out. The rectal sleeve is then opened and a full-thickness specimen is sent for frozen section for additional confirmation of ganglion cells at the proximal margin. After posterior myotomy, coloanal anastomosis is completed with interrupted absorbable sutures. Oral feeding is started on postoperative day 1, and the average length of hospital stay is 2-3 days. Reported experiences of 80 patients from several centers demonstrate an average operating time of 147 minutes with minimal blood loss. Only two patients required conversion to open procedures, and enterocolitis and chronic diarrhea were each noted in 8% of the patient group. Despite the lack of long-term results, laparoscopy-assisted colonic endorectal pull-through for Hirschsprung's disease appears to be a satisfactory technique.

### **Thoracoscopy**

A wide variety of conditions are amenable to thoracoscopic approach. Biopsy of lung nodules and early drainage of empyema are commonly performed thoracoscopic procedures. Access to mediastinal masses is also easily achieved thoracoscopically, and resection without a large painful thoracotomy incision can be accomplished. Other recent innovative applications of minimally invasive techniques in thoracic surgery include ligation of patent ductus arteriosus (PDA) and anterior spinal fusion for severe scoliosis. Single lung ventilation is generally difficult to achieve in small patients weighing less than 30 kg due to the lack of a small sized double-lumen endotracheal tube. However, selective mainstem intubation of the contralateral bronchus or use of a bronchial blocker can be of great help in

maintaining operative exposure. A low-pressure (3-5 mm Hg) CO<sub>2</sub> infusion can also assist in keeping the lung decompressed.

### Summary

There now exist extensive applications of the laparoscopic technique in infants and children. The list of operations appears to be getting longer as we witness the development of improved technology. However, one must exercise caution in utilizing these innovative techniques and be aware of potential complications associated with each procedure. The benefits of minimally invasive techniques must be carefully compared to the potential increased cost, operating time, and lack of long-term results. Most importantly, laparoscopic surgery should be regarded in terms of applying minimally invasive techniques to perform the same operations as in open approach.

### Selected Readings

1. Georgeson KE. Minimally invasive pediatric surgery: Current Status. *Semin Pediatr Surg* 1998 (series); 7(4):193-238.
2. Lobe TE. Laparoscopic surgery in children. *Curr Prob Surg* 1998; 35(10):859-950.
3. Holcomb GW III: Laparoscopic Pediatric and Fetal Surgery. *Semin Lap Surg* 1998 (series); 5(1):1-66.

**A**

Aberrant pulmonary artery 312, 314  
 Abscess 45, 46  
 Abuse 120, 123, 129, 135, 144, 148, 150, 159-162  
 Acalculous cholecystitis 396, 398  
 Achalasia 380-382  
 Adenoma 420-422, 424, 425, 427  
 Adenomatous polyps 234  
 Adhesions 393, 394  
 Airway 310-313, 315, 320, 330, 337, 341, 343, 349, 377, 384  
 Alpha interferon 68  
 Amniocentesis 10-12  
 Anal fissure 100, 101, 104  
 Anemia 3, 9, 10  
 Ann Arbor staging 212, 213  
 Annular pancreas 395, 411  
 Anorectal malformation 366, 367  
 Antibiotic therapy 40, 46-48  
 Anus 91, 100, 101, 103-105, 107  
 Aortomesenteric 400  
 Apnea 310, 377  
 Appendicitis 246, 388-392  
 Apple peel lesion 265  
 ARDS 31  
 Arteriography 142  
 Ascites 286, 287, 290, 295-298  
 Aspiration 312, 320, 322, 339, 341, 349, 377, 381  
 Asplenia 266  
 Atresia 250-252, 254, 255, 257-259, 261, 264-267, 269-271, 276, 277, 396, 411

**B**

Barium esophagram 315, 385  
 Battery ingestion 82  
 Beckwith-Wiedemann syndrome 164, 363, 426  
 Bell-Clapper deformity 57  
 Biliary atresia 241-244, 300-302, 396, 411

Bilious emesis 251, 269  
 Bites 115, 150-152, 161  
 Bladder rupture 130, 133  
 Blood donation 4  
 Blunt abdominal trauma 128, 130, 132  
 Bochdalek (Foramen of) 325, 327  
 Brain injury 110, 123, 125, 136  
 Branchial arches 69  
 Branchial remnant 69-72  
 Breast 206-209, 212, 220  
 Bronchogenic cyst 185, 201, 202, 204, 205, 311, 326, 333, 335, 337, 338  
 Bronchoscopy 312, 377  
 Burkitt's lymphoma 215  
 Burns 144-149, 161, 162

**C**

Calories 24, 25, 27, 30  
 Cantrell (pentalogy of) 362  
 Carcinoid 198  
 Caroli's disease 307  
 Cat bite 150, 151  
 Catecholamine 171, 172, 415-419  
 Caustic esophageal injury 383  
 Cephalohematoma 153, 154  
 Cerebral perfusion 35  
 Chagas' disease 380  
 CHARGE association 321  
 Chloride channel 268  
 Cholangiocarcinoma 305  
 Cholecystitis 238, 389, 396-398  
 Choledochal cyst 301, 304, 305, 307, 308  
 Cholelithiasis 389, 395, 397, 398, 405  
 Chorionic villus sampling 11  
 Chylothorax 344-346, 348, 351, 354  
 Chylous ascite 295, 297, 298  
 Circumcision 63, 64  
 Clear cell 164, 165, 167  
 Cloaca 366, 367, 370, 372  
 Cloacal exstrophy 362, 372



Coins 79, 80, 84  
 Colon atresia 269  
 Colon carcinoma 403  
 Compartment syndrome 142, 143, 145  
 Congenital adrenal hyperplasia 428, 429, 431, 433  
 Congenital cystic adenomatoid malformation (CCAM) 335, 337  
 Congenital diaphragmatic hernia 325, 327, 331, 332, 335, 344, 349  
 Congenital hemangioma 65  
 Congenital lobar emphysema 315, 333, 335  
 Conjoined twin 439, 440  
 Constipation 99-102, 104, 107, 371  
 Corticosteroids 68, 96  
 Craniofacial ratio 121  
 Crohn's disease 389, 391, 402-405, 407, 410  
 Croup 315  
 Cryoprecipitate 39, 40  
 Cryotherapy 68  
 Cryptorchidism 56, 57, 60-62  
 Cushing ulcer 237  
 Cystic fibrosis 241, 266-271, 390, 396-398, 409  
 Cystography 130, 133

## D

Dehydration 19, 22, 29, 85, 86, 100  
 Diagnostic studies 3, 11  
 Dislocation 116, 126, 141, 142, 155  
 Dog bite 150  
 Double aortic arch 314  
 Ductus arteriosus 314, 330, 352-354  
 Duodenal hematoma 162  
 Duodenal web 259  
 Duodenoduodenostomy 259, 411  
 Duplications 278, 279, 280, 281, 283, 395

## E

Electrolytes 19-21, 24  
 Embryonal sarcoma 177, 178, 180, 181, 221

Emesis 85, 86, 88  
 Empyema 348-351  
 Endodermal sinus 189, 190, 194  
 Enteral nutrition 23, 30  
 Epidural hematoma 124, 125, 154  
 Esophageal atresia 311, 318-323, 377  
 Esophageal perforation 339, 341, 348, 381, 384-386  
 Esophagitis 376-378, 381  
 Esophagoscopy 312, 378, 381, 384  
 Eversion 325-327, 330, 331  
 Exchange transfusion 10  
 Extracorporeal membrane oxygenation (ECMO) 27, 34, 330, 331  
 Extremity trauma 115  
 Extubation 5

## F

Facial nerve 69-71  
 Facial trauma 110, 120, 121  
 Fecalith 246, 388, 390, 392  
 Female pseudohermaphroditism 428-430  
 Femoral hernia 50, 54  
 Fertility 56, 61, 62  
 Fetal surgery 11, 13, 14  
 Fibroadenoma 208, 209  
 Fissure 229, 230  
 Fistula-in-ano 105, 106  
 Fistulas 69-71, 77  
 Fluid imbalance 20  
 Fluid requirements 20, 23  
 Fluid resuscitation 112, 130, 145  
 Fluids 21, 22, 37  
 Follicular carcinoma 226  
 Follicular cyst 188, 189  
 Foramen cecum 72  
 Foreign bodies 79-82, 84  
 Fundoplication 379

## G

Ganglioneuroblastoma 169, 170  
 Gastric teratoma 197, 198  
 Gastritis 230, 237-239  
 Gastroesophageal reflux 315, 320, 322, 323, 331, 376-379, 381  
 Gastroschisis 361-363, 365

Germ cell tumor 189, 190, 192, 194,  
201-203, 205  
Glasgow coma scale 110, 112, 123,  
124  
Greenstick fracture 117, 121  
Gross-Vogt classification 318, 322  
Growth retardation 403-405  
Gynecomastia 193, 207, 208

## H

Head injury 112, 113, 123, 124, 136,  
139, 160  
*Helicobacter pylori* 237, 238, 248  
Hemangioendothelioma 177, 178,  
180, 181  
Hemangioma 65-68, 70, 97  
Hematuria 132, 133  
Hemorrhage 111, 112, 115, 132,  
137-139, 142, 150, 153-156,  
160-162, 229, 231, 238, 239,  
242, 243, 246, 397, 404  
Hemorrhoids 106, 107  
Hemothorax 110, 111, 137, 139  
Hepatoblastoma 177-181  
Hepatocellular carcinoma 177, 178,  
180, 181  
Hereditary spherocytosis 9  
Hirschsprung's disease 251, 252, 261,  
265-267, 269, 270, 272-274,  
276, 277, 390  
Hodgkin's disease 202, 205, 209,  
211-214  
Hydrocele 50-52, 55, 56  
Hydrops fetalis 13  
Hydrostatic reduction 92  
Hyperinsulinism 424-426  
Hypersplenism 94, 97  
Hypertrophic pyloric stenosis 251,  
254, 255  
Hyperventilation 125  
Hypoparathyroidism 422  
Hypovolemia 35-37

## I

Idiopathic thrombocytopenic purpura  
(ITP) 94, 96, 97  
Imperforate anus 362, 366, 367,  
369-372

Incarceration 51, 52  
Inguinal hernia 50-52  
Insulinoma 412  
Intersex 428-432  
Intestinal injury 131  
Intestinal obstruction 232, 246, 248,  
250-253, 268, 269, 271, 279,  
280, 393, 411  
Intra-abdominal testicle 61, 62  
Intraosseous 17, 37  
Intravenous access 17, 37  
Intussusception 89-93, 102, 103, 230,  
232, 235, 246-248, 389, 390,  
393, 394  
Ischiopagus 439, 440  
Islet cell adenoma 425

## J

Jaundice 300-302, 304  
Jejunal atresia 250, 251, 265-267, 269  
Joint injuries 116  
Juvenile polyps 232, 233, 235, 246

## K

Kasabach-Merritt syndrome 68, 180  
Kasai procedure 302  
Kyphosis 357

## L

Ladd's procedure 261, 262, 264, 393  
Laparoscopic cholecystectomy 443  
Laparoscopic pull-through procedure  
443, 447, 448  
Laparoscopic splenectomy 446  
Laparoscopy 431, 443-445, 447, 448  
Large cell lymphoma 215, 216  
Lead point 89, 93  
Leiomyoma 197  
Ligation 330, 335, 344, 348, 354, 355  
Lipids 24  
Liquid ventilation 34  
Liver biopsy 301  
Lymphoma 184, 185, 194, 197, 198,  
201, 209, 211-219, 221

**M**

- Maintenance 20-22, 25, 37
- Malrotation 251, 254, 255, 257, 260-262, 264, 265, 276, 389, 400
- Manometry 381, 382
- McBurney's point 389, 393, 394
- Meckel's diverticulum 230, 245-248, 391, 393, 412
- Meconium 250-252, 255, 265, 268, 269-272, 276
- Meconium ileus 250-252, 268-271
- Mediastinum 185, 201-204, 217, 218
- Medullary carcinoma 224, 226
- Melena 229-232, 246
- MEN syndrome 415, 416, 419, 421, 422
- Mesenteric cyst 281-283, 297
- Mesoblastic nephroma 164, 165, 167, 168
- Metabolic alkalosis 86
- Metabolism 23, 35
- MIBG scanning 416, 419
- Mixed gonadal dysgenesis 429, 430, 433
- Morgagni 325-327, 329-331
- MRSA 44
- Myotomy 381, 382

**N**

- Necrotizing enterocolitis (NEC) 229, 230, 285-293, 398, 435
- Neglect 148, 159, 160, 162
- Neonatal hepatitis 295, 301
- Nephroblastoma 164, 167
- Nesidioblastosis 424-426
- Neuroblastoma 165, 169-176, 182, 185, 186
- Nevus 66
- Non-Hodgkin's lymphoma 170, 197, 198, 203, 205, 209, 212, 214, 215, 218
- Nonoperative management 129, 140
- Nonrotation 261
- Nutrition 22, 23

**O**

- Omphalocele 361-365, 372
  - Omphalomesenteric duct 75-77
  - Omphalopagus 440
  - Open fracture 116, 117
  - Opsoclonus-myoclonus 171
  - Orchidopexy 52, 61, 62, 193
  - Ovarian teratoma 184, 185, 190
  - Ovary 184, 189-191
  - Oxygen 32, 34, 35, 42
- P**
- Packed red blood cells 37, 39
  - Pain management 3, 7
  - Pancreatic cyst 410
  - Pancreatitis 238, 389, 393, 395, 408-411
  - Papillary carcinoma 208, 226
  - Paralysis 110, 115, 126, 141, 155, 156
  - Parathyroid 420, 422
  - Parenteral nutrition 17, 22-24, 27-30
  - Parkland formula 145
  - PCVC 17
  - Pectus carinatum 359
  - Pectus excavatum 357, 359
  - Perforation 287-291, 293-296, 298
  - Perianal abscess 105, 106
  - Pericardial cyst 201, 202, 204
  - Peritoneal drainage 290, 291
  - Peutz-Jeghers syndrome 199, 235
  - Pheochromocytoma 415-417, 419, 421
  - Phimosis 63, 64
  - PIC 17
  - Plasma 29, 39, 40, 42
  - Pneumoperitoneum 287, 290, 293, 294
  - Pneumothorax 110, 111, 136, 137, 139, 140, 156, 157
  - Poland's syndrome 359
  - Polyhydramnios 250, 251, 255, 269
  - Polyposis 233-235, 396
  - Polyps 199, 230, 232-235, 246, 397
  - Polysplenia 266
  - Port wine stain 66, 68
  - Portal hypertension 241-243

Portoenterostomy 302, 303  
 Portosystemic anastomoses 241  
 Posterior sagittal anorectoplasty 367  
 Postsplenectomy sepsis 97  
 Potassium 21, 22  
 Premature thelarche 206, 207, 212  
 Prematurity 285, 294  
 Prenatal diagnosis 10, 11  
 Prenatal ultrasound 13  
 Preoperative management 3, 6, 10  
 Presurgical visitation 4  
 Primary survey 109, 110, 113  
 Proctocolectomy 404, 405  
 Prostaglandin 353  
 Protein preparations 25, 27, 29, 30, 39, 40  
 Pull-through procedure 405  
 Pulmonary artery sling 314, 315  
 Pulmonary contusion 111, 136, 138-140  
 Pulmonary hypertension 329-331  
 Pyloric stenosis 85-87

## R

Rectal biopsy 273, 274  
 Rectal bleeding 229-232, 402  
 Rectal prolapse 101-104, 106  
 Rectopexy 104  
 Rectum 79, 82, 83, 91, 100, 101, 104  
 Recurrent hernia 52  
 Renal injury 132  
 Respiratory distress 310, 311, 320, 322, 325, 326, 330, 333, 335, 346, 348  
 Resuscitation 36, 37, 41  
 Retinopathy of prematurity 32  
 Rex shunt 243  
 Rhabdoid 164, 165, 167  
 Rhabdomyosarcoma 170, 194-196, 209, 220-223  
 Riley-Day syndrome 416  
 Rings 311, 312, 314, 315  
 Rye classification 212

## S

Saccrococcygeal teratoma 183  
 Salter-Harris 118, 119, 157

Sarcoma 164, 170, 177, 182, 185, 194, 209, 214, 221  
 Scoliosis 357  
 Scrotum 134, 135  
 Seminoma 194, 202, 203, 205  
 Sequestration 311, 326, 333, 335, 337, 338  
 Shaken impact syndrome (SIS) 160, 161  
 Shock 35-37, 42  
 Short bowel syndrome (SBS) 435, 436, 438  
 Sickle cell 11  
 Sinus 69-72, 74, 76, 77  
 Sistrunk procedure 73, 74  
 Skin grafting 135  
 Skull fracture 123, 125, 153, 154, 160, 161  
 Slings 314, 315  
 Sodium 20, 22  
 Spherocytosis 94, 95, 97  
 Spider bite 152  
 Spleen 94-97  
 Splenectomy 94-98  
 Splenic cysts 97  
 Splenic laceration 139  
 Splenomegaly 301  
 Stings 152  
 Stridor 310-312, 314, 315, 384  
 Stromal tumor 190, 193, 194  
 Subdural hematoma 124, 125, 154, 160  
 Superior mesenteric artery syndrome (SMA) 400, 401

## T

Teratoma 165, 182-187, 189, 194, 202  
 Testicle 50-52, 55, 57-59, 61, 62  
 Testicular feminization 428, 429, 432  
 Thermal injury 145  
 Thermoregulation 37  
 Thoracic duct 344, 346, 348  
 Thoracoscopy 443, 448  
 Thoracotomy 315, 323, 335, 349, 351, 354, 381, 385  
 Thyroglossal duct 69, 72-74  
 Thyroid carcinoma 214

Thyroid scan 74  
 Torsion 57-59, 61  
 Trace elements 27  
 Tracheoesophageal fistula 311,  
 318-323, 339, 344, 385  
 Tracheomalacia 311, 315, 320, 323  
 Transfusion 39-42

## U

Ulcerative colitis 402-405, 410  
 Ulcers 237-239, 248, 403, 405, 411  
 Ultrasonography 70, 86, 91  
 Umbilical fistula 246  
 Umbilical hernia 75, 77  
 Umbilical vessel 17  
 Umbilicus 75, 76, 77  
 Undescended testes 51  
 Urachal remnant 75-78  
 Urachus 75-77  
 Urine output 24, 25, 36  
 Urogenital ridge 60  
 Urogenital sinus 372  
 Uropathy 295

## V

VACTERL association 319, 321-323  
 Varices 230, 239, 242-244  
 Varicocele 55, 56  
 Vascular injury 141-143  
 Vascular malformation 65-69  
 Vasoactive intestinal peptide 171  
 Venomous snake bite 151  
 Ventilator support 32  
 Vitamins 23, 26  
 Vitelline duct 245-248  
 Volvulus 251, 260-262, 264, 268,  
 269, 271, 276, 279, 282, 283

## W


WAGR syndrome 165  
 Wilms tumor 167  
 Wind-sock 257  
 Wound care 5, 7  
 Wound closure 46, 52  
 Wound infection 43-46, 48

## Z

Zollinger-Ellison syndrome 237

## Table of contents (excerpt)

- |  |   |
|--|---|
| 1. Preoperative Care                                       | 12. Inguinal Hernia and Hydrocele                   |
| 2. Immediate Postoperative Care                            | 13. Variocele                                       |
| 3. Anemia  | 14. Testicular Torsion                              |
| 4. Genetics and Prenatal<br>Diagnosis in Pediatric Surgery | 15. Cryptorchidism:<br>The Undescended Testes (UDT) |
| 5. Vascular Access   | 16. Circumcision                                    |
| 6. Fluids and Electrolytes                                 | 17. Hemangiomas and Vascular<br>Malformations       |
| 7. Nutrition and Metabolism                                | 18. Branchial Cysts, Sinuses<br>and Fistulas        |
| 8. Respiratory Failure<br>and Support in Children          | 19. Thyroglossal Duct Cyst<br>and Sinus             |
| 9. Hypovolemic Shock<br>and Resuscitation                  | 20. Umbilical Anomalies                             |
| 10. Blood Component Therapy                                | 21. Foreign Bodies<br>of the Gastrointestinal Tract |
| 11. Perioperative Infections<br>and Antibiotics            |   |



This is one of a new series of medical handbooks.

It includes subjects generally not covered in other handbook series, especially many technology-driven topics that reflect the increasing influence of technology in clinical medicine.

The name chosen for this comprehensive medical handbook series is *Vademecum*, a Latin word that roughly means "to carry along". In the Middle Ages, traveling clerics carried pocket-sized books, excerpts of the carefully transcribed canons, known as *Vademecum*. In the 19th century a medical publisher in Germany, Samuel Karger, called a series of portable medical books *Vademecum*.

The *Vademecum* books are intended to be used both in the training of physicians and the care of patients, by medical students, medical house staff and practicing physicians. We hope you will find them a valuable resource.

All titles available at  
[www.landesbioscience.com](http://www.landesbioscience.com)

ISBN 1-57059-499-6



9 791570 594990